EQUILIBRE du RACHIS et MALADIE de PARKINSON

J M VITAL , N AUROUER ,
I OBEID , O GILLE ,
M de SEZE , K BIM .

Unité de Pathologie Rachidienne , Tripode , Bordeaux

RACHIS NORMAL de FACE

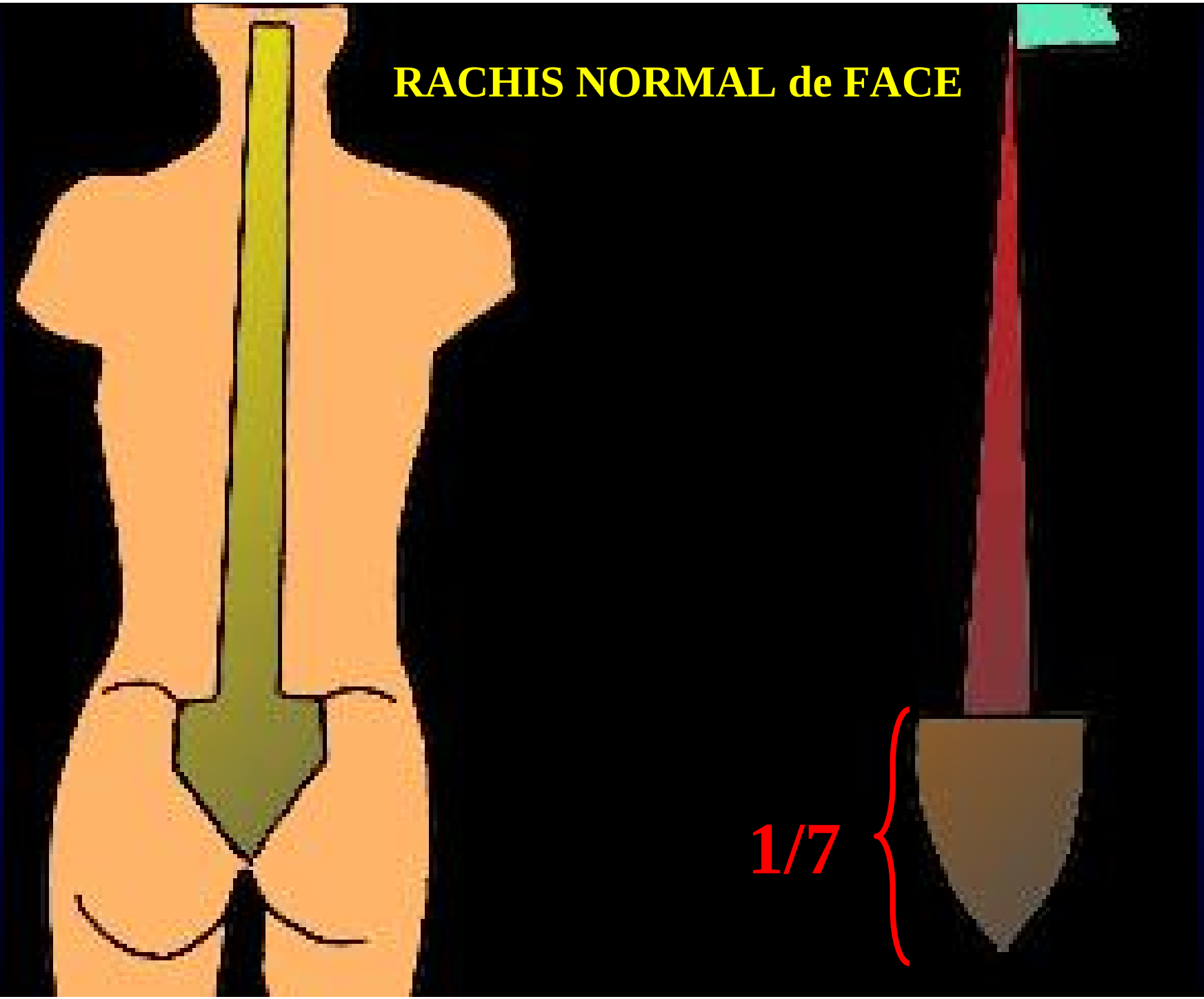

RACHIS NORMAL de PROFIL

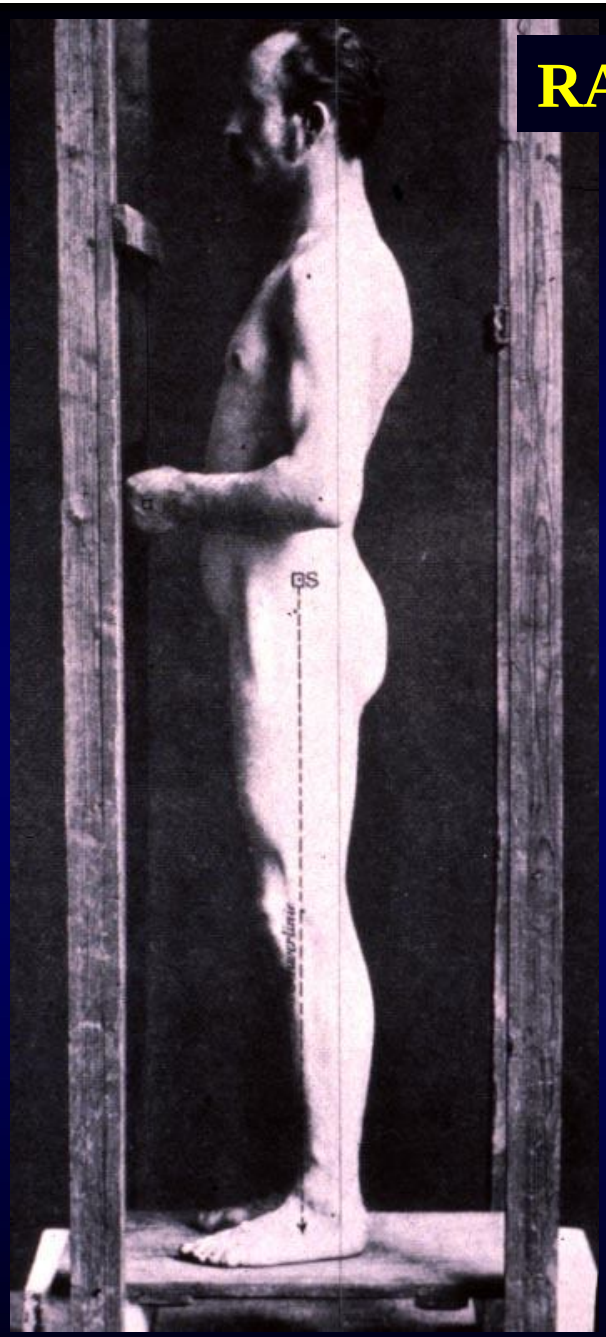

BRAUNE et FISHER

RACHIS LOMBAIRE

QuickTime™ et un
décompresseur Vidéo
sont requis pour visionner cette image.

« VERTEBRE PELVIENNE »

DURING

INCIDENCE PELVIENNE

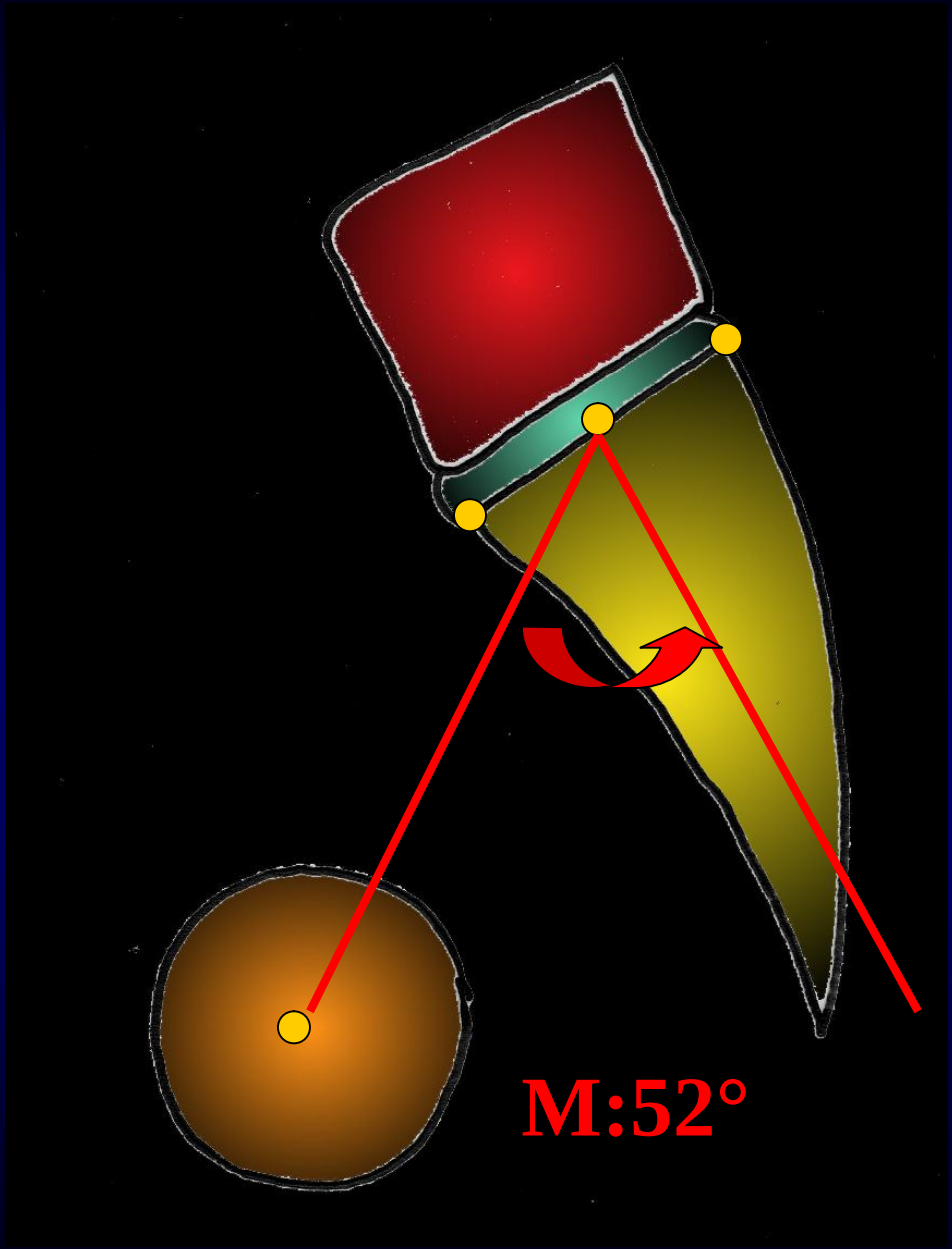

DUVAL-BEAUPERE

DYNAMIQUE

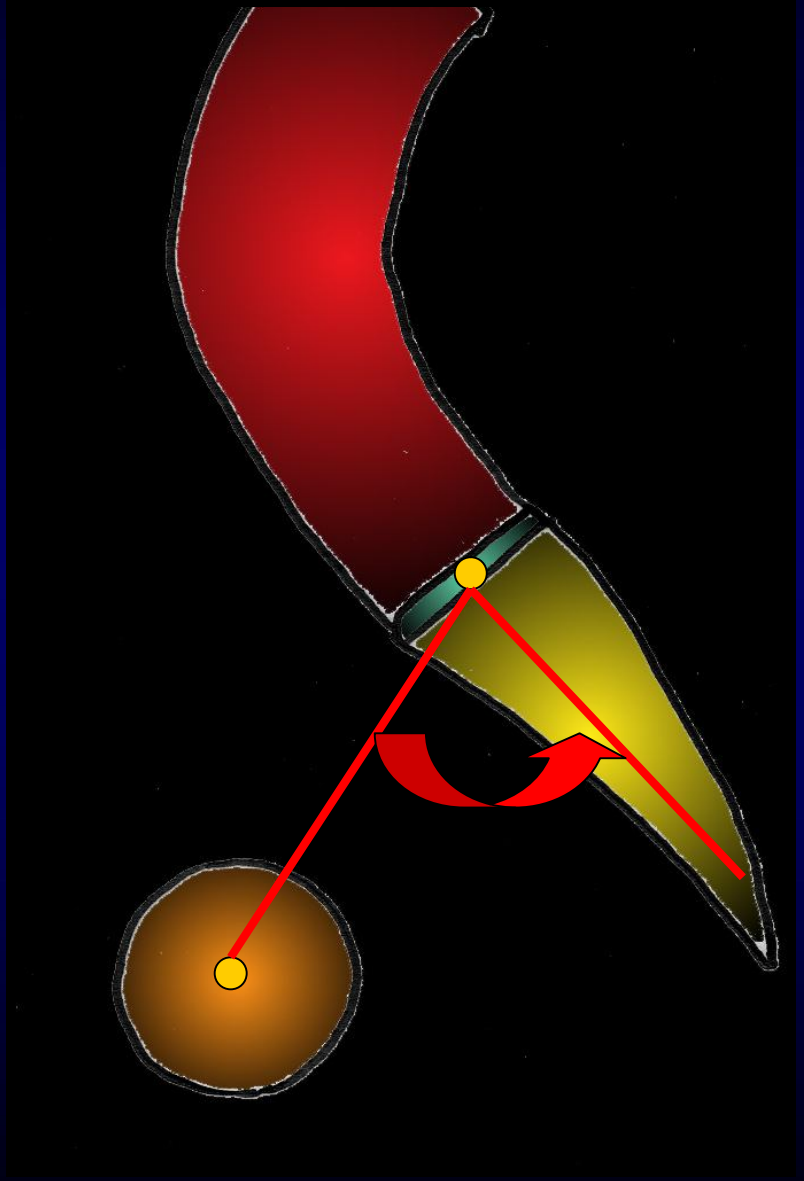

STATIQUE

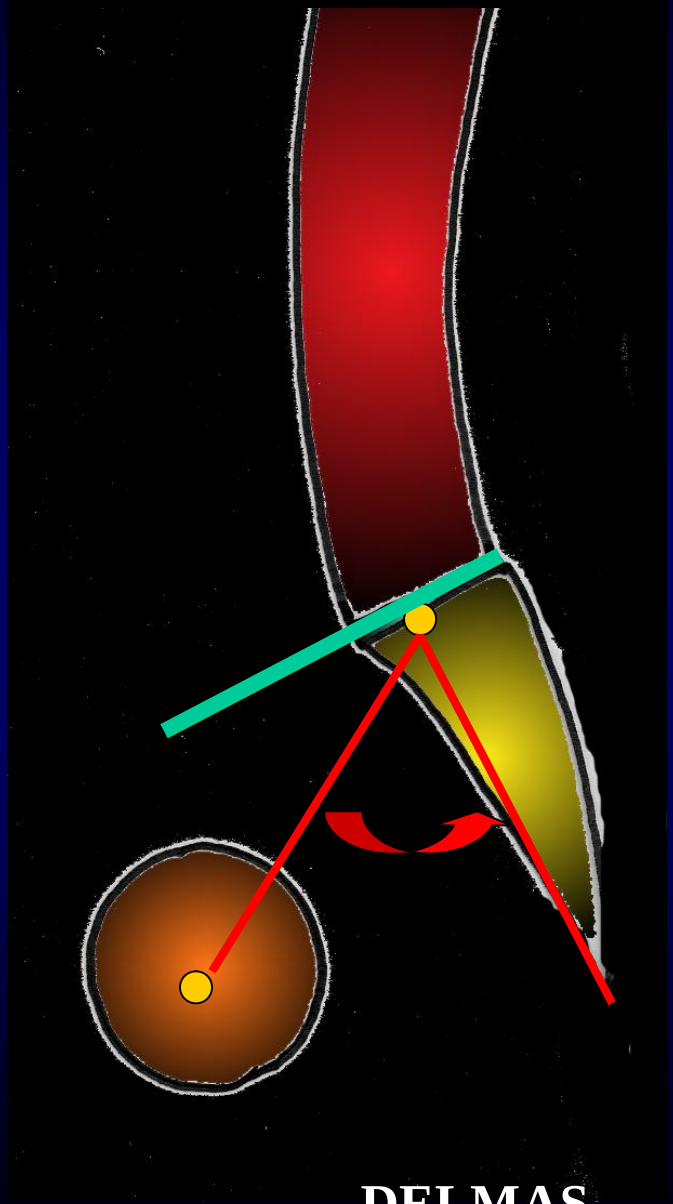

DELMAS

ROUSSOULY (RCO , 2005)

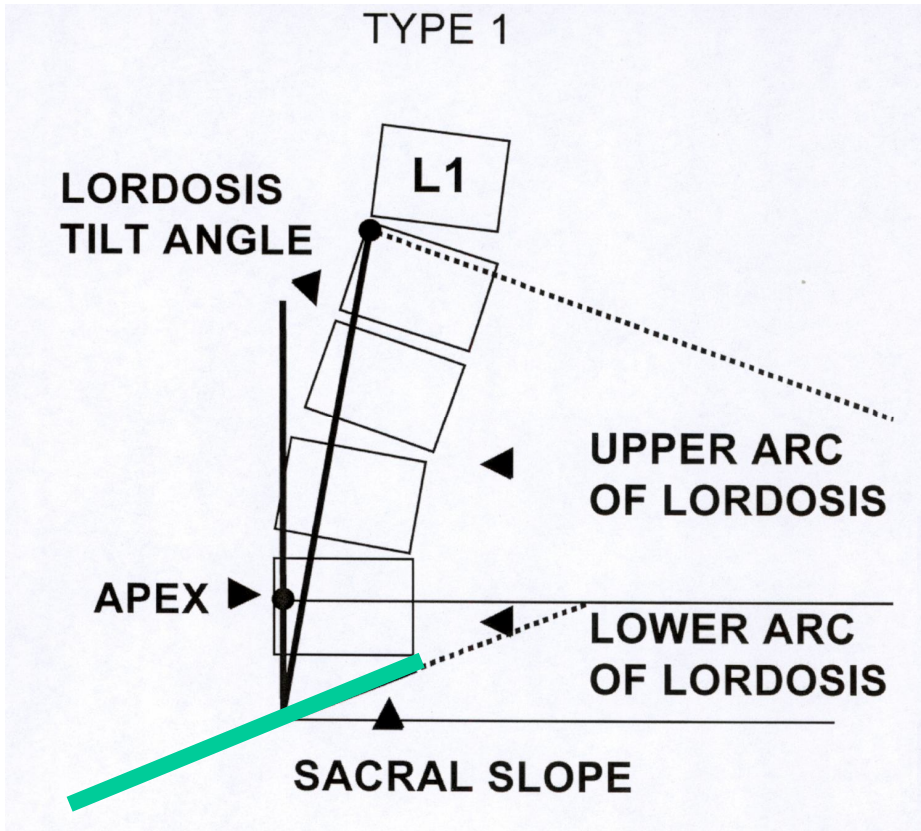

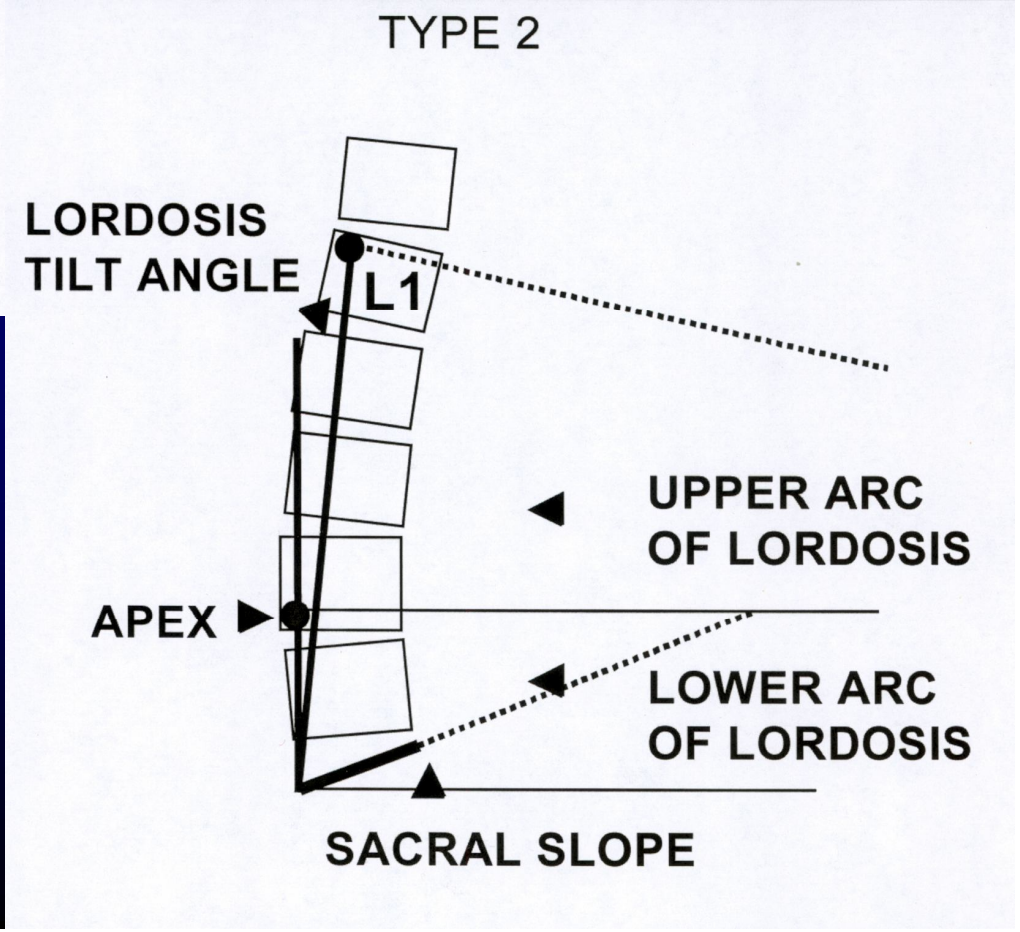

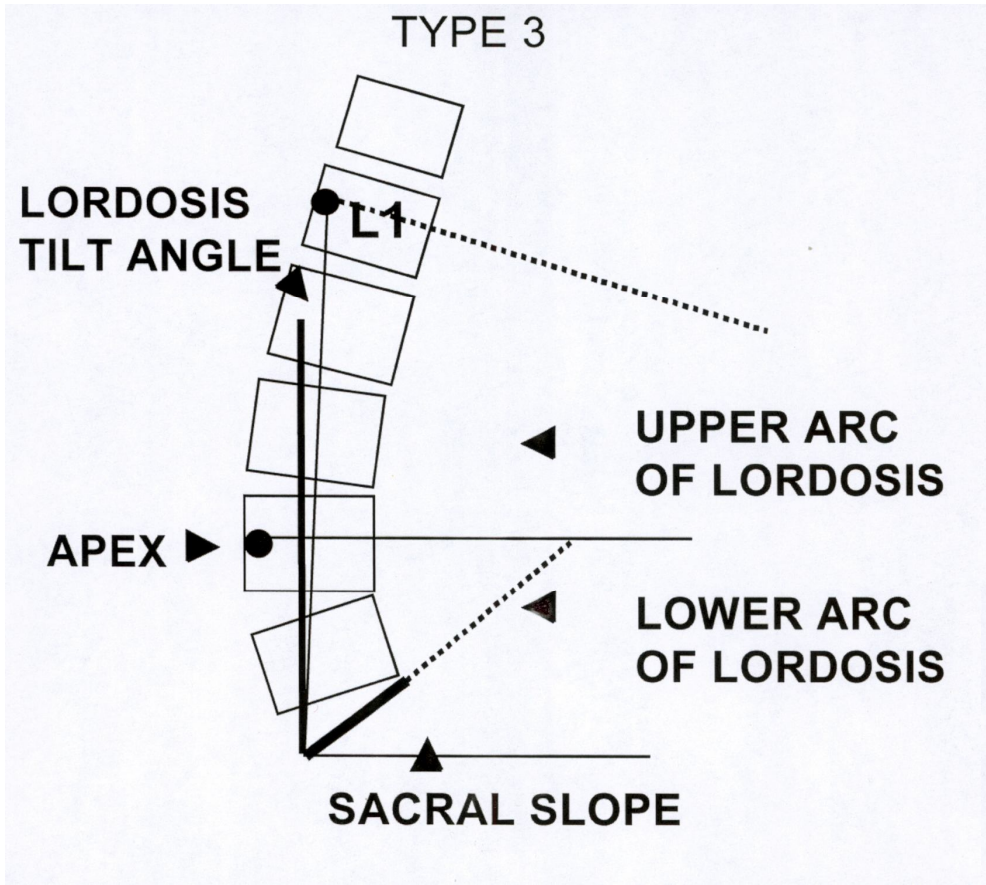
TYPE 3
LORDOSIS
TILT ANGLE
L1
UPPER ARC
OF LORDOSIS
APEX
LOWER ARC
OF LORDOSIS
SACRAL SLOPE

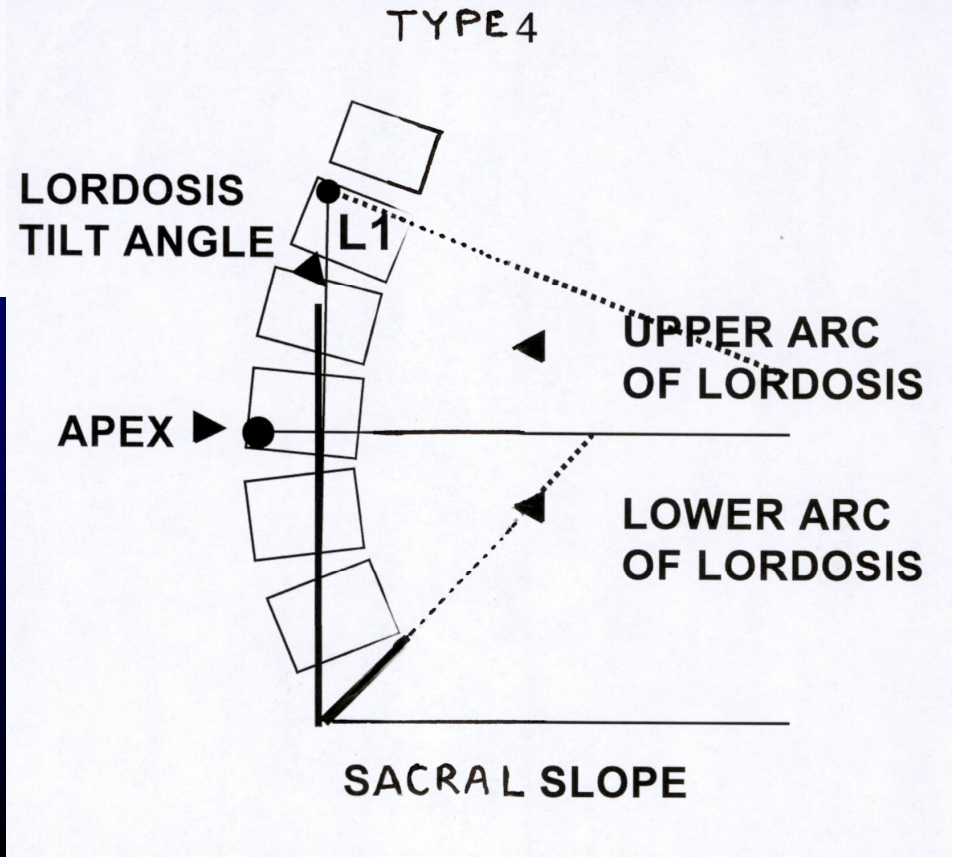
TYPE 4
LORDOSIS
TILT ANGLE
L1
UPPER ARC
OF LORDOSIS
APEX
LOWER ARC
OF LORDOSIS
SACRAL SLOPE

VERSION PELVIENNE

QuickTime™ et un
décompresseur Vidéo
sont requis pour visionner cette image.

Moyenne : 12°

GITE SAGITTALE

en T9

QuickTime™ et un
décompresseur Vidéo
sont requis pour visionner cette image.

Moyenne : 11°

ANGLE FEMORO TIBIAL

Normal: 0°

ITOI

« VERTEBRE CRANIALE »

DISTANCE CAE-TF



STEREORADIOGRAPHIE

Plateforme de gravité

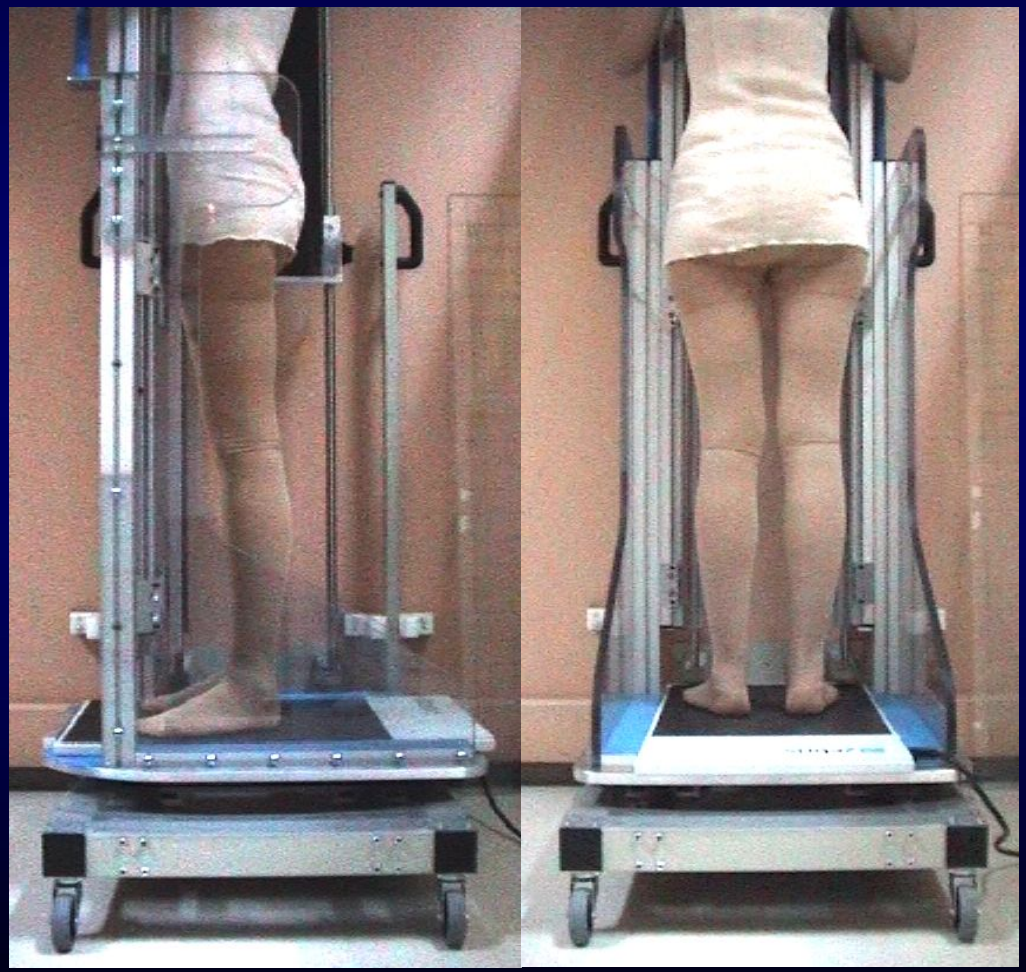

GANGNET

projection C A E
/
centre des T F

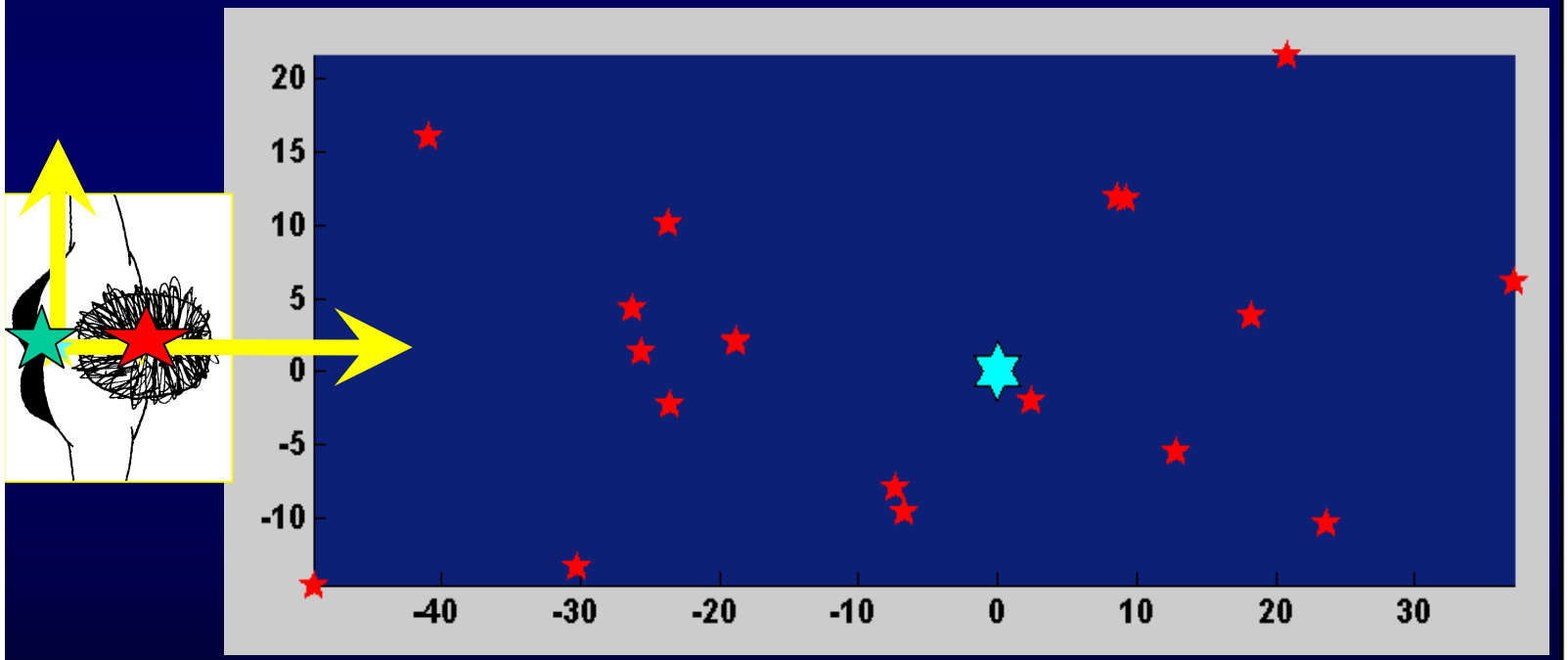



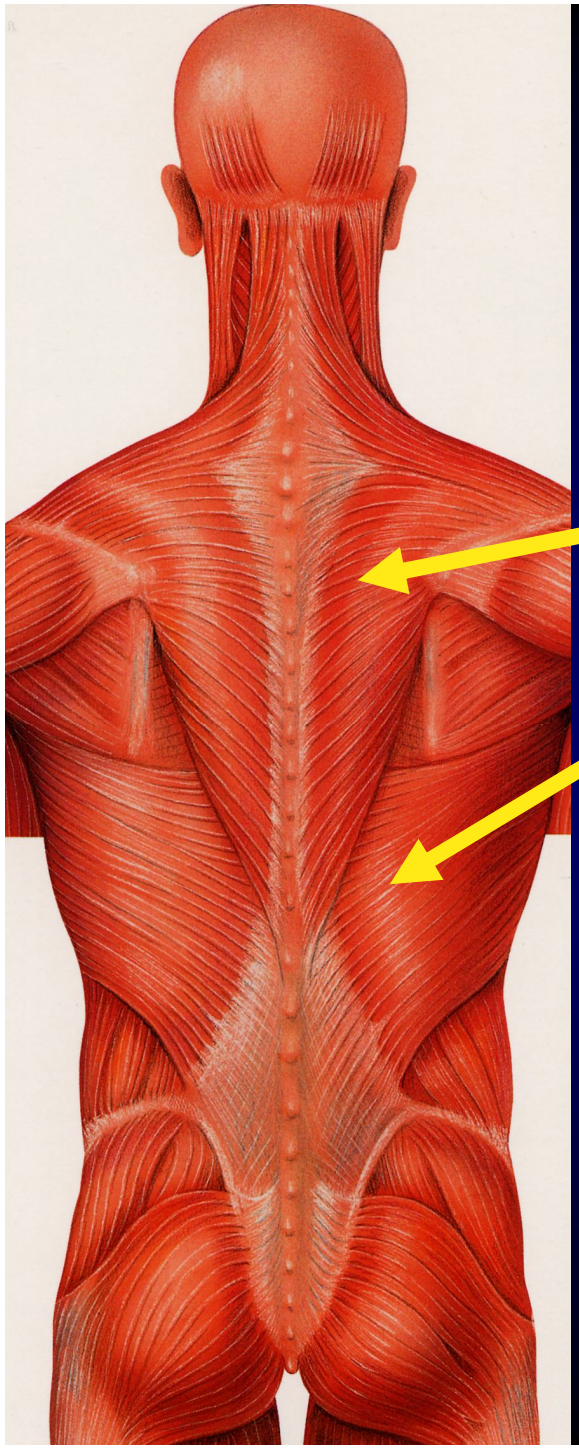

MUSCLES EXTRINSEQUES

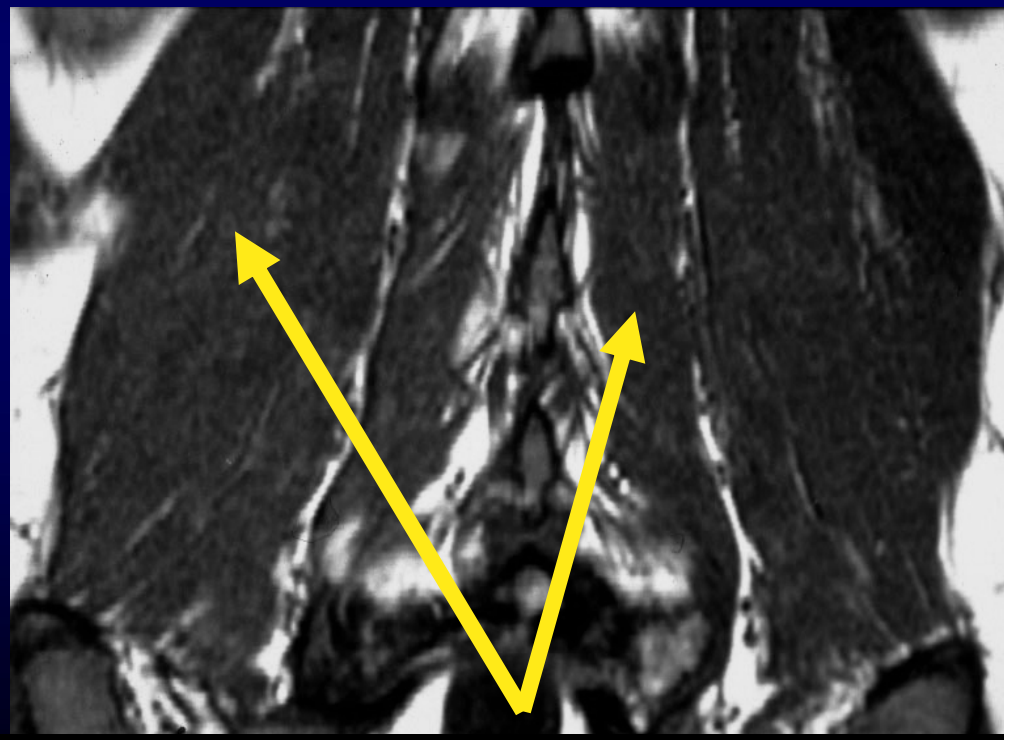

MUSCLES INTRINSEQUES

- DAGGFELDT Spine 2000 (Visible Human Project)

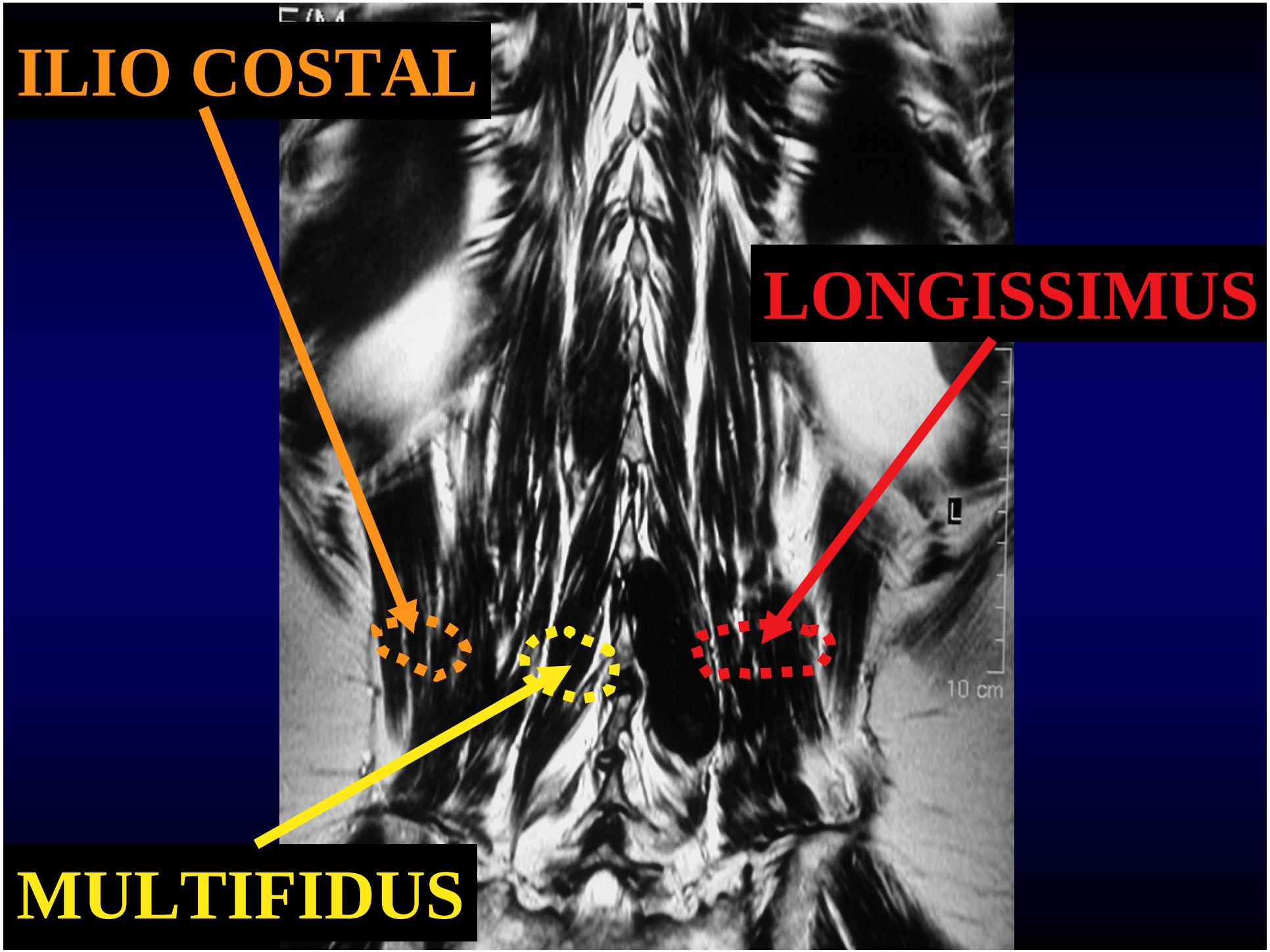
ILIO COSTAL
LONGISSIMUS
MULTIFIDUS
10 cm

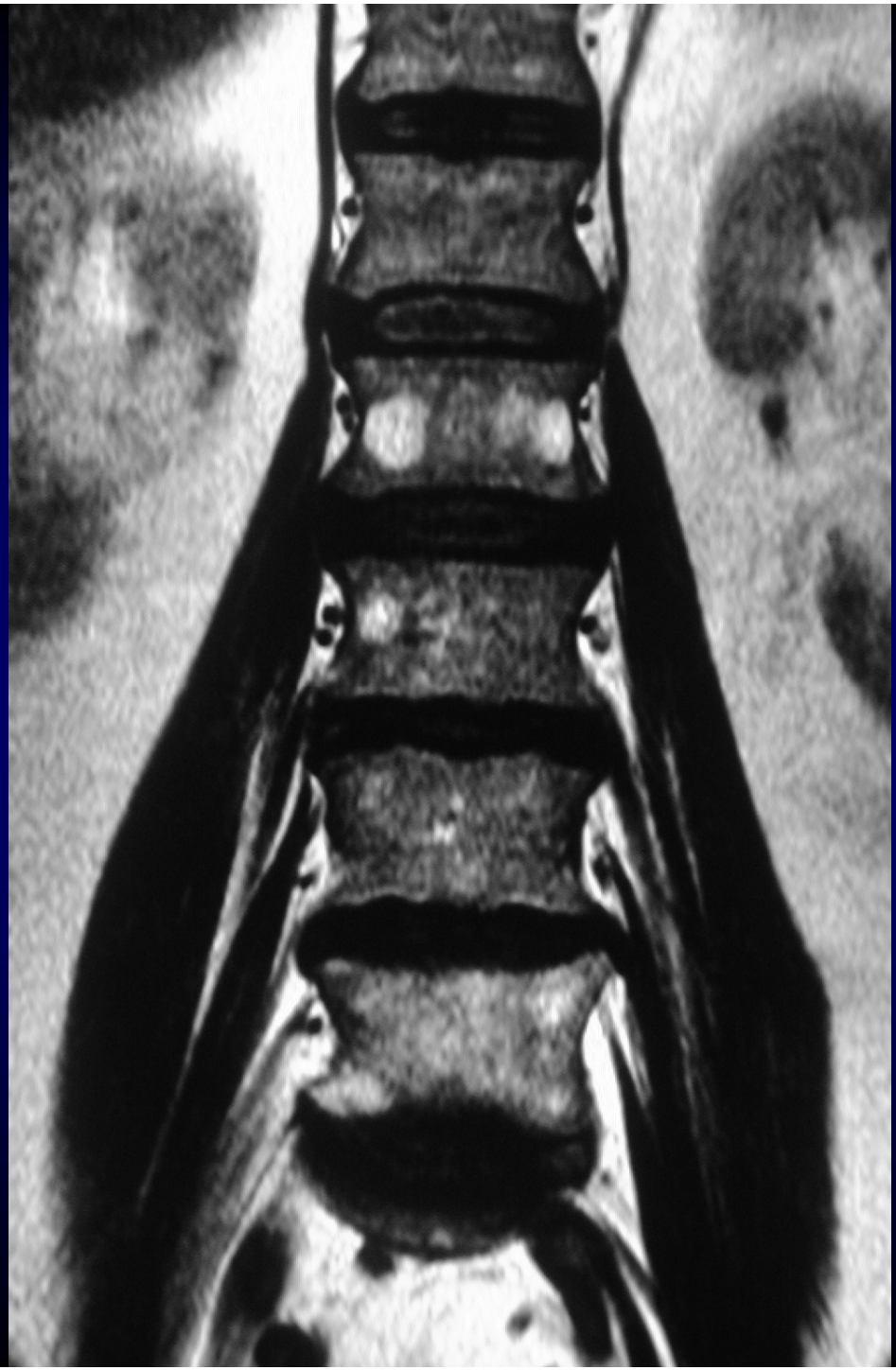

DIAPHRAGME THORACIQUE

MUSCLES de la PAROI ABDOMINALE

DIAPHRAGME PELVIEN

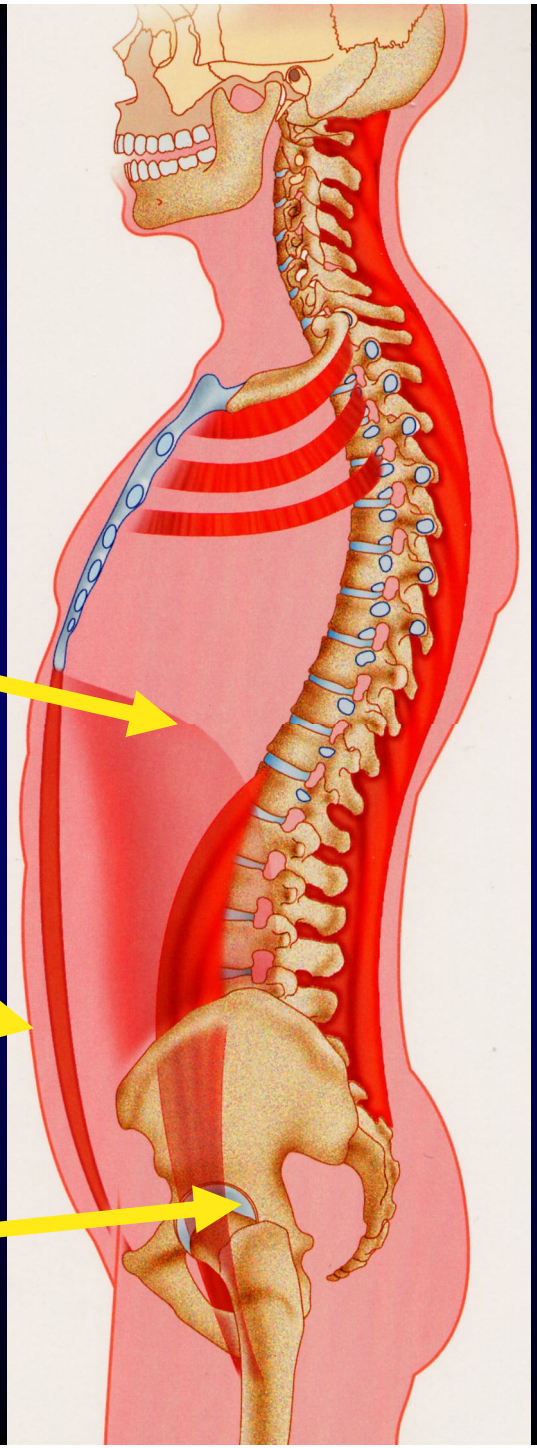

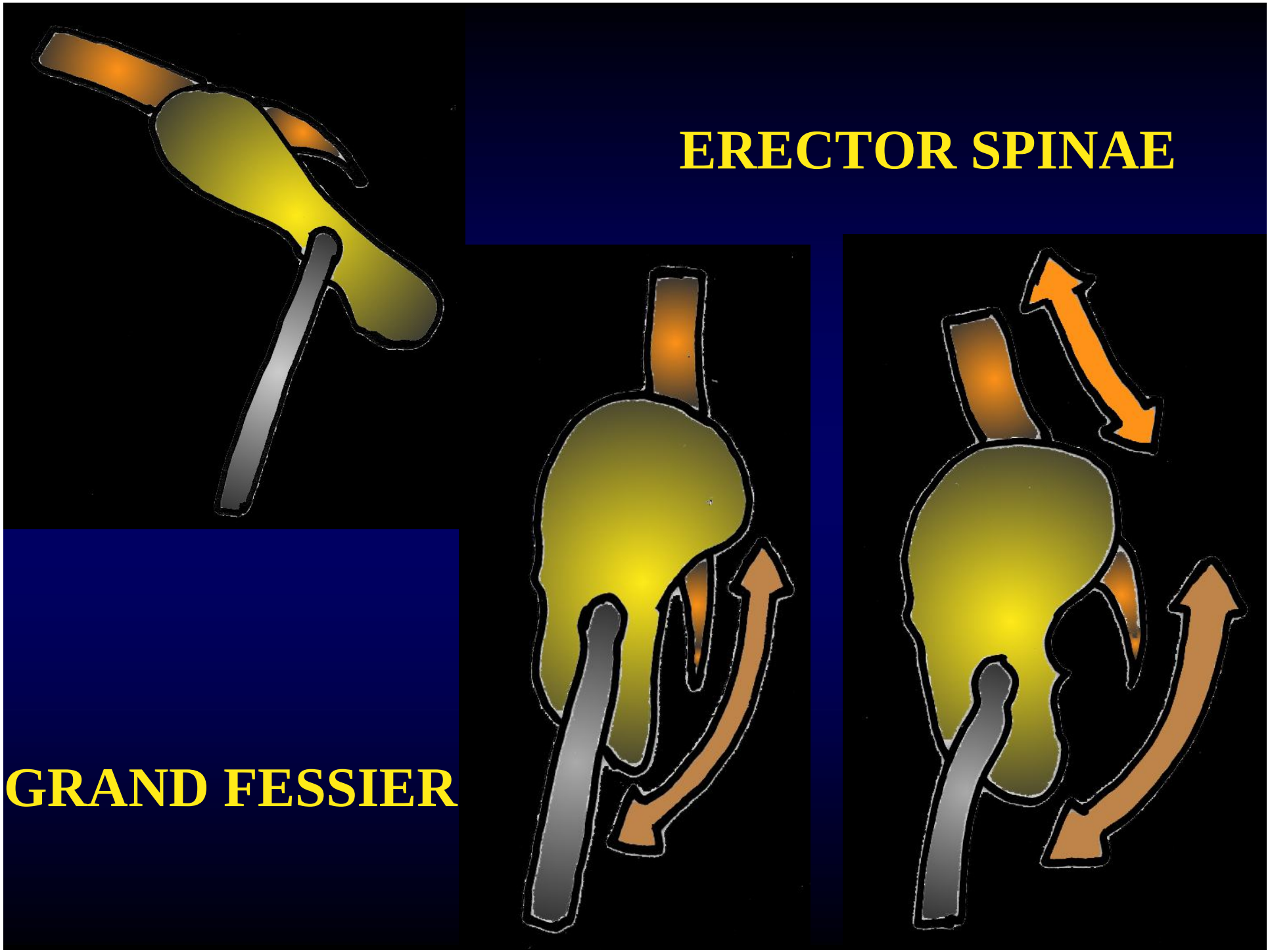
ERECTOR SPINAE
GRAND FESSIER

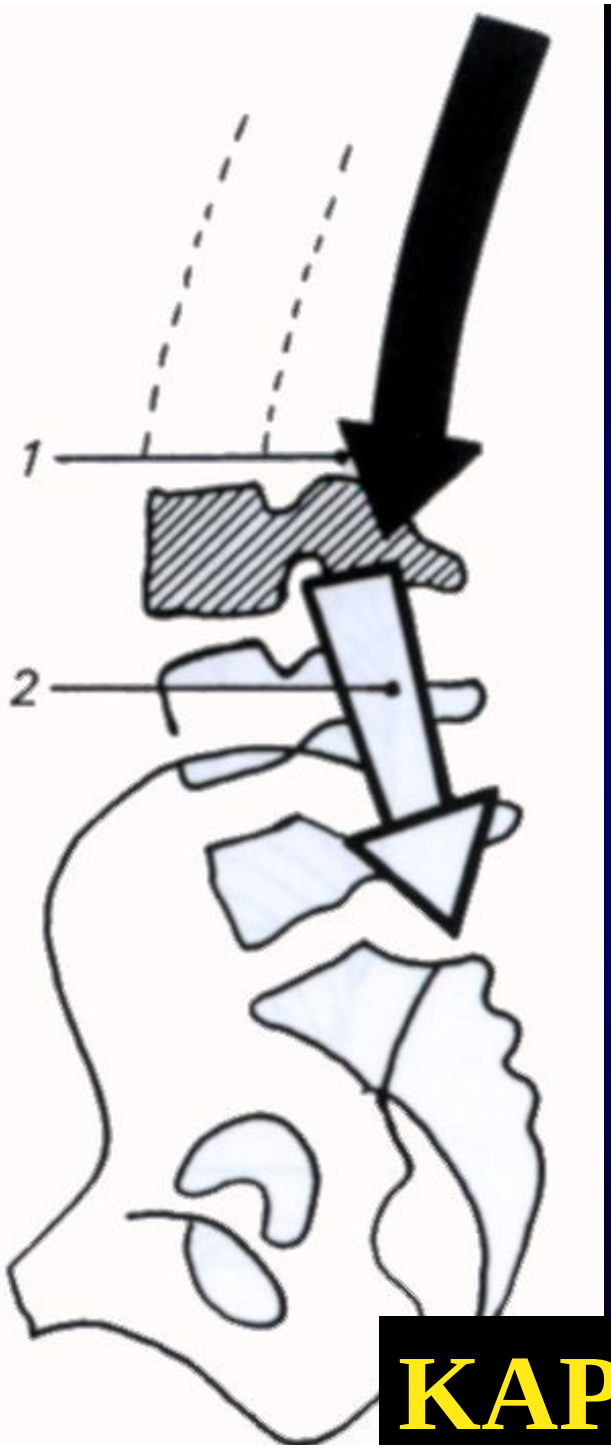

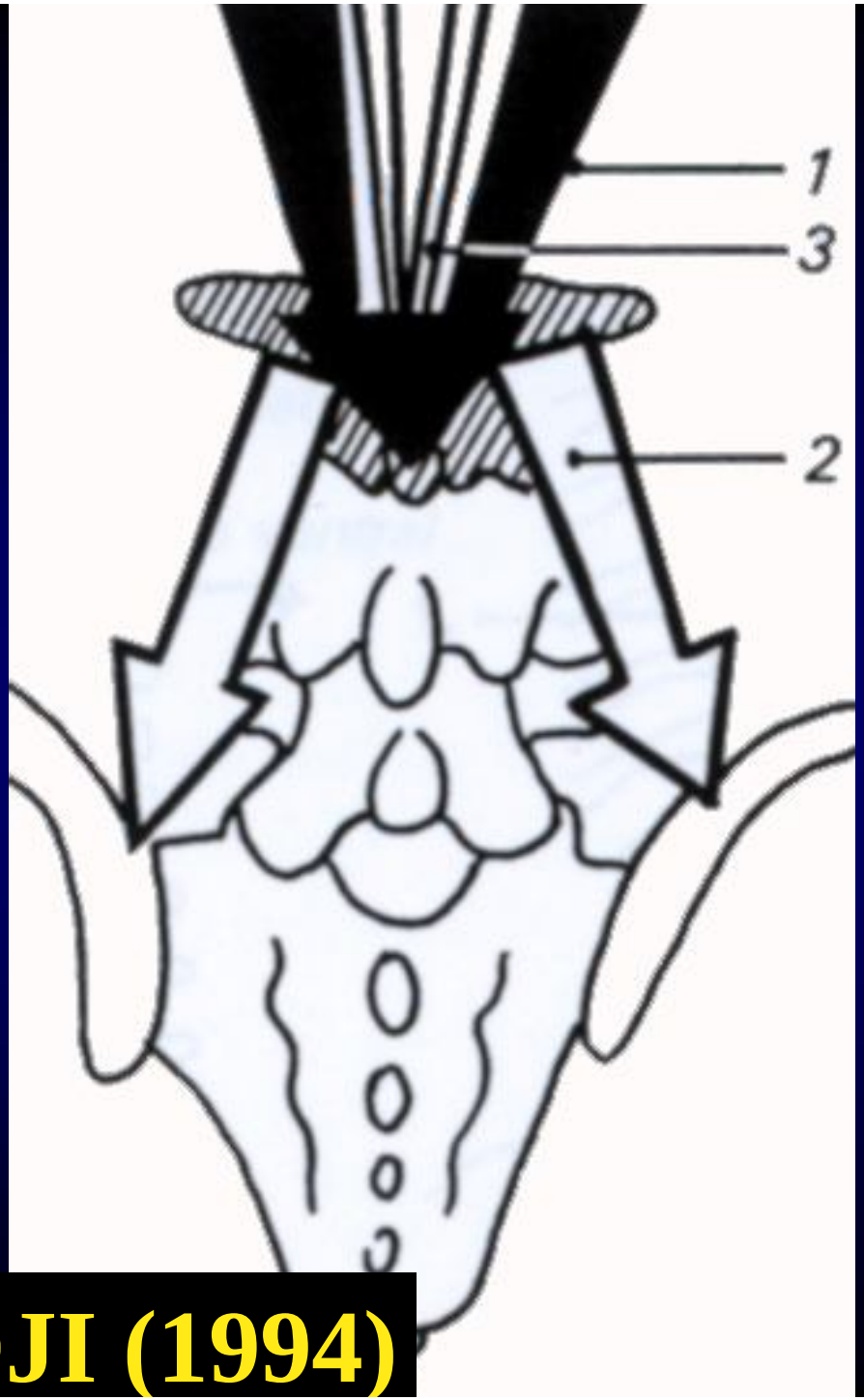

KAPANDJI (1994)

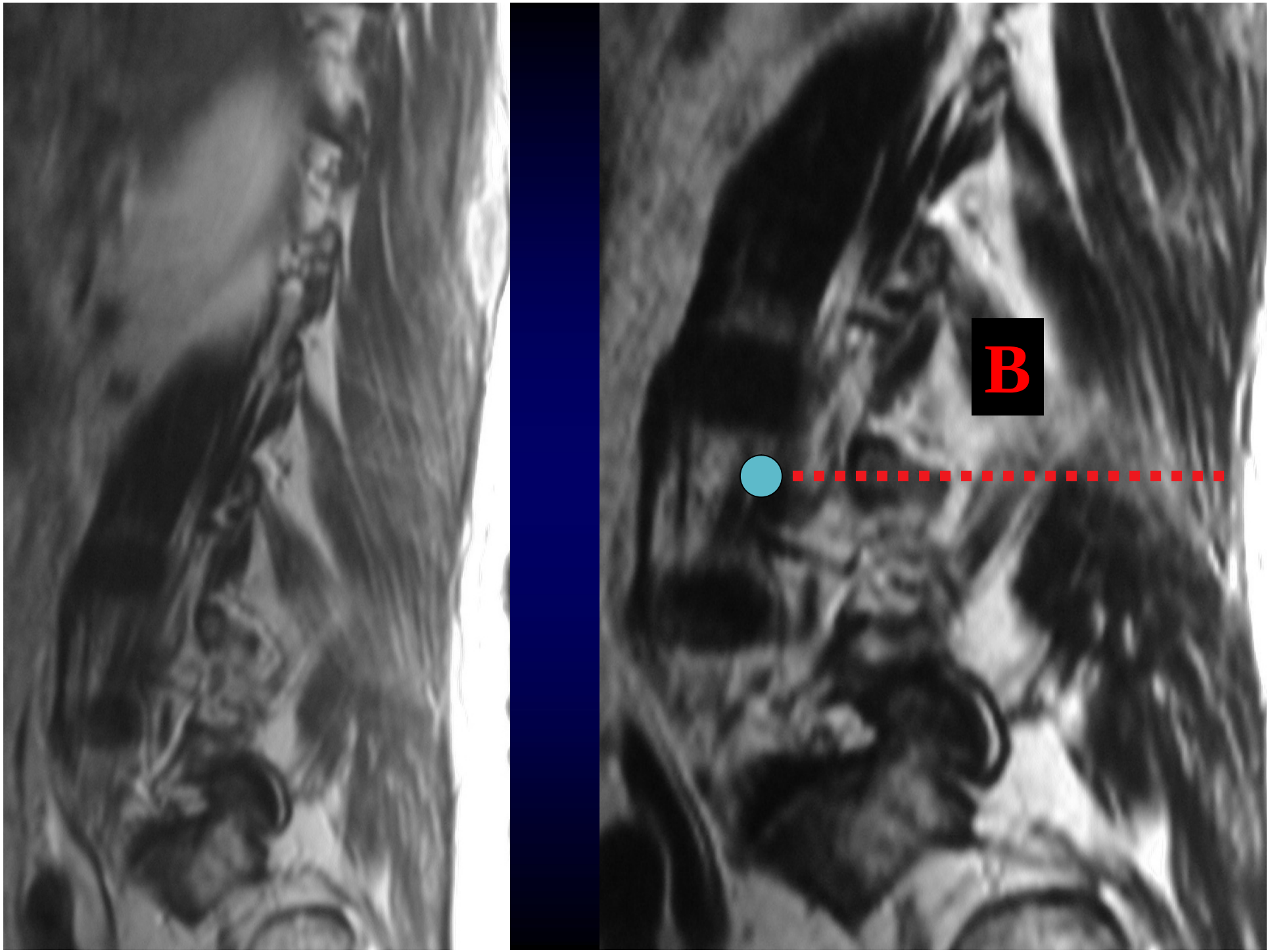
B

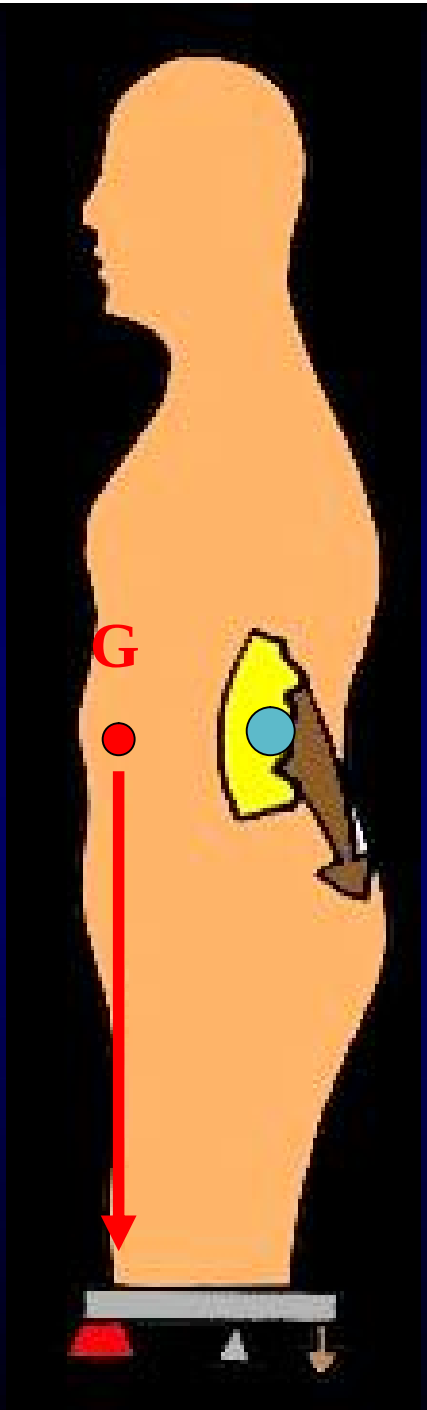
G

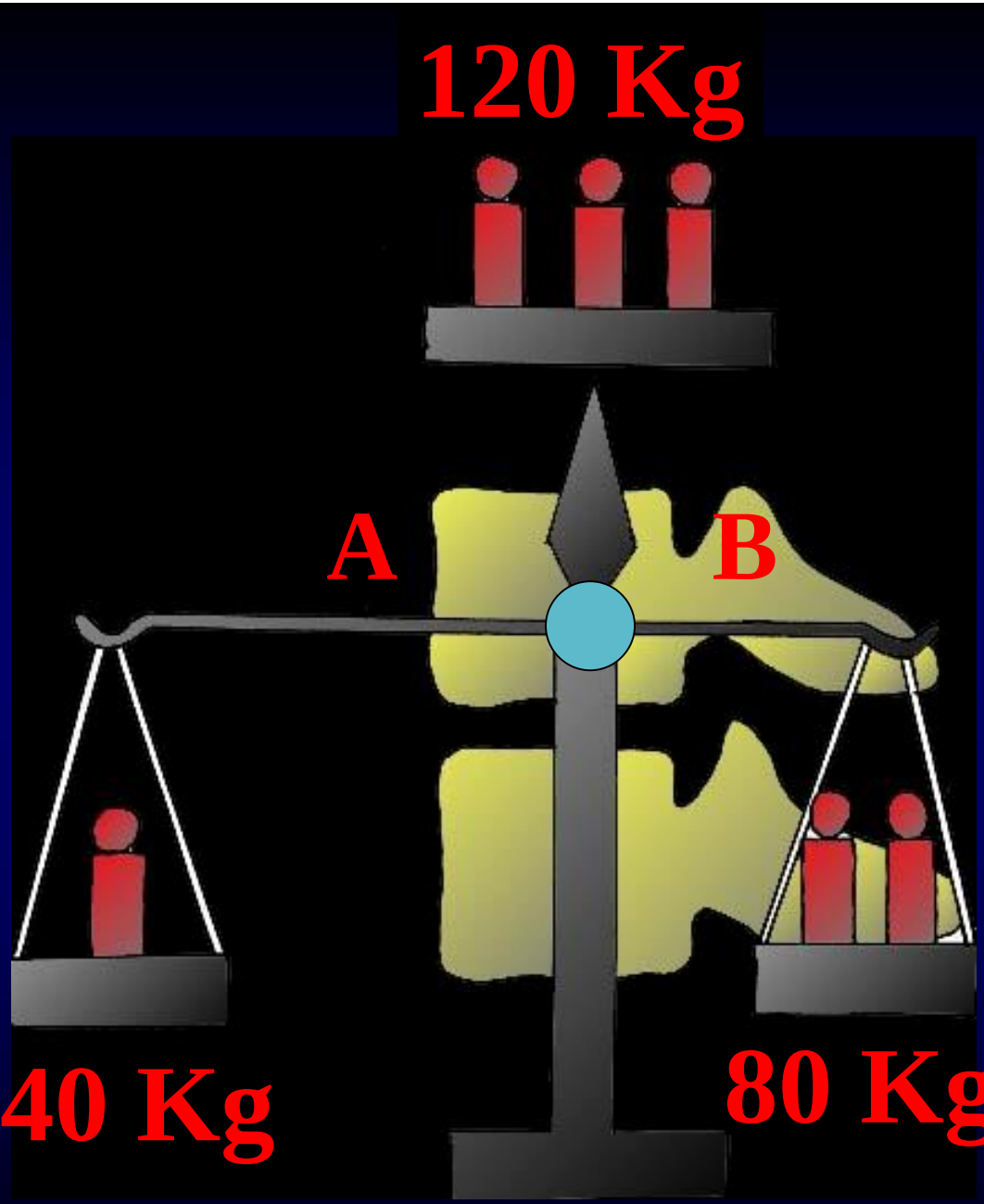
120 Kg
A
B
40 Kg
80 Kg

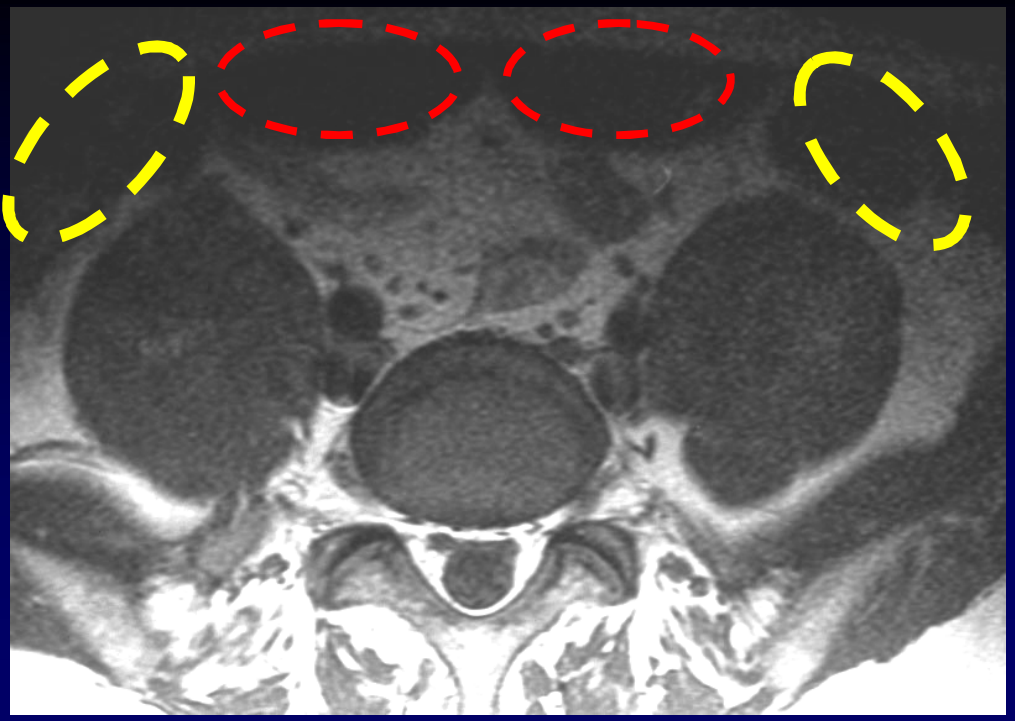

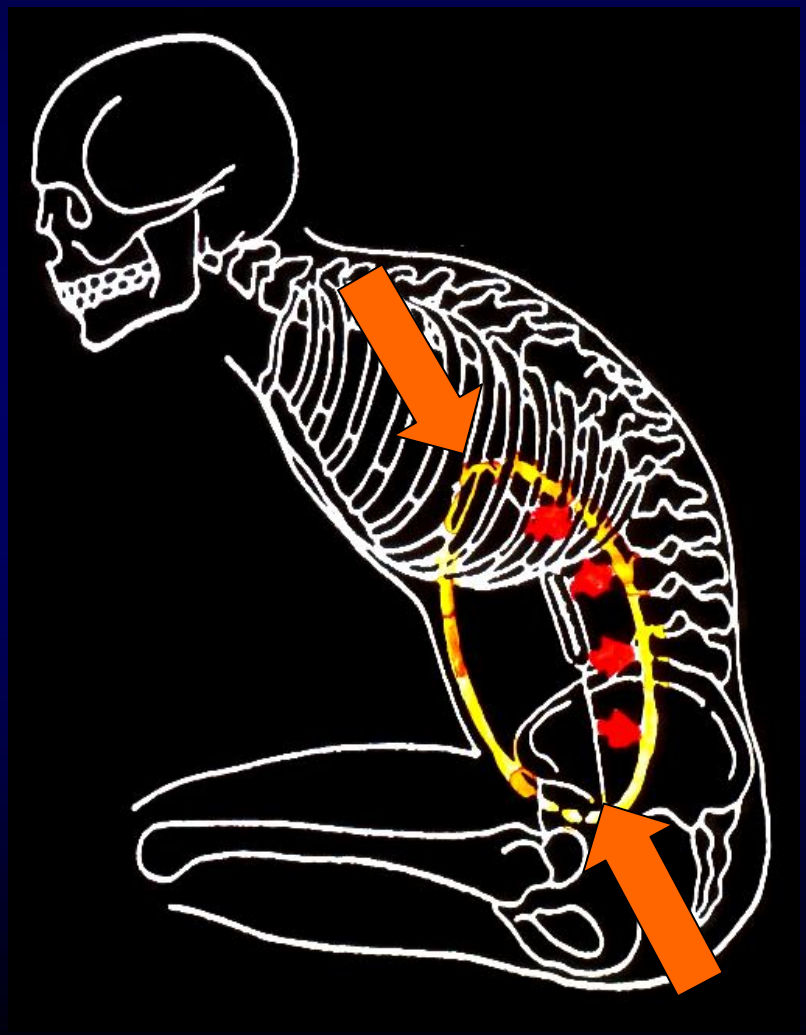

CONTENTION PNEUMATIQUE

ANTERIEURE

EVALUATION de L’EQUILIBRE CORONAL

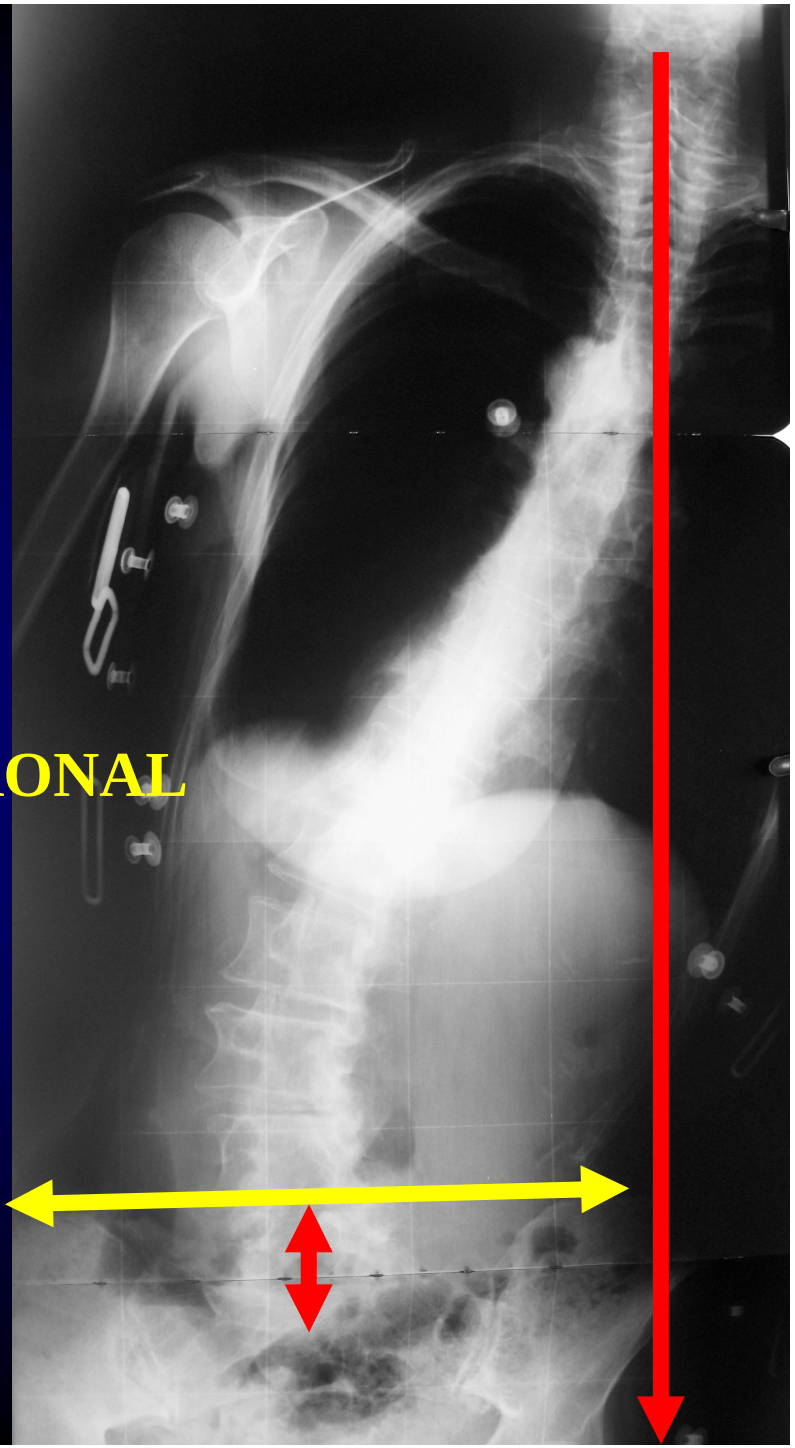

EVALUATION de L’EQUILIBRE SAGITTAL

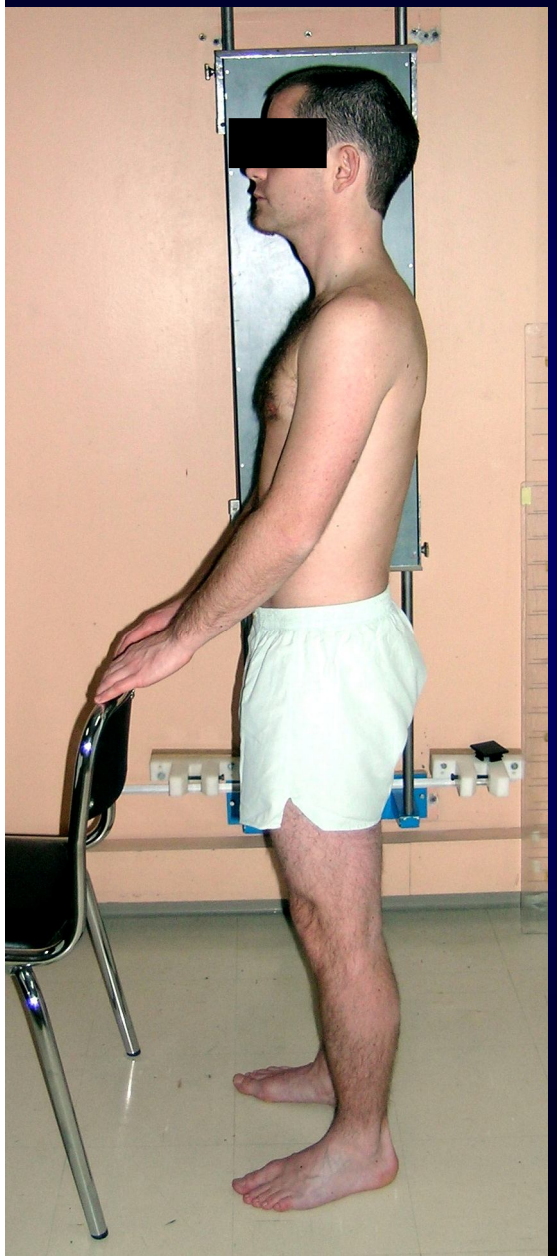

RACHIS COMPLET

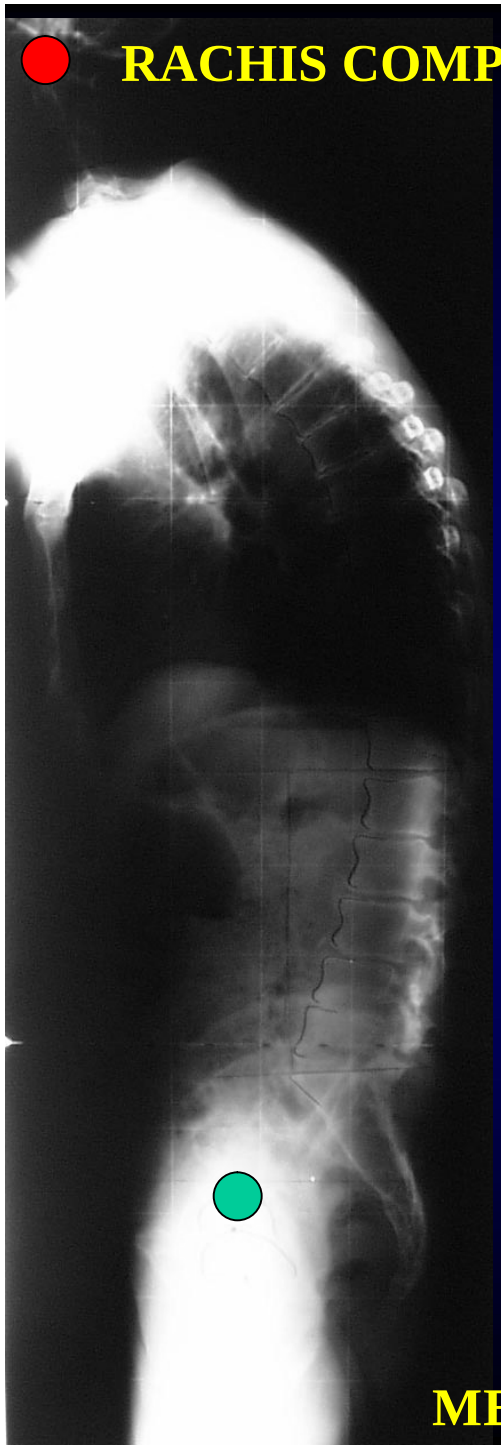

«POSITION NATURELLE»

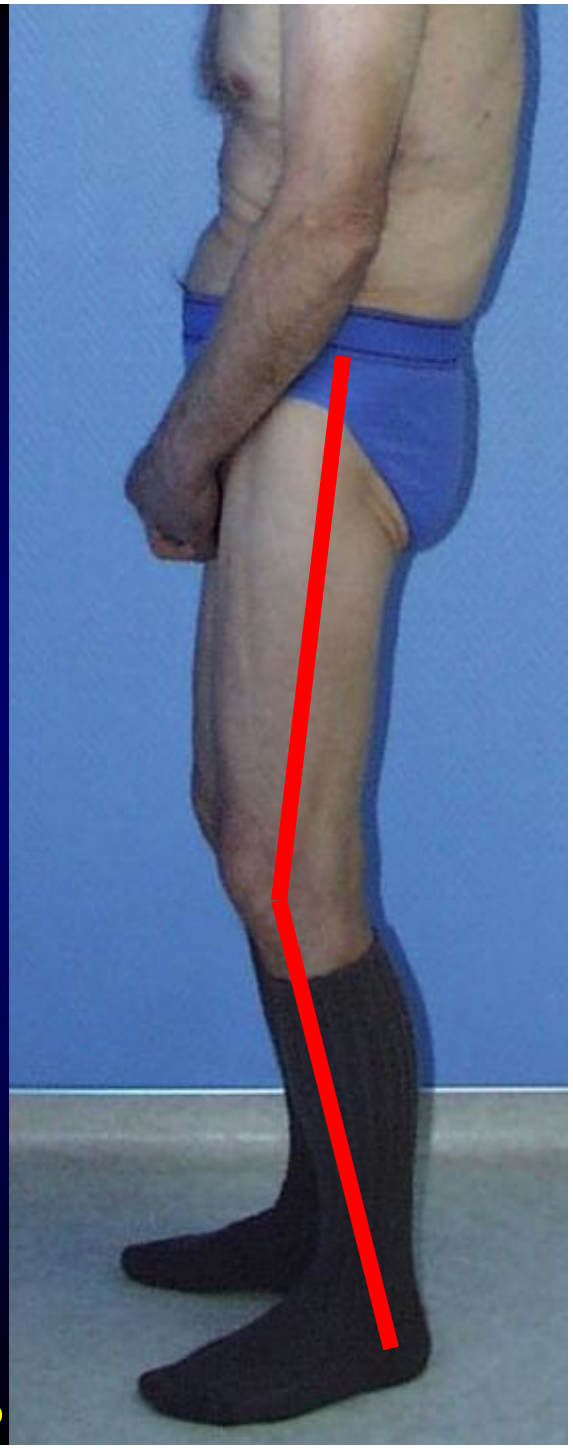

MEMBRES INFERIEURS COMPLETS

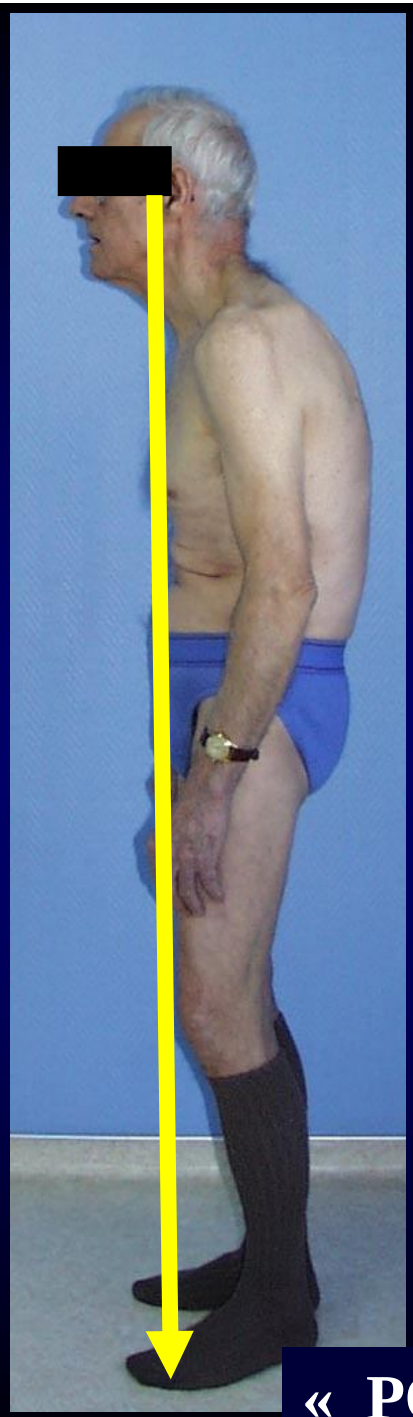

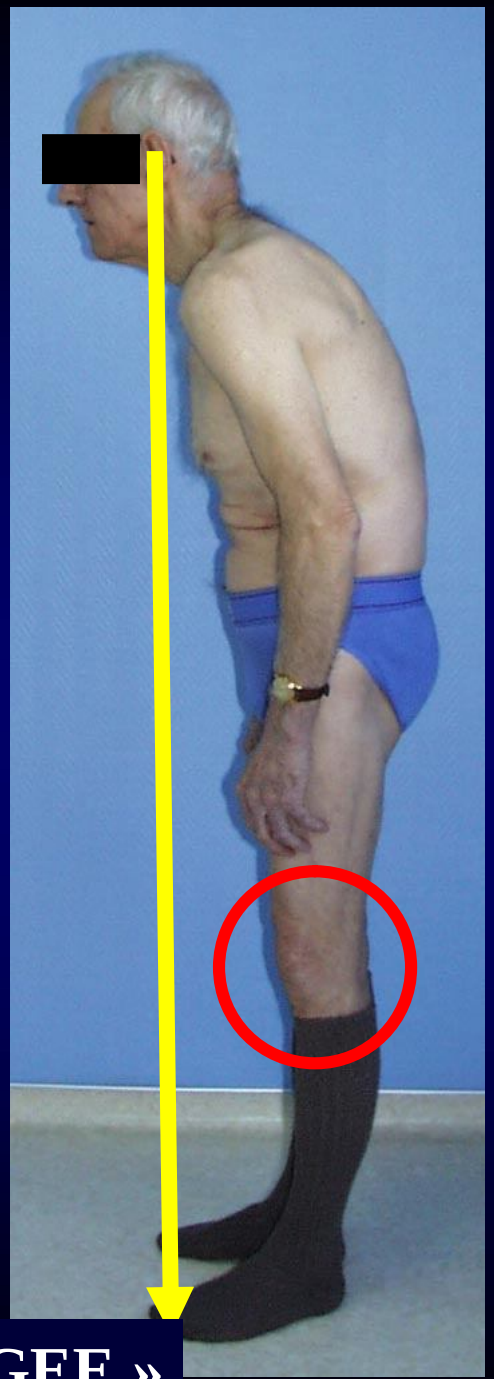

« POSITION CORRIGEE »

CHARPAK



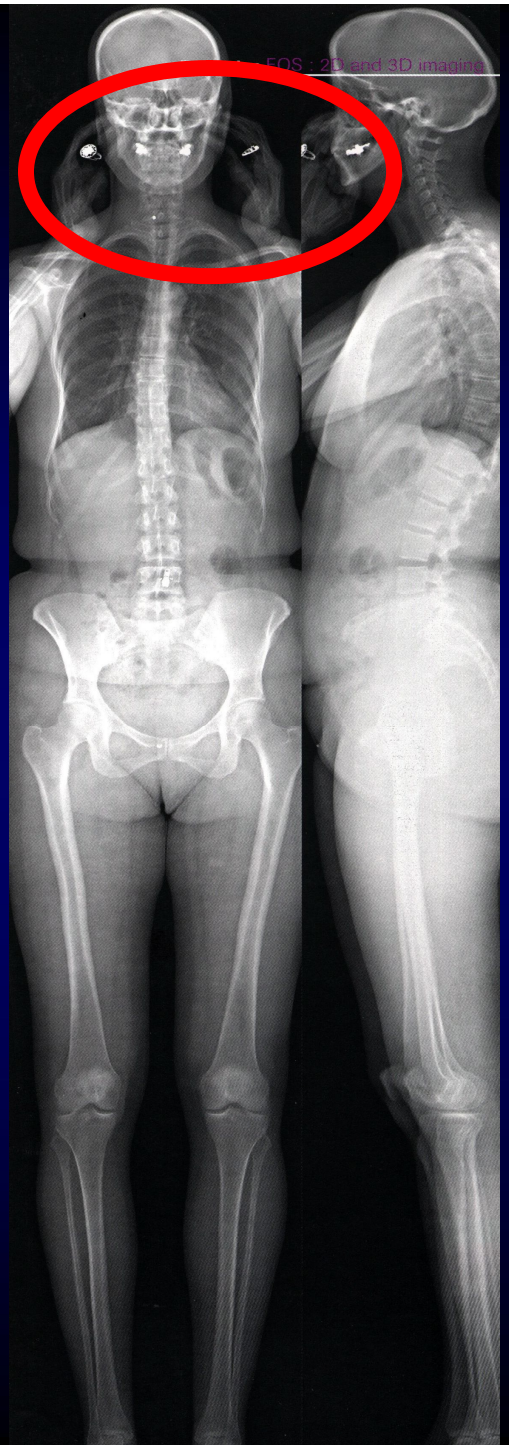



EQUILIBRE

IDEAL OR ECONOMIQUE

EQUILIBRE

COMPENSE

par

Rétroversion pelvienne

+/-Flexion des genoux

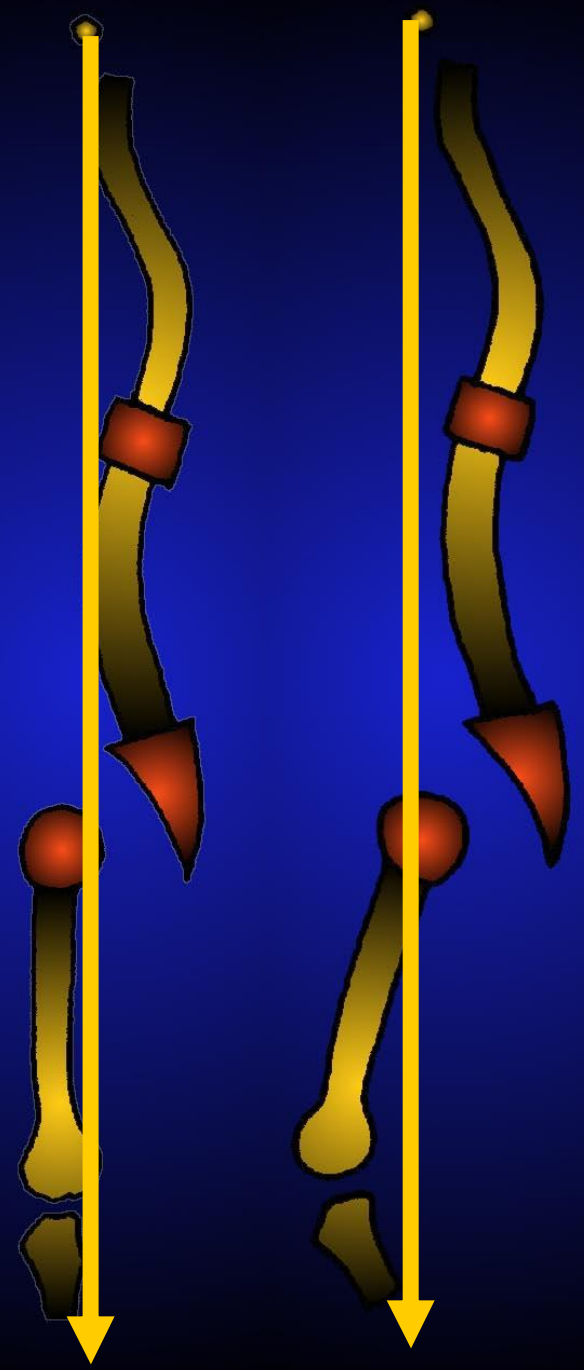

DESEQUILIBRE ANTERIEUR



DESEQUILIBRE MIXTE

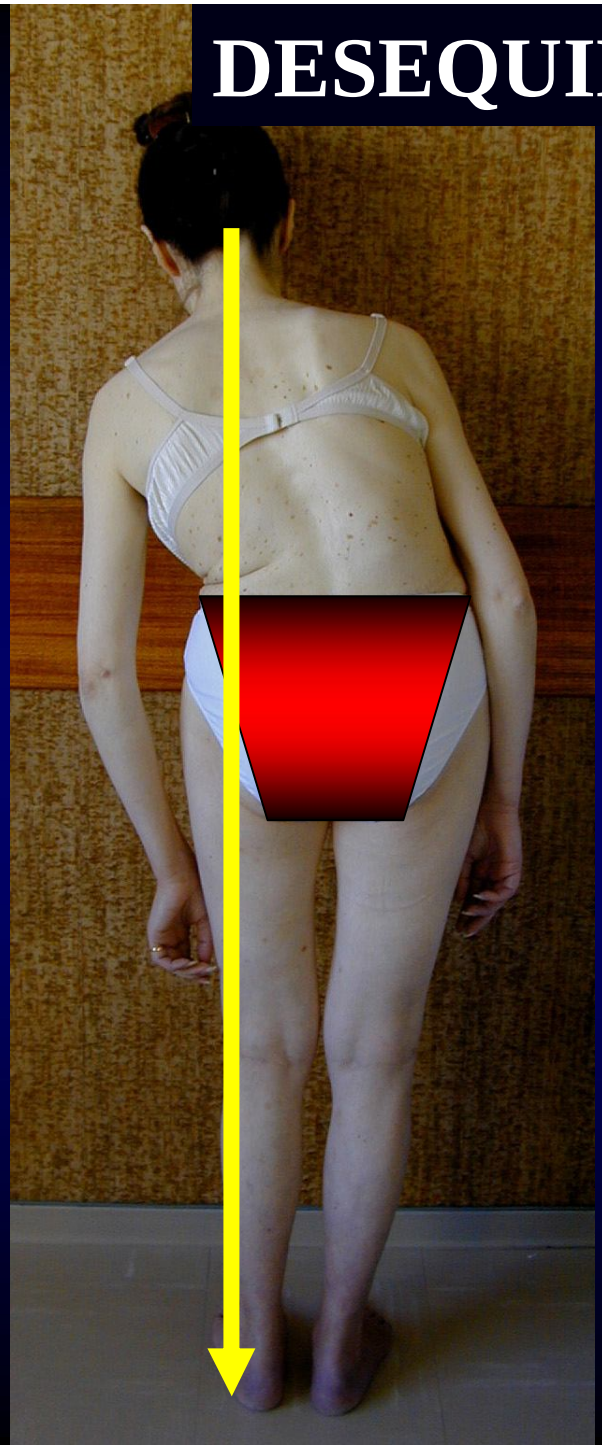

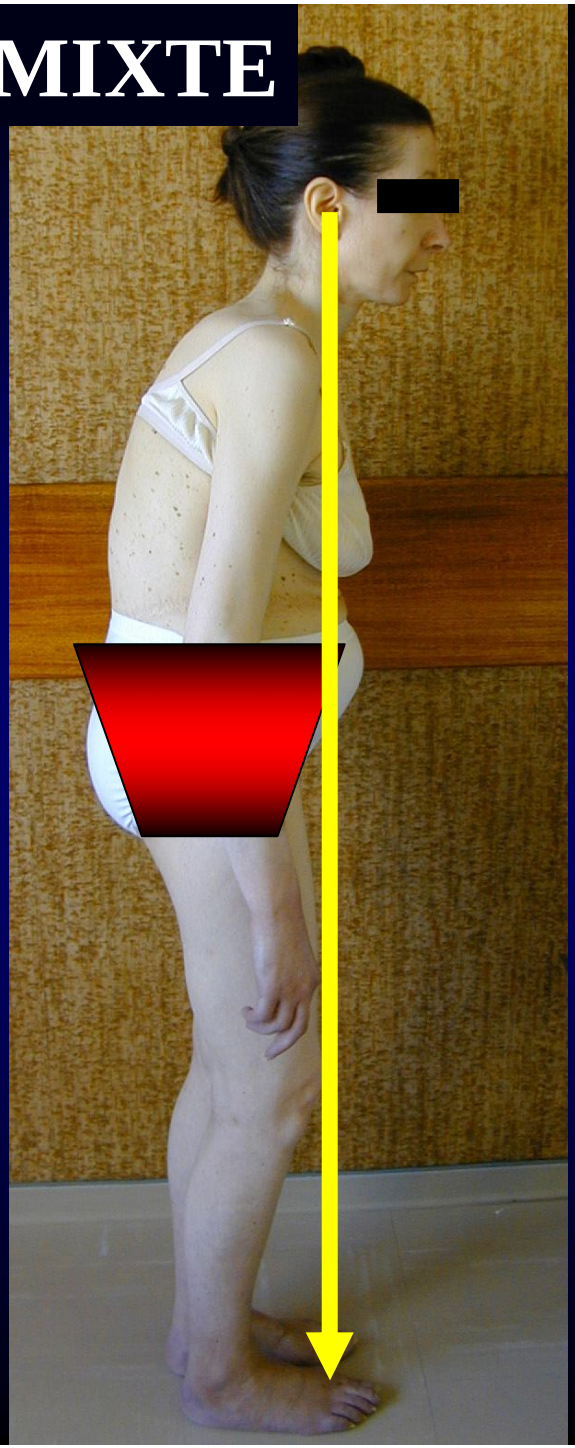

QuickTime™ et un
décompresseur H.263
sont requis pour visionner cette image.

ANALYSE de la MARCHE

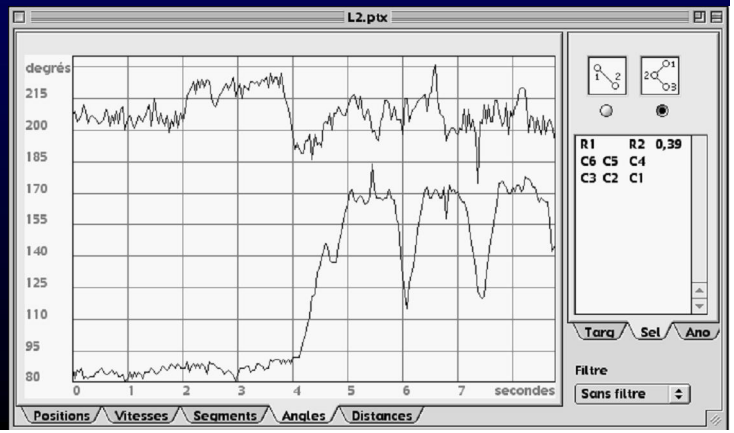

SPIN
©20 035

SPINE 2001

Dynamic Sagittal Imbalance of the Spine in Degenerative Flat Back

Significance of Pelvic Tilt in Surgical Treatment

Choon-Sung Lee, MD,* Choon-Ki Lee, MD,† Yung-Tae Kim, MD,* Young-Mi Hong, MD,‡ and Jeong-Hyun Yoo, MD*

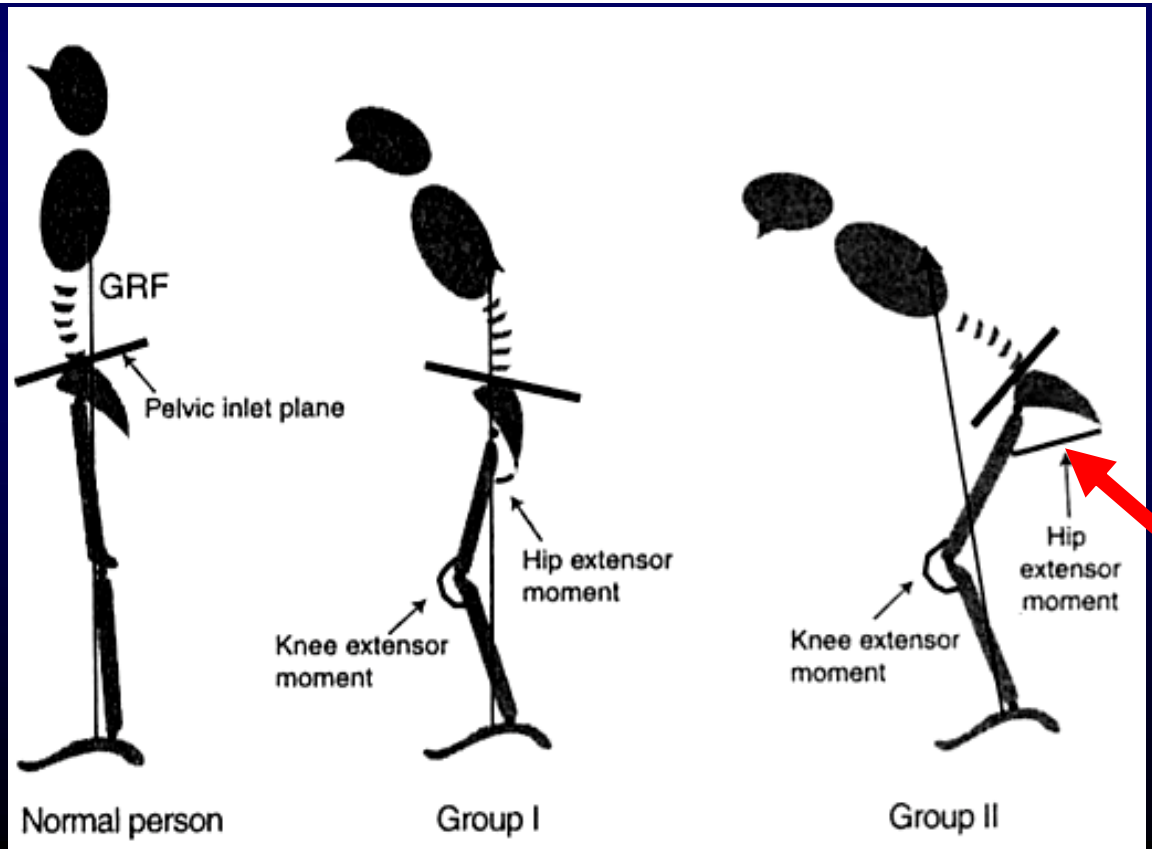

Maladie de PARKINSON (1817)

- « Paralysie agitante »

- Clinique :
  - akinésie
  - dystonie axiale en flexion
  - tremblement (80%)

EXAMEN CLINIQUE

SIGNES EXTRA PYRAMIDAUX PREDOMINANTS

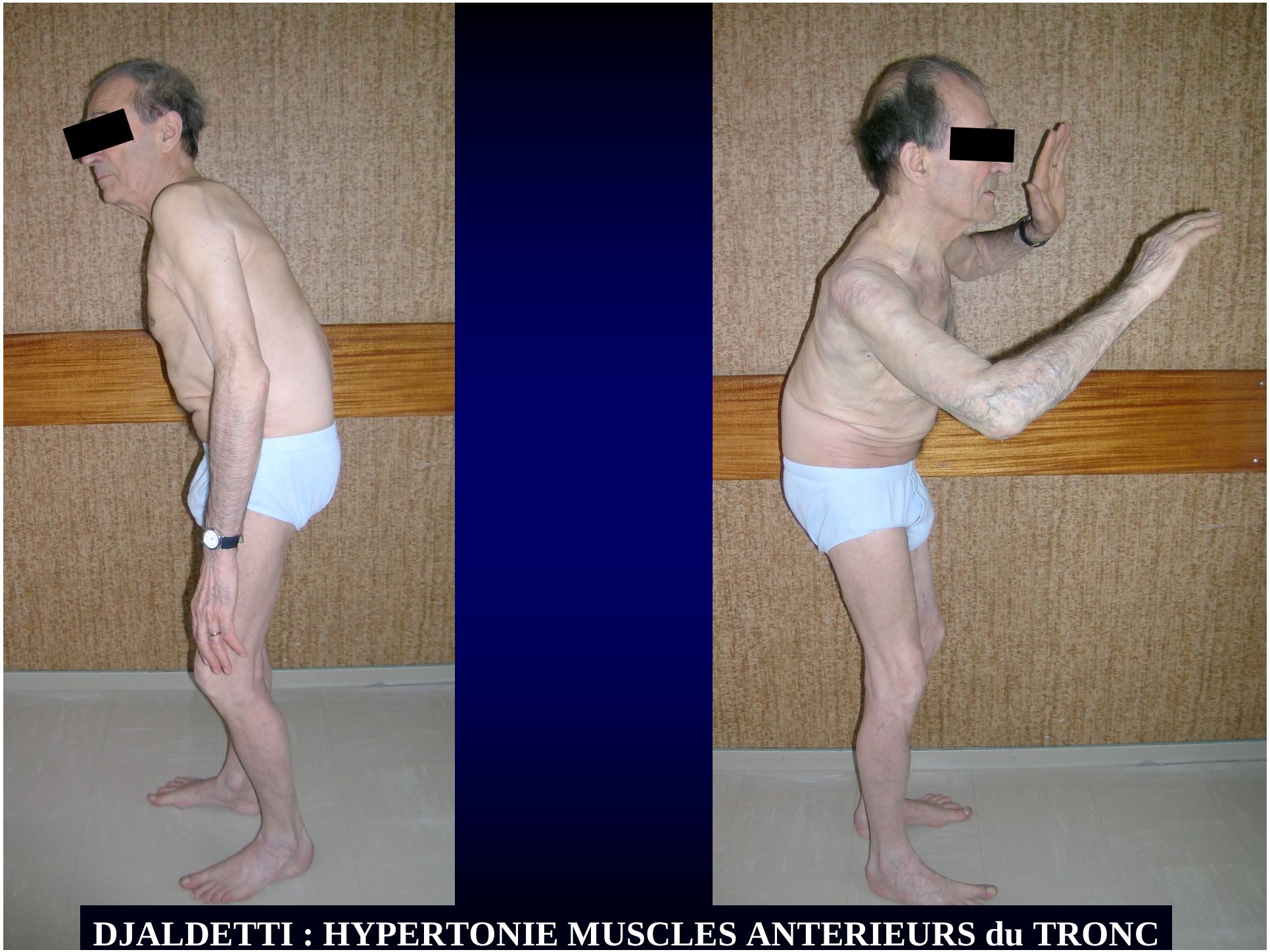

DJALDETTI : HYPERTONIE MUSCLES ANTERIEURS du TRONC

A3=36°
A1=14°
A2=24°

MARCHE

QuickTime™ et un décompresseur
Cinepak Codec par Radius[32] sont requis pour visualiser
cette image.

QuickTime™ et un décompresseur
Cinepak Codec par Radius[32] sont requis pour visualiser
cette image.

BILAN RADIOLOGIQUE

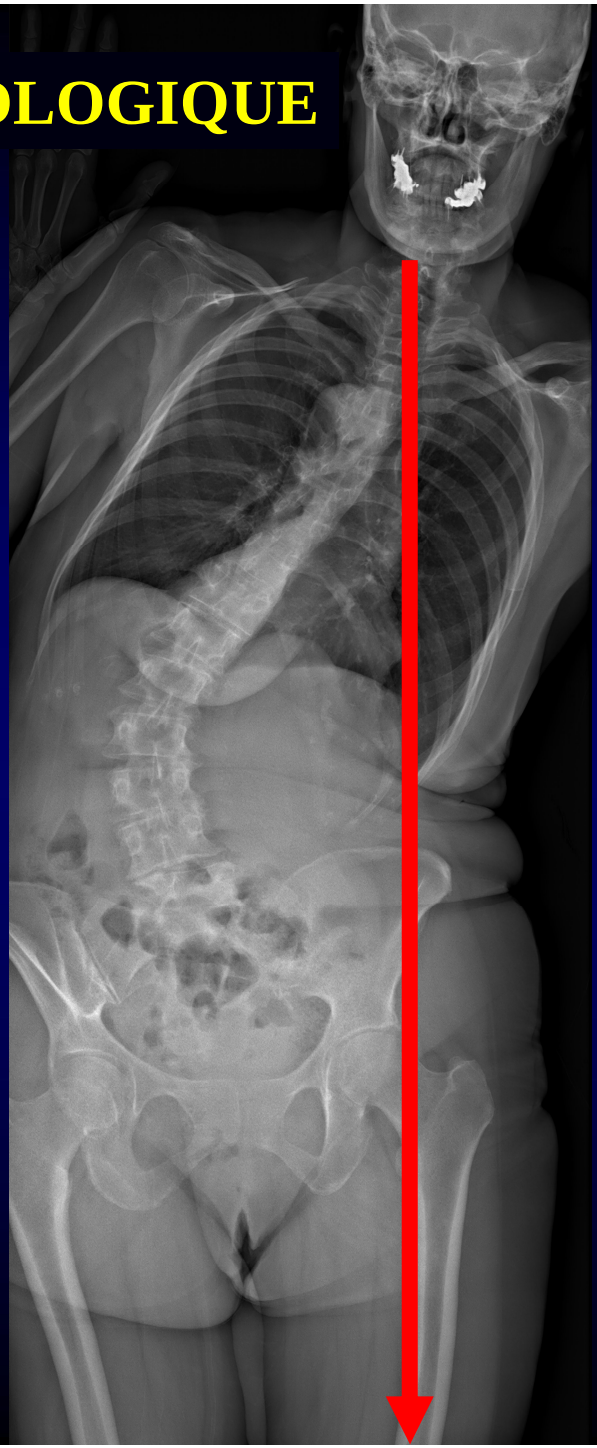

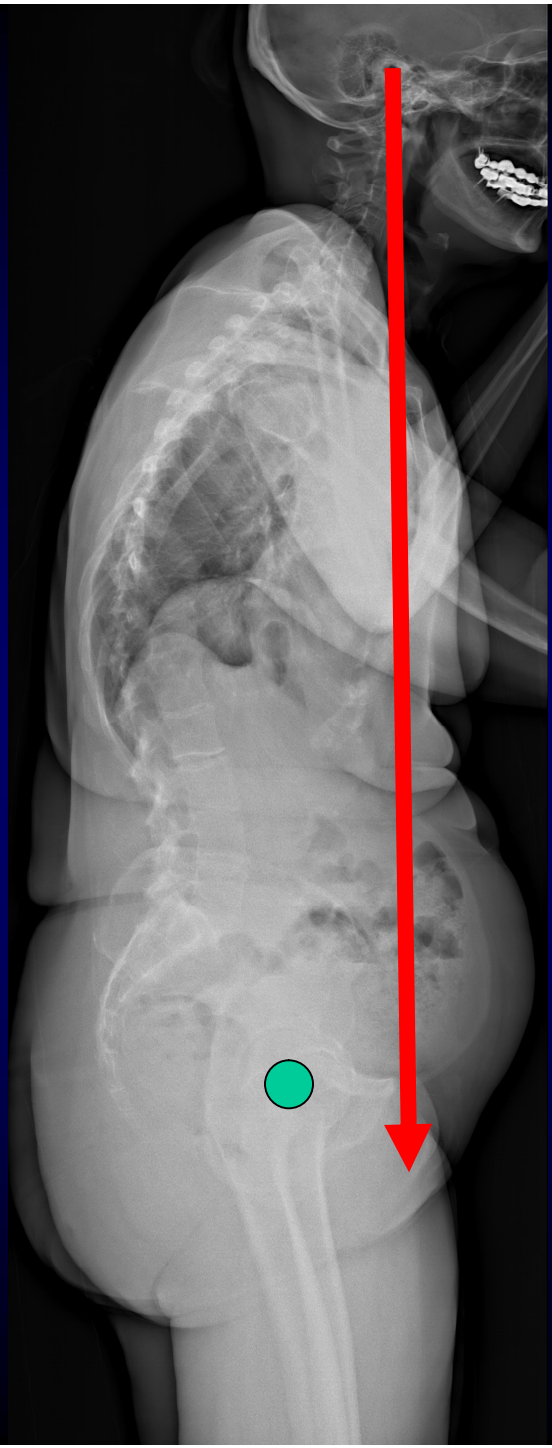



CAMPTOCORMIE

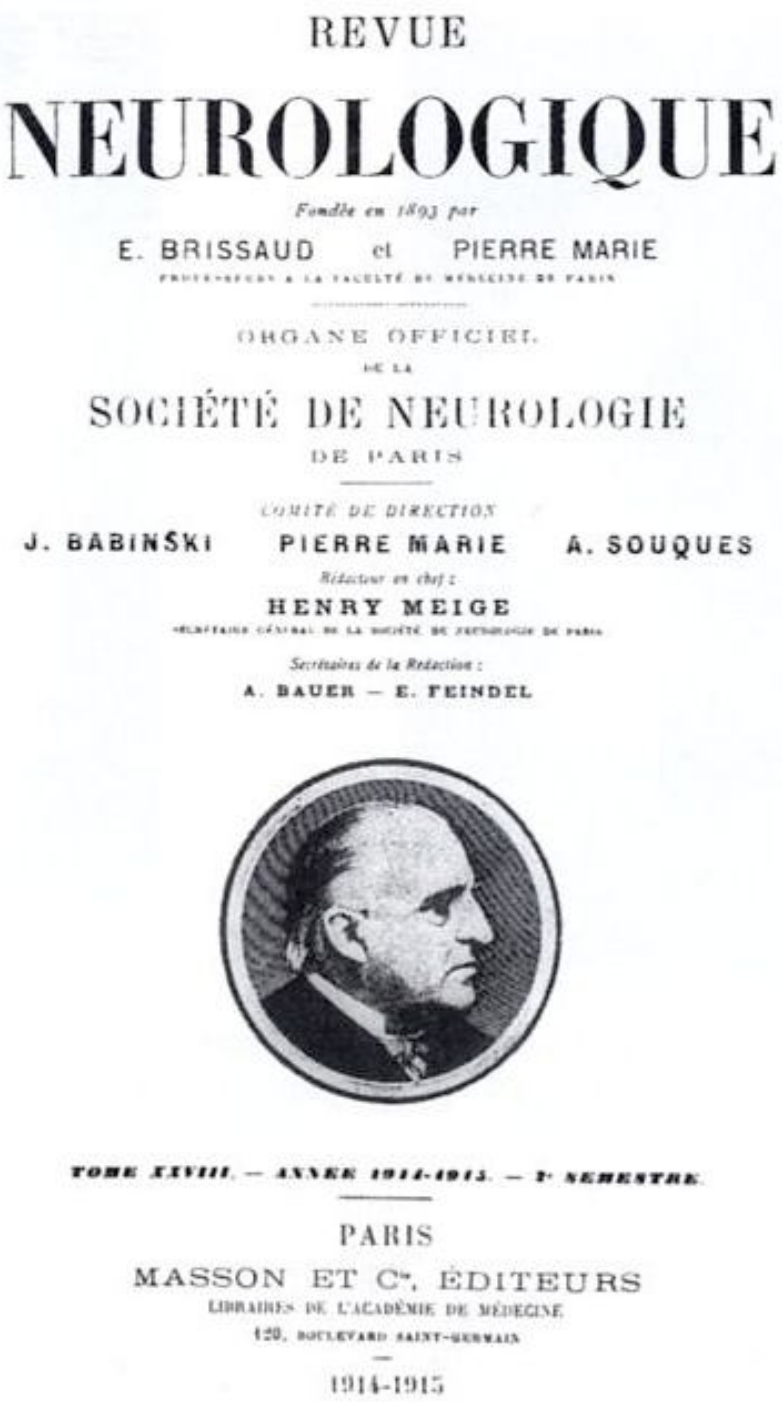

REVUE

NEUROLOGIQUE

Fondée en 1893 par

E. BRISSAUD et PIERRE MARIE

PROFESSEURS A LA FACULTÉ DE MÉDECINE DE PARIS

ORGANE OFFICIEL

DE LA

SOCIÉTÉ DE NEUROLOGIE

DE PARIS

COMITÉ DE DIRECTION

J. BABINSKI PIERRE MARIE A. SOUQUES

Rédacteur en chef :

HENRY MEIGE

SECRÉTAIRE GÉNÉRAL DE LA SOCIÉTÉ DE NEUROLOGIE DE PARIS

Secrétaires de la Rédaction :

A. BAUER — E. FEINDEL

TOME XXVIII. — ANNÉE 1914-1915. — 2e SEMESTRE.

PARIS

MASSON ET Cie, ÉDITEURS

LIBRAIRES DE L'ACADÉMIE DE MÉDECINE

120, BOULEVARD SAINT-GERMAIN

1914-1915

LA CAMPTOCORMIE

INCURVATION DU TRONC, CONSÉCUTIVE AUX TRAUMATISMES DU DOS ET DES LOMBES

CONSIDÉRATIONS MORPHOLOGIQUES

PAR

M. **Souques** et Mme **Rosanoff-Saloff**.

Société de Neurologie de Paris.

(Séance du 4 novembre 1915.)

Nous désirons exposer quelques brèves considérations morphologiques sur l'incurvation spéciale du tronc, que l'on observe si fréquemment chez les soldats, à la suite des traumatismes les plus variés du tronc, surtout du dos et des lombes, et dont nous présentons quatre exemples.

L'un de nous, M. Souques, propose de donner à cette incurvation le nom de *camptocormie* (καμπτω, je fléchis, je courbe ; κορμος, le tronc). Il lui semble qu'il y aurait avantage à adopter un terme univoque pour désigner une attitude du tronc, qui est la même, quelle qu'en soit la cause, et qui jusqu'ici porte différents noms. Certains auteurs parlent de *plicature*, de *cyphose*. Si le terme de plicature est acceptable, celui de cyphose qui, par définition, veut dire « cour-

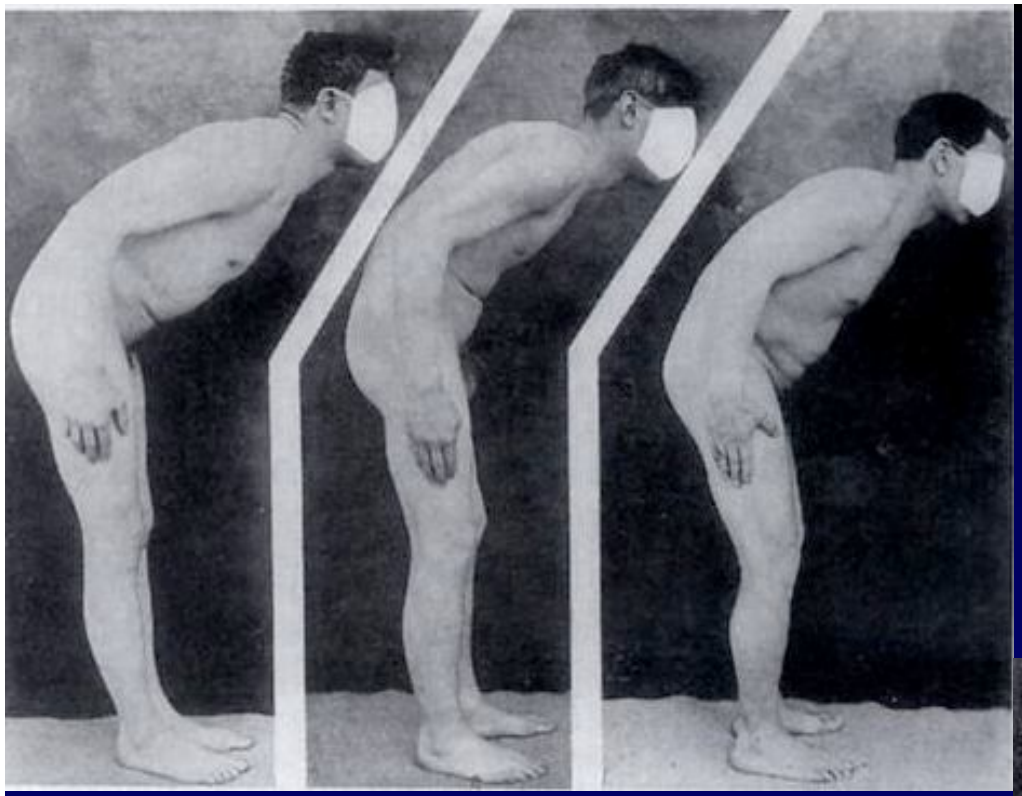

ELECTROTHERAPIE « SUGGESTIVE »

The Old and the New Camptocormia

Kazimierz Karbowski, MD

Spine 1999

Feature	Old Camptocormia	New Camptocormia
Age/sex	Young men	Aged women
Manifestation	Acute postural changes	Chronically progressive
Main cause	Psychogenic	Somatic
Cases in family	None	Frequent
Effective treatment	Psychotherapy	Corticosteroids

FACTEURS AGGRAVANTS

-VIEILLISSEMENT NATUREL

- OSTEOPOROSE

-SCOLIOSE PREEXISTANTE

-CHIRURGIE RACHIDIENNE LOCALISEE

VIEILLISSEMENT

INVOLUTION

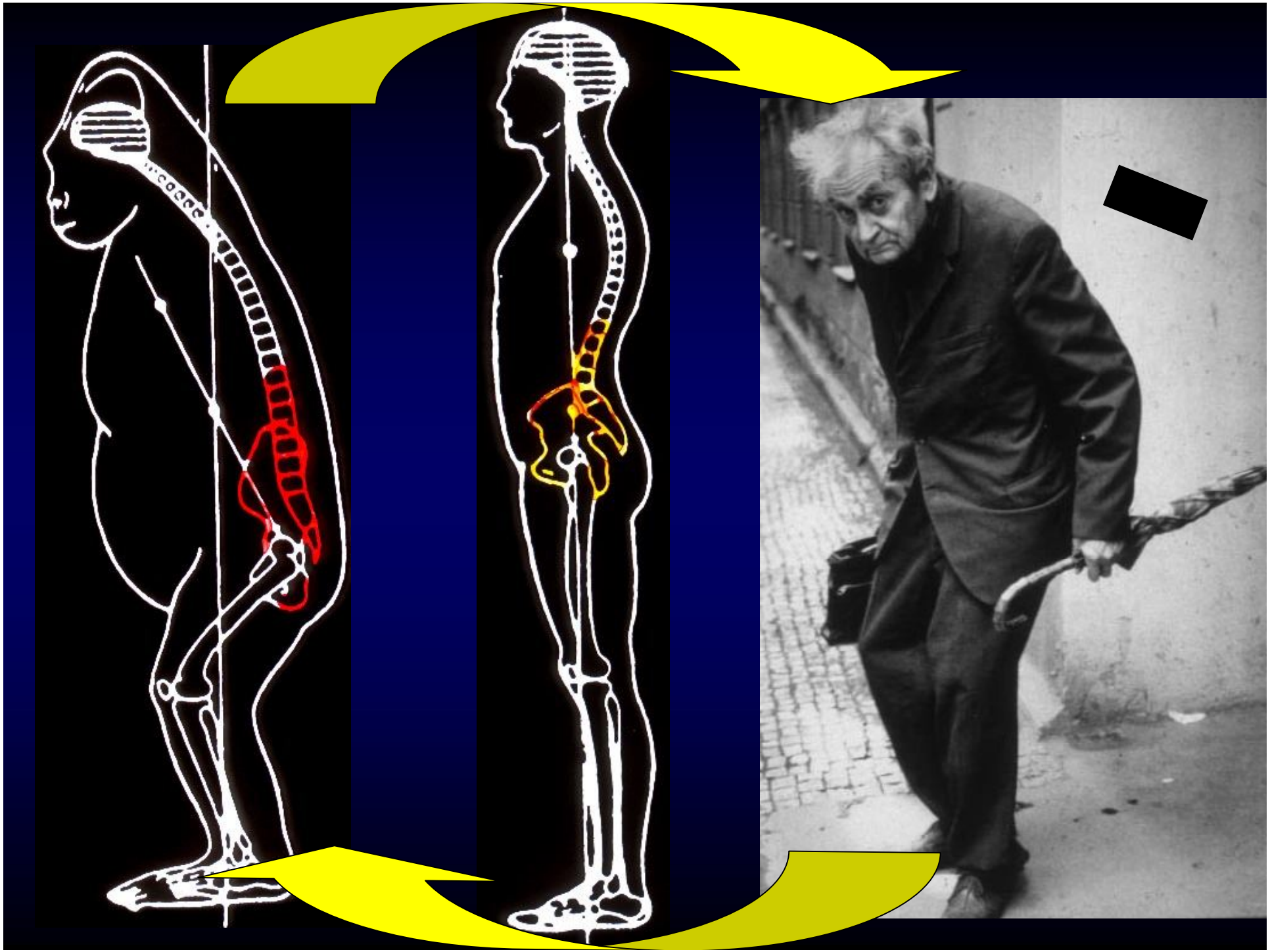

CYPHOSE DEGENERATIVE

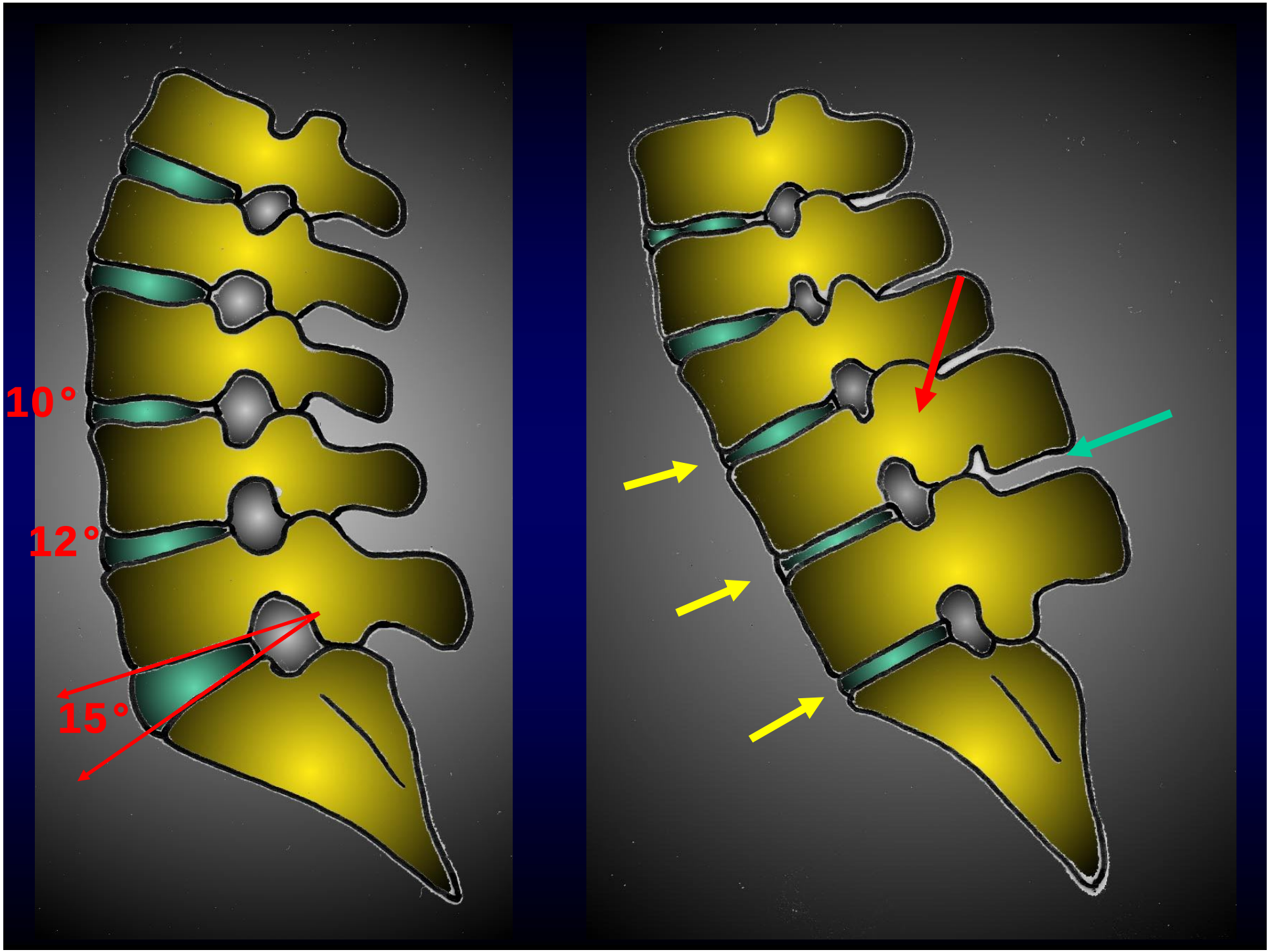
10°
12°
15°

FACTEURS PROFESSIONNELS

TAKEMITSU,1988

ANOMALIES MITOCHONDRIALES

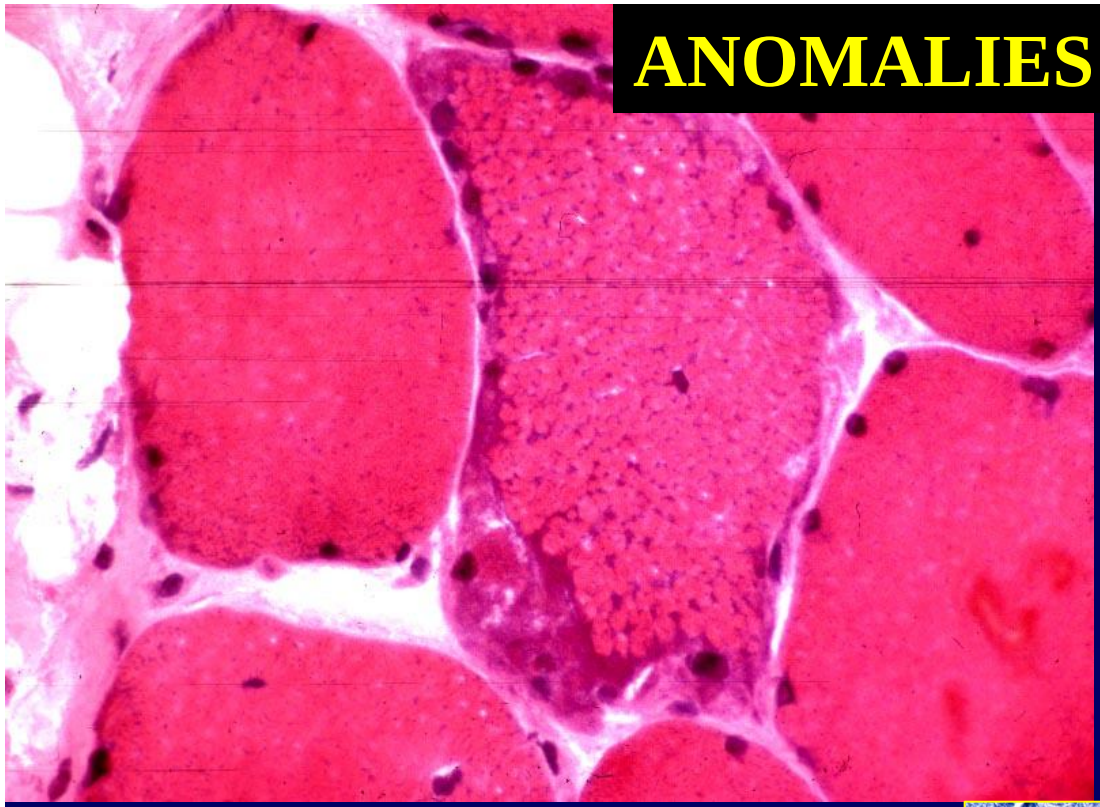

CORE TARGETOID

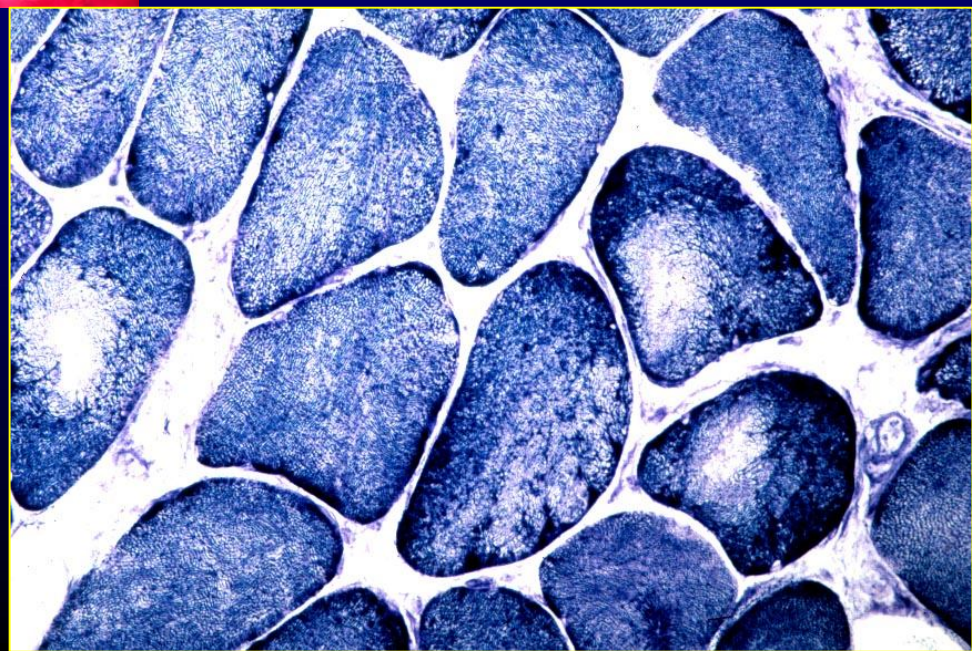

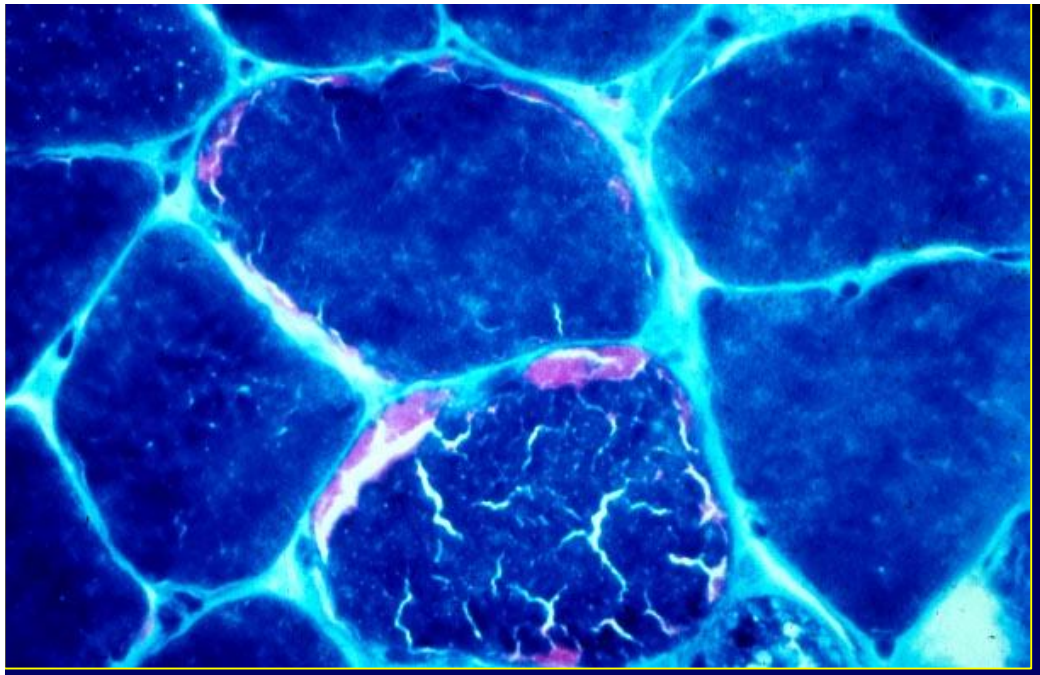

RAGGED RED F.

« MYOPATHIE »

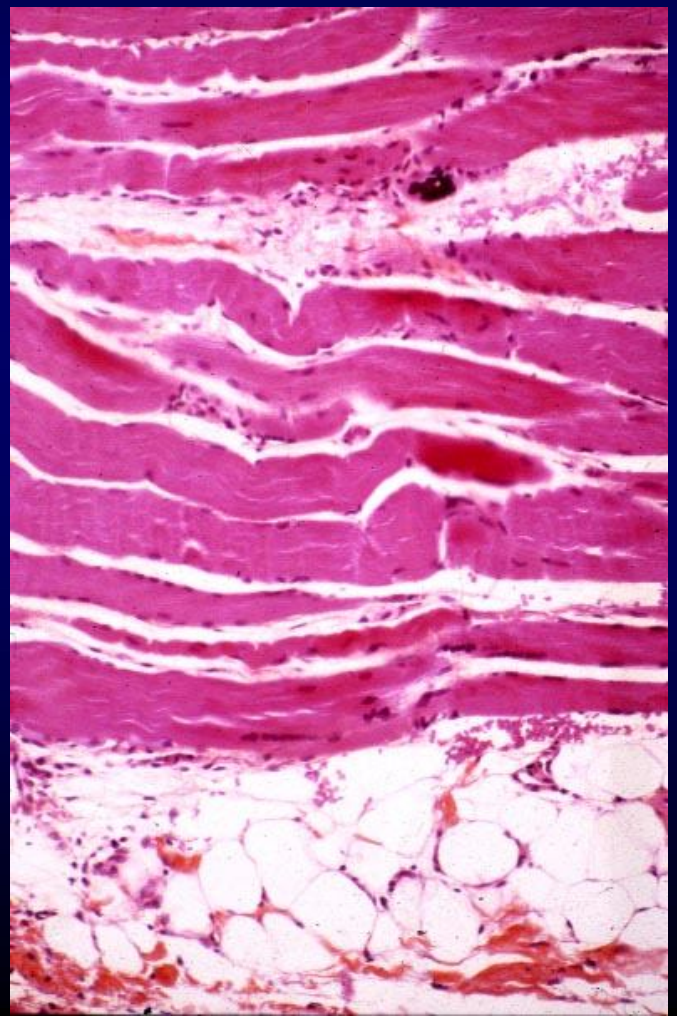

FIBROADIPOSE

DEGENERESCENCE GRAISSEUSE

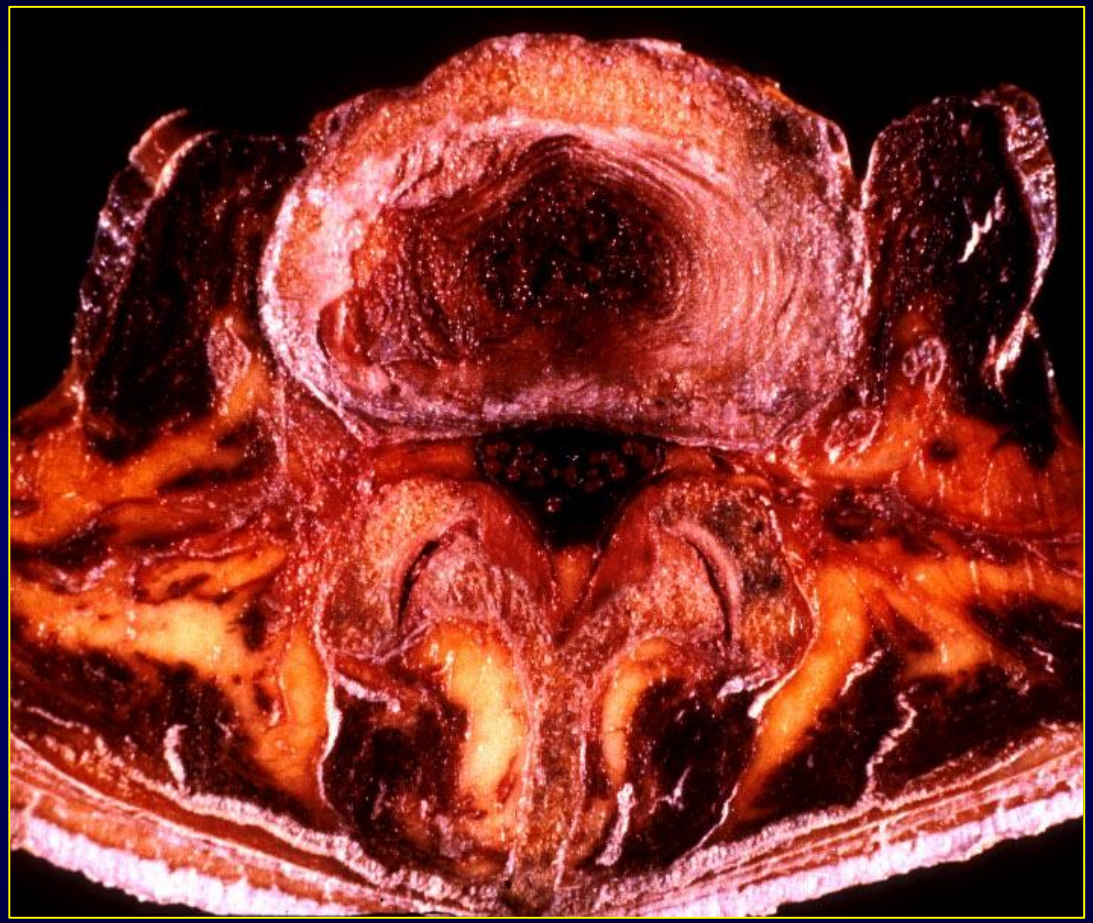

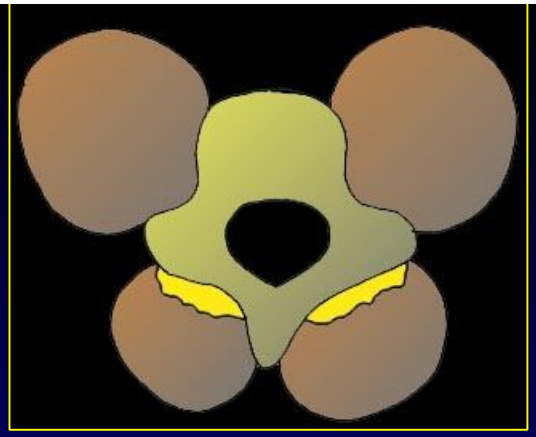

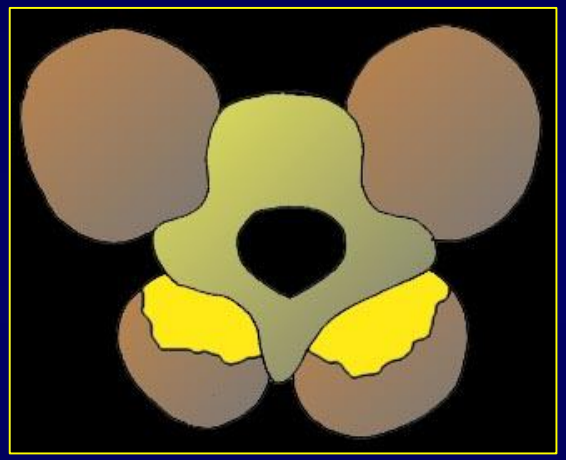

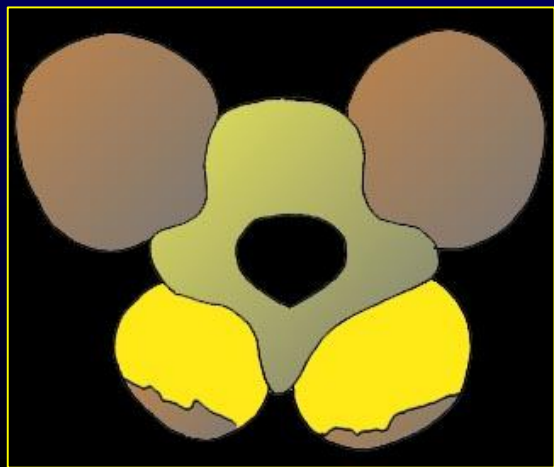

HADAR (1989)

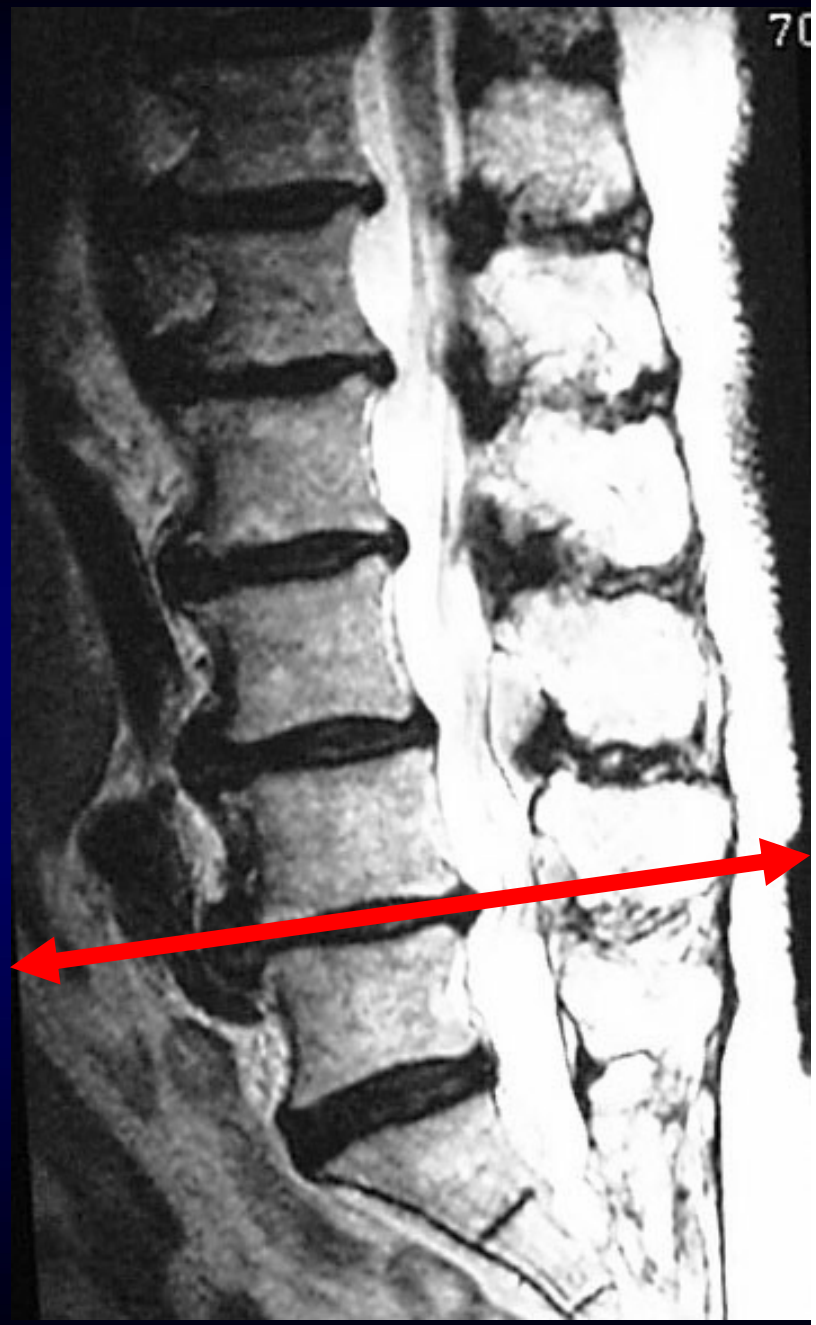
70

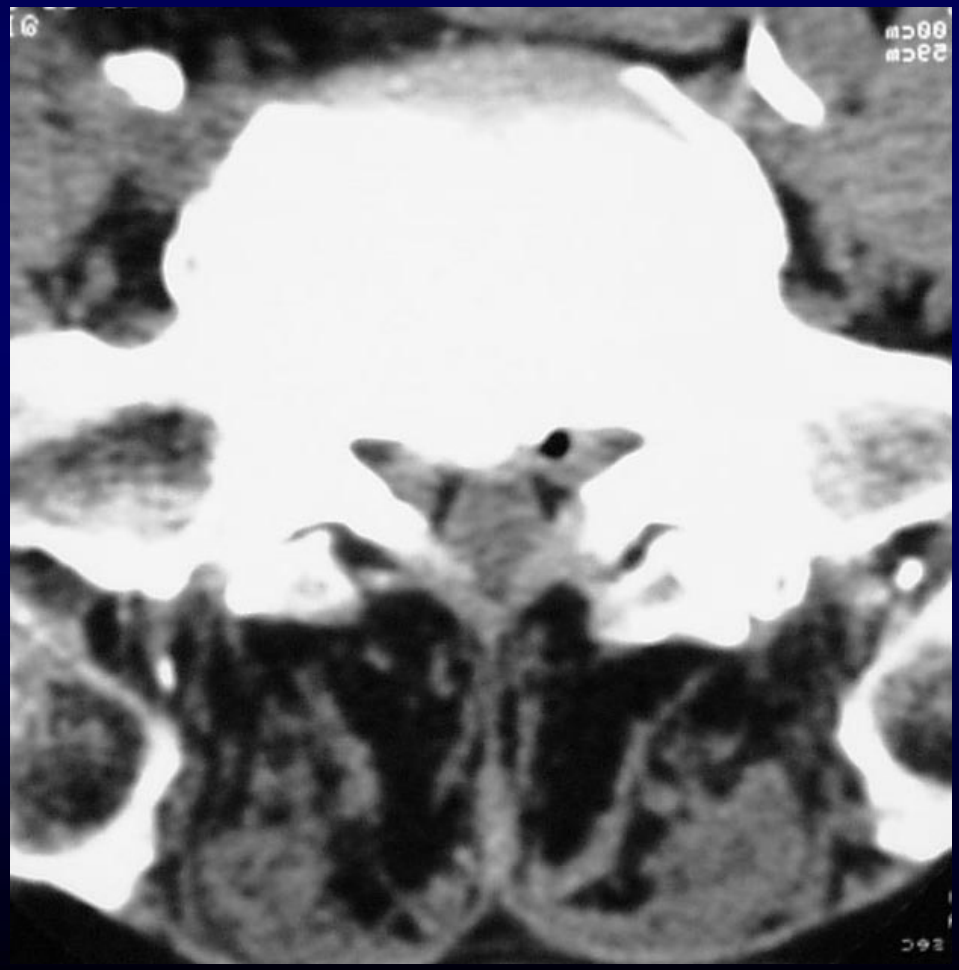

HADAR 2

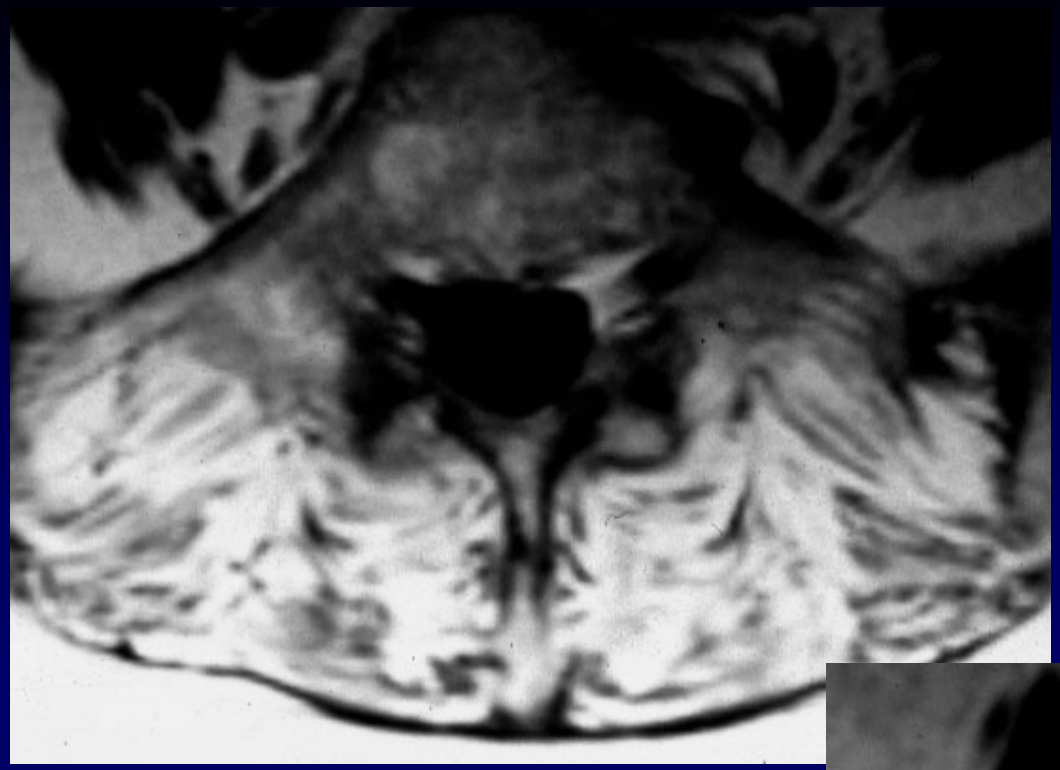

HADAR 3

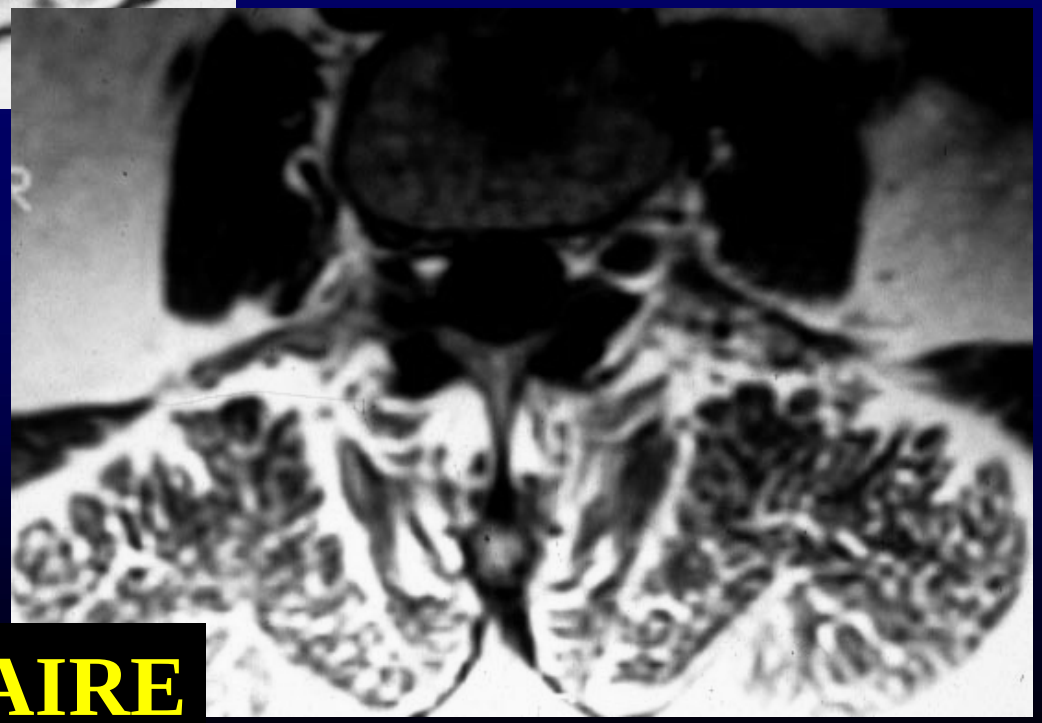

R. THORACOLOMBAIRE

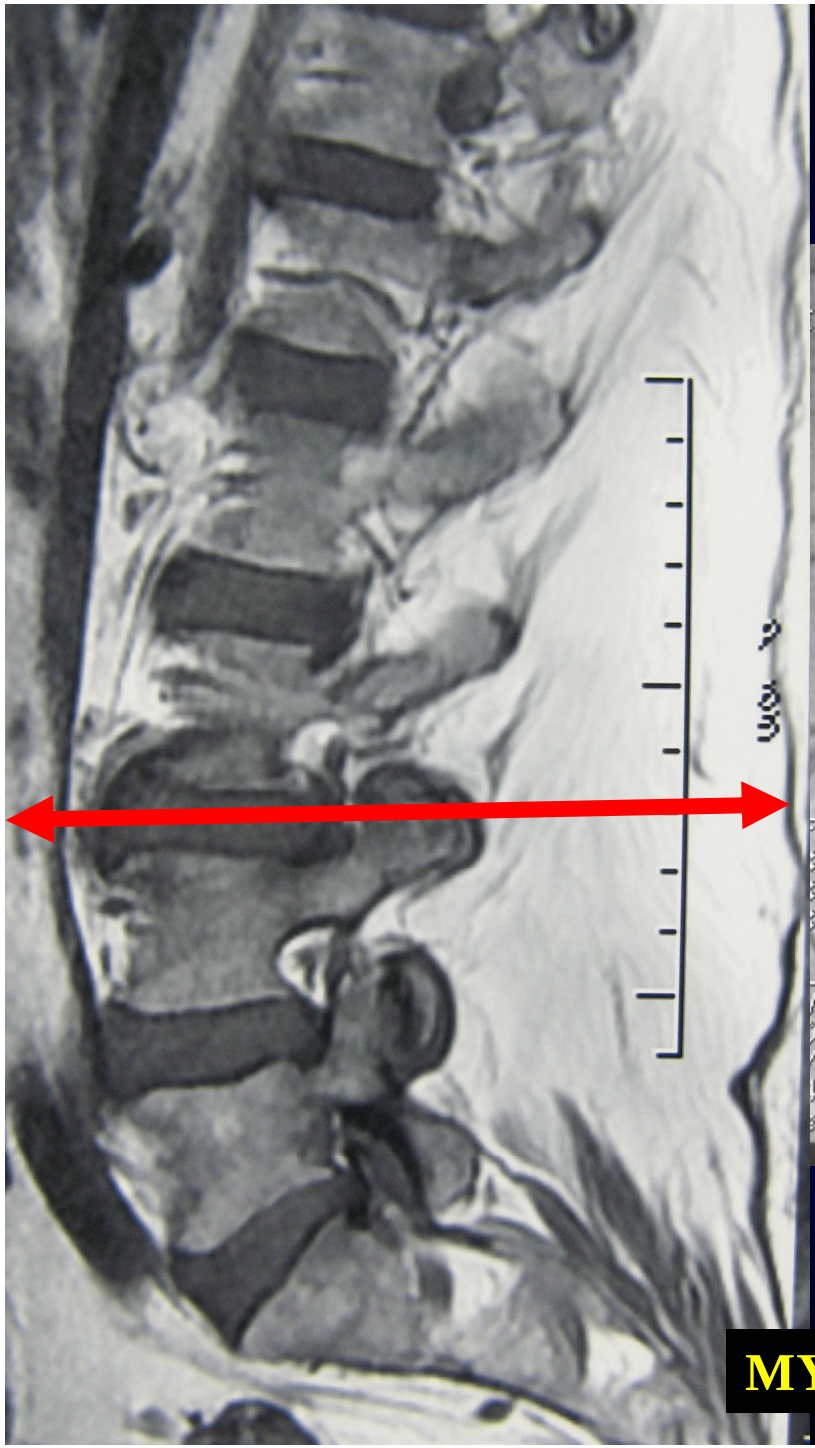

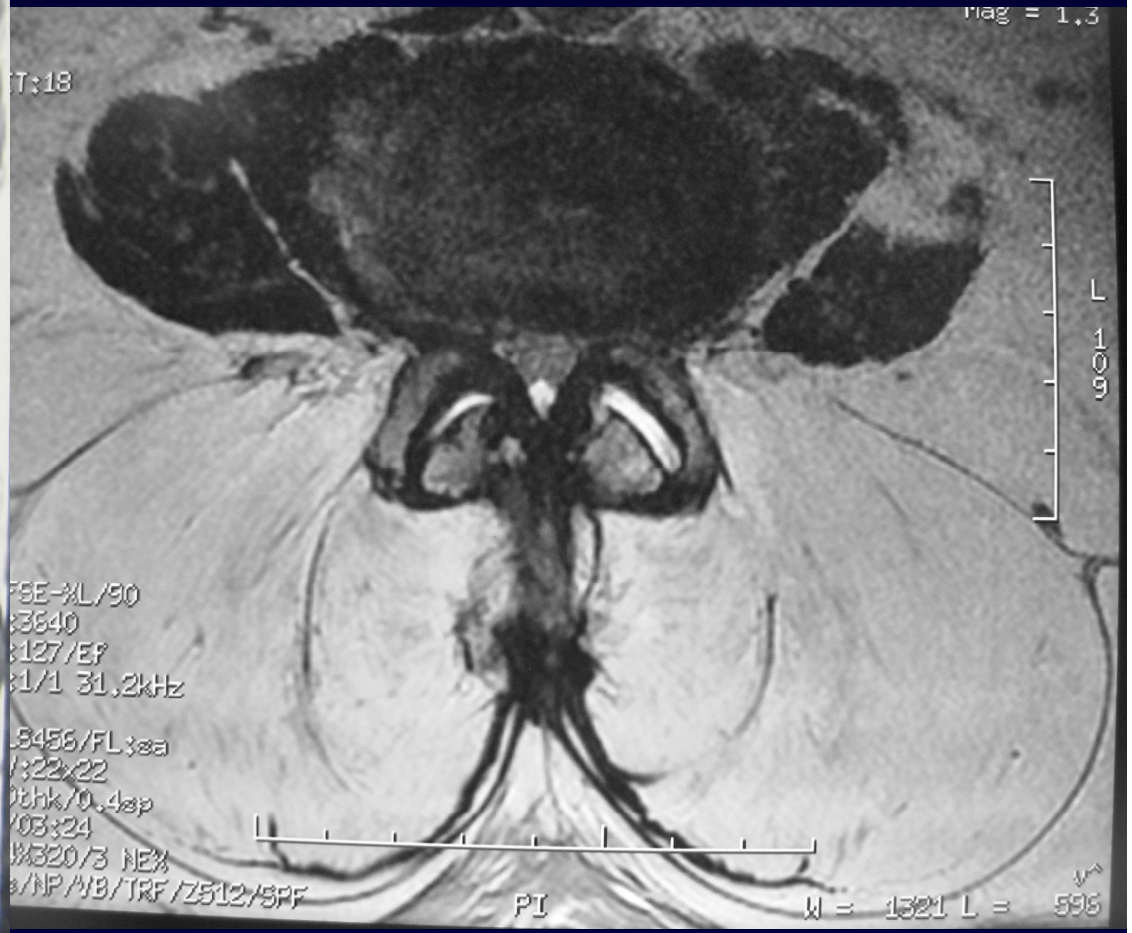

MYOPATHIE PARAVERTEBRALE PRIMITIVE

ISOCINETISME 60°/sec.

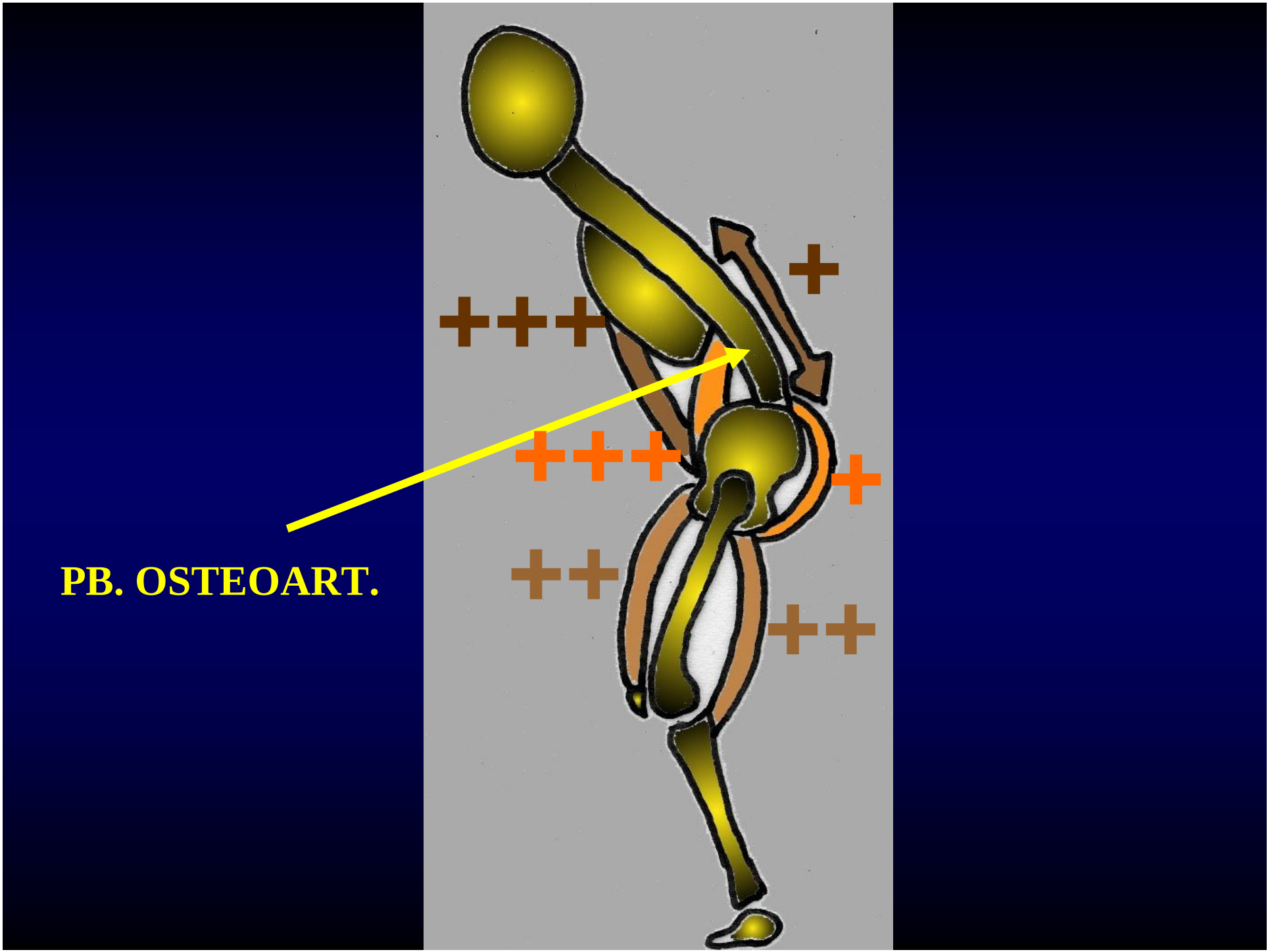
PB. OSTEOART.
+
+++
+++
+
++
++

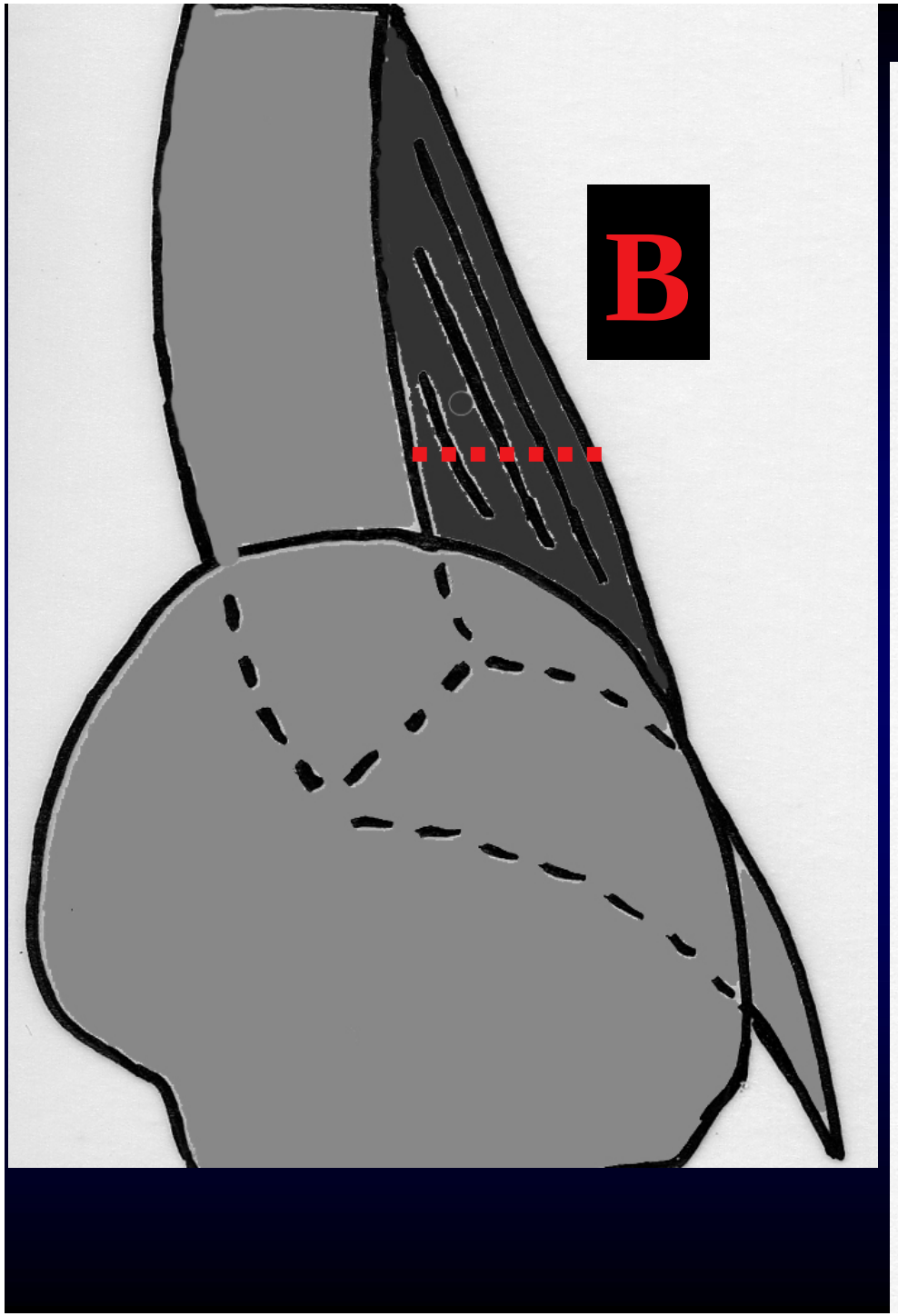
B

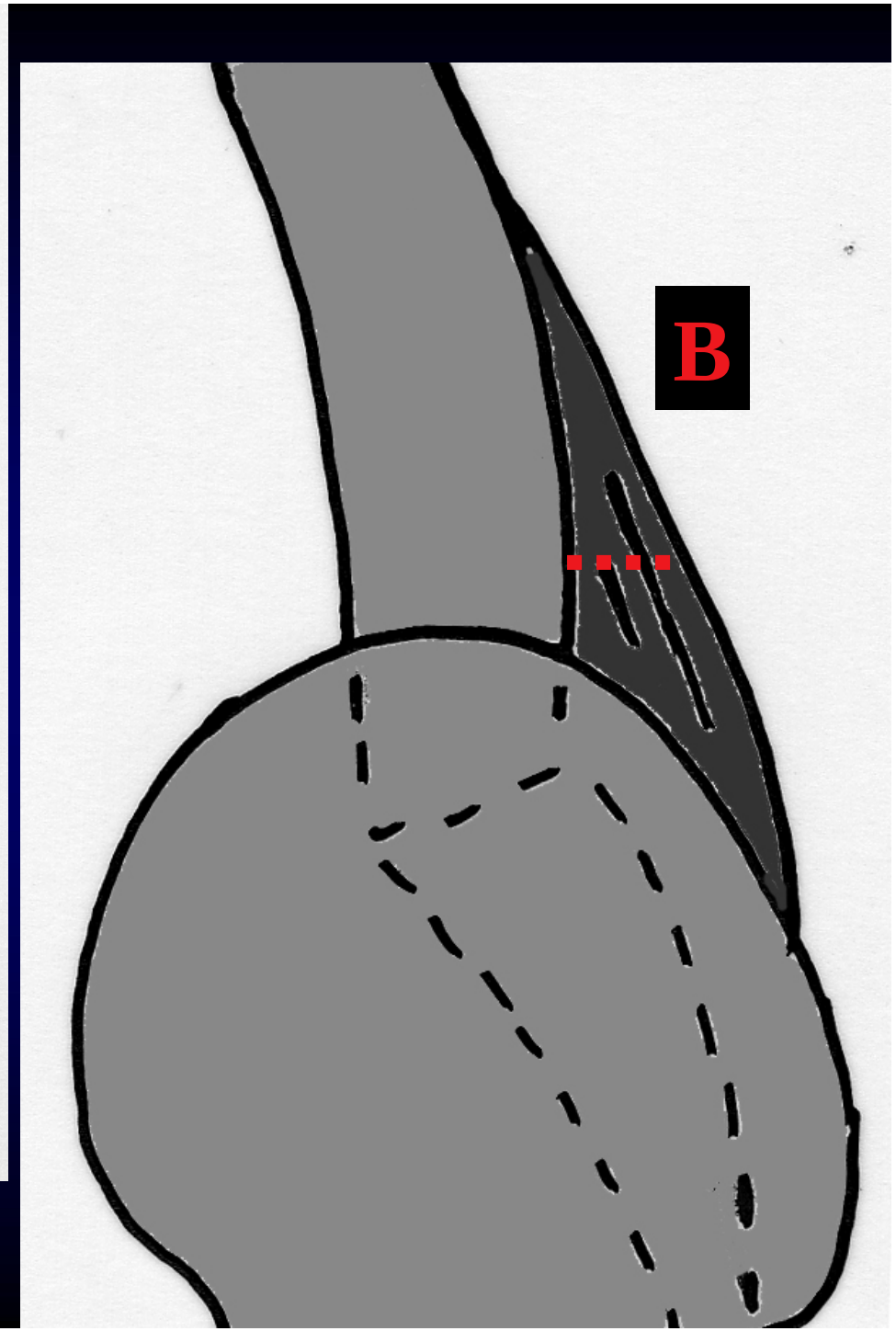
B

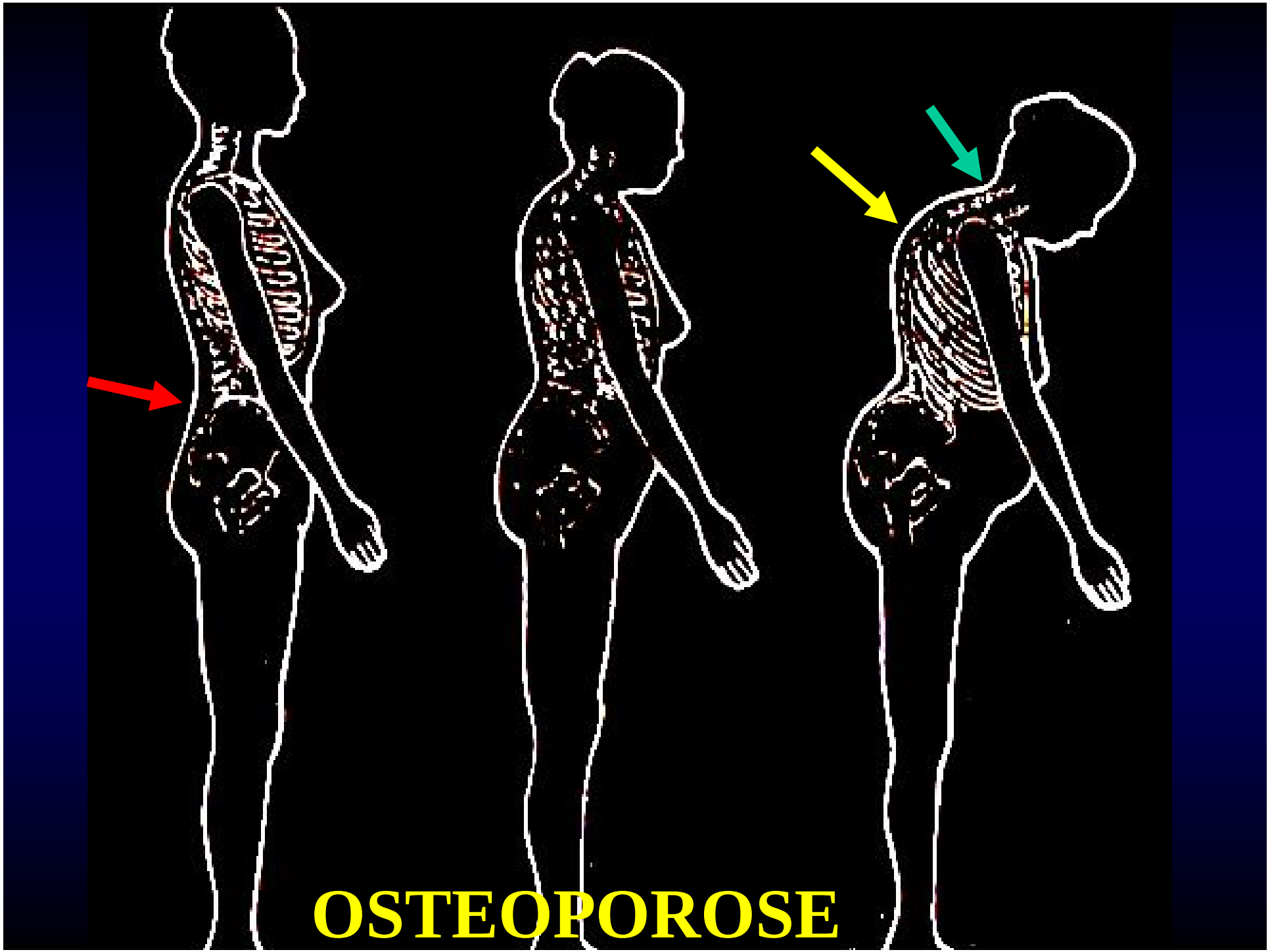
OSTEOPOROSE

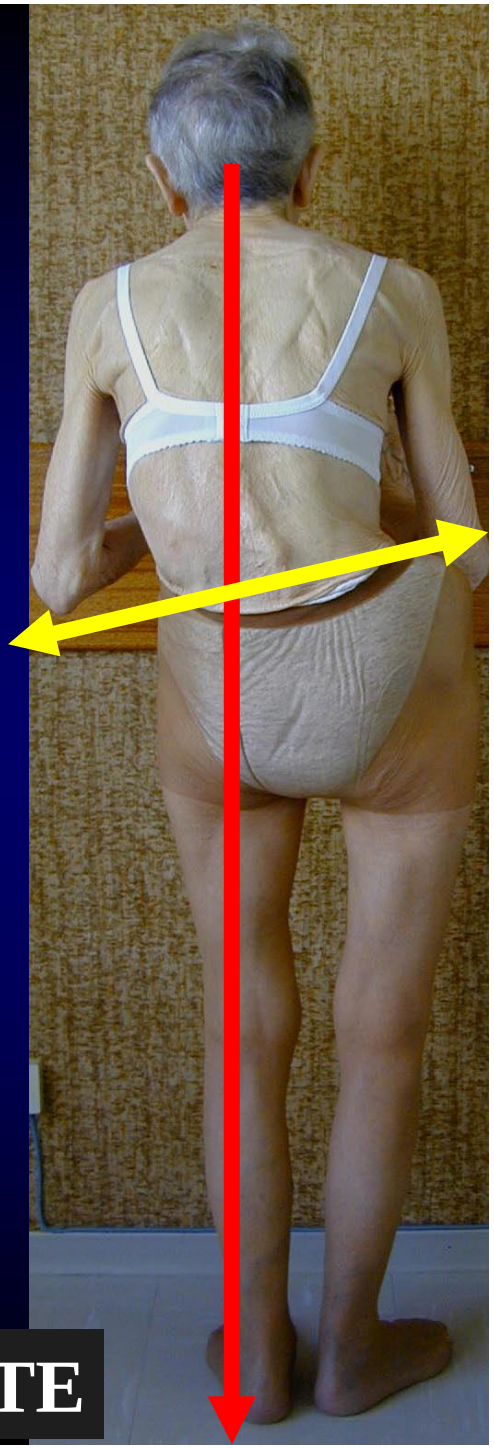

SCOLIOSE PREEXISTANTE

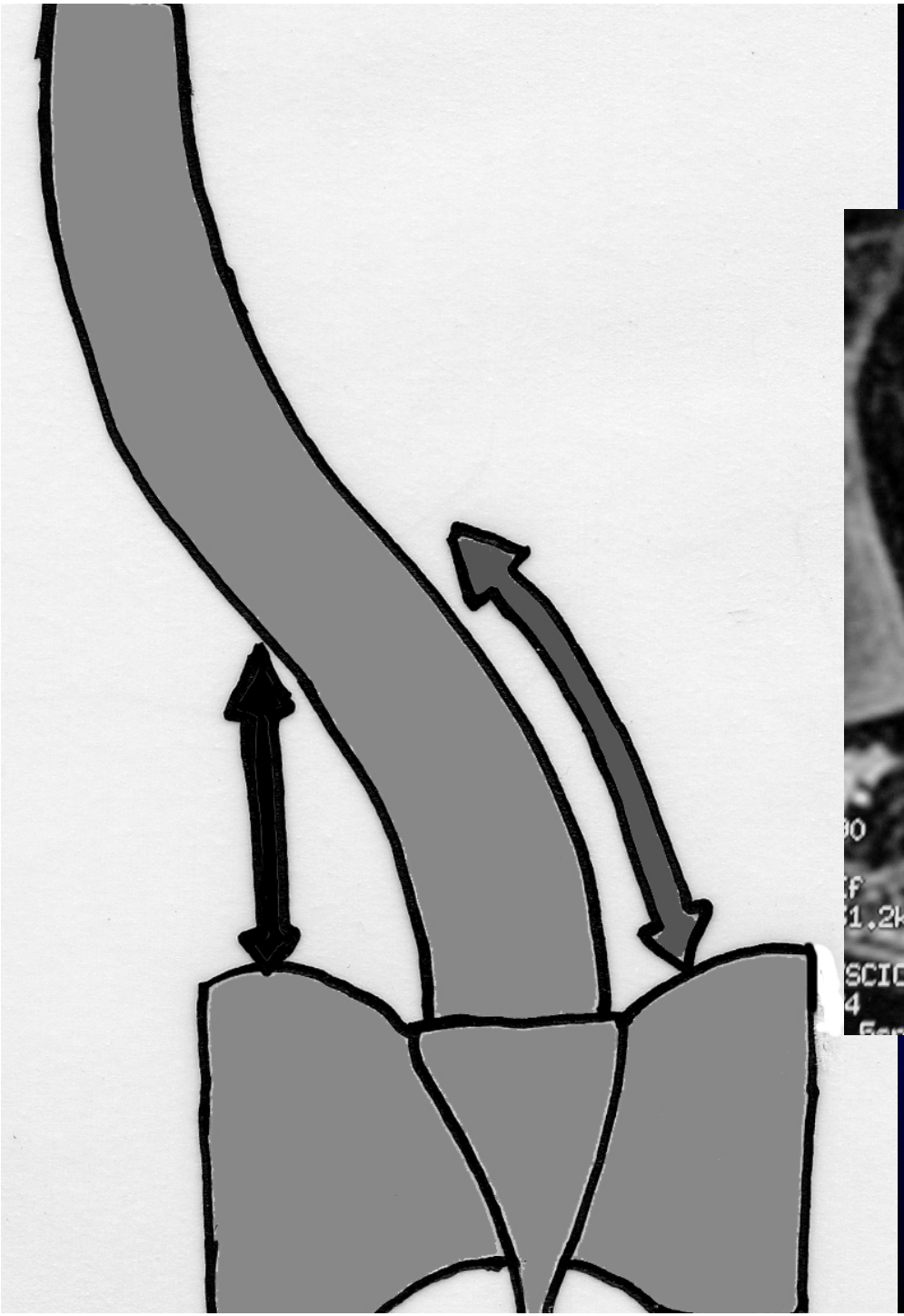

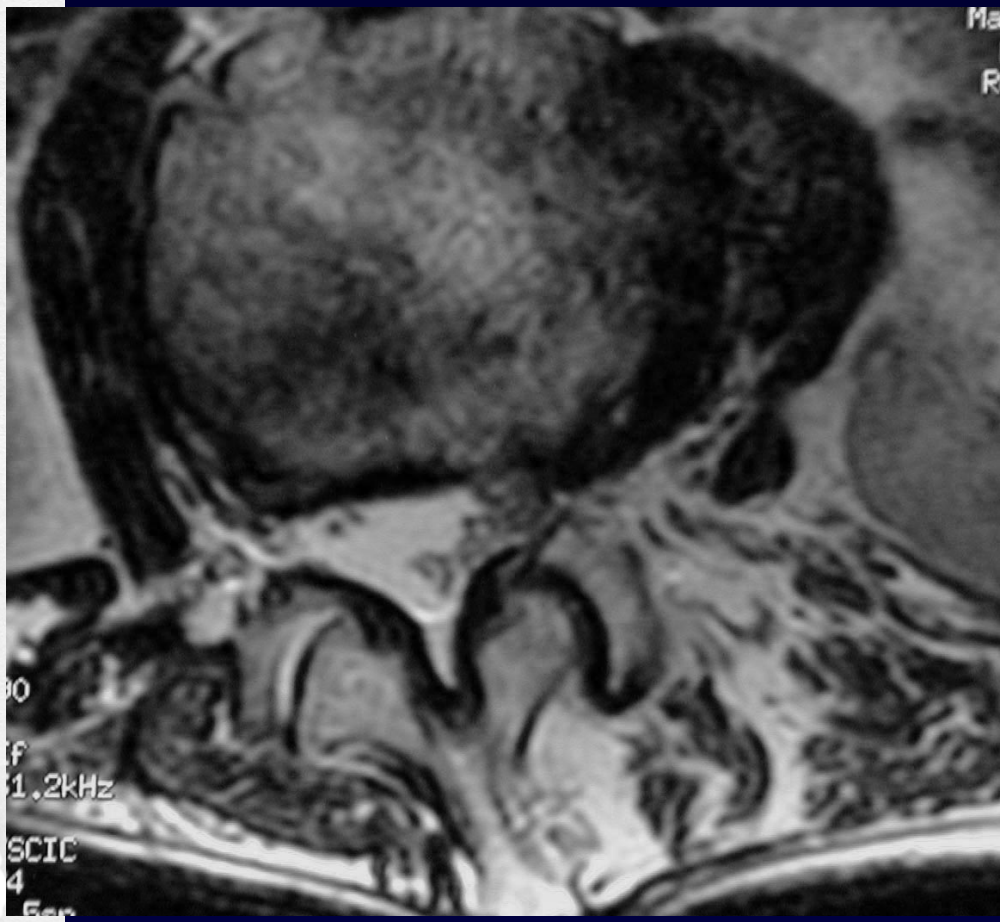
1.2kHz
SCIC

FRACTURE du RACHIS

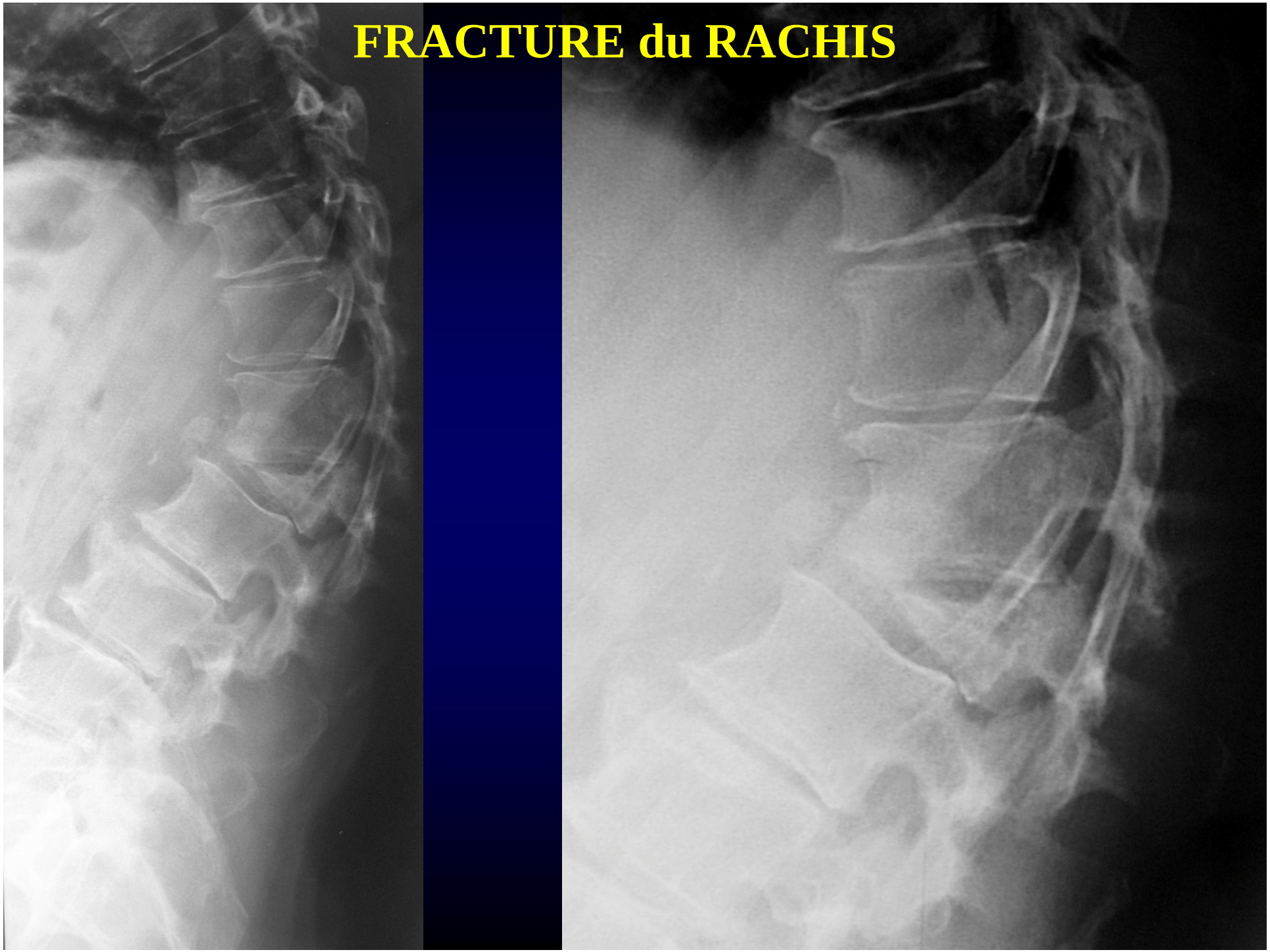

HAUT

SPONDYLODISCITE

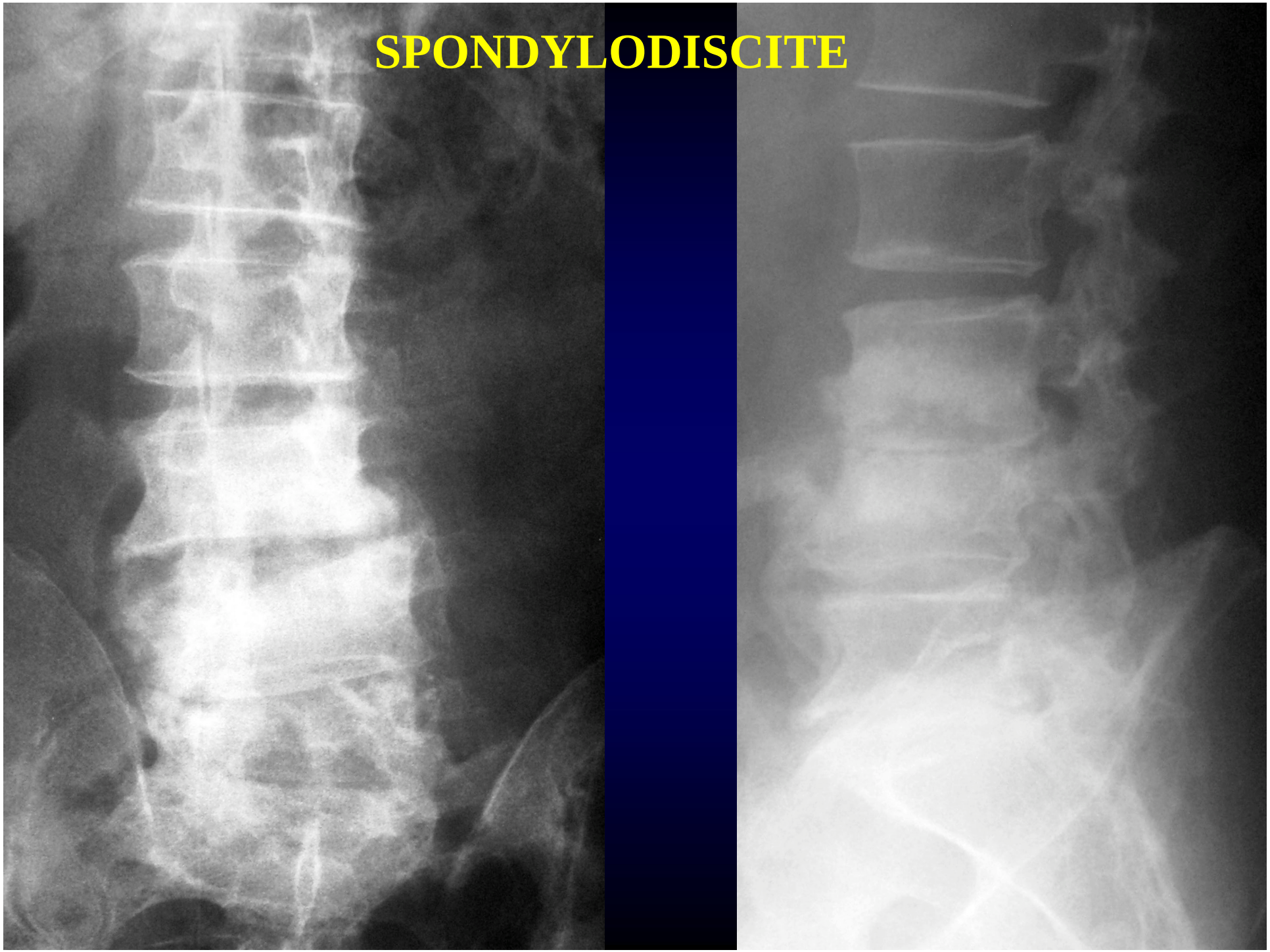

(Adulte)
cm²
29.7°
19.5°
iS=49.2°

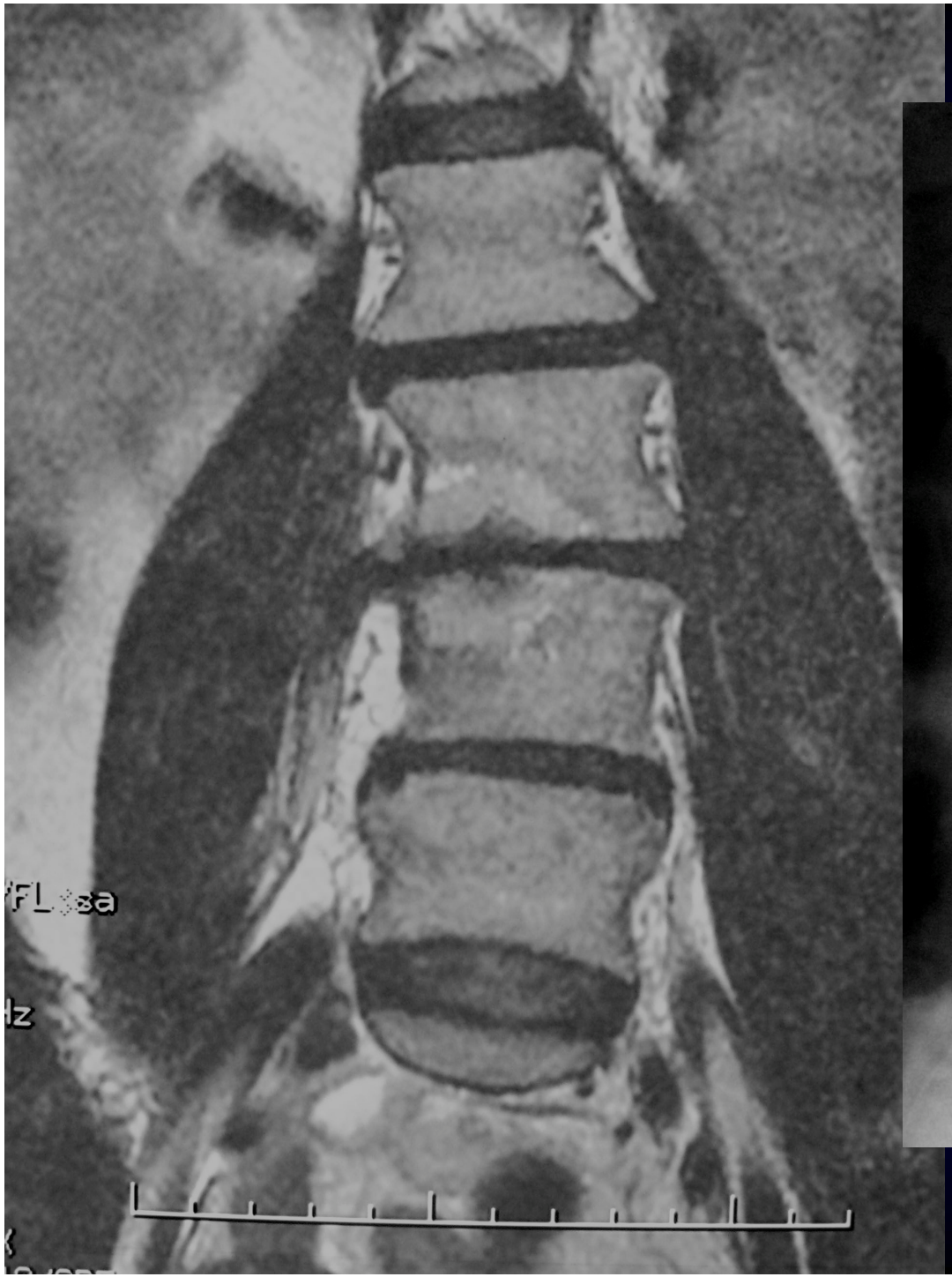

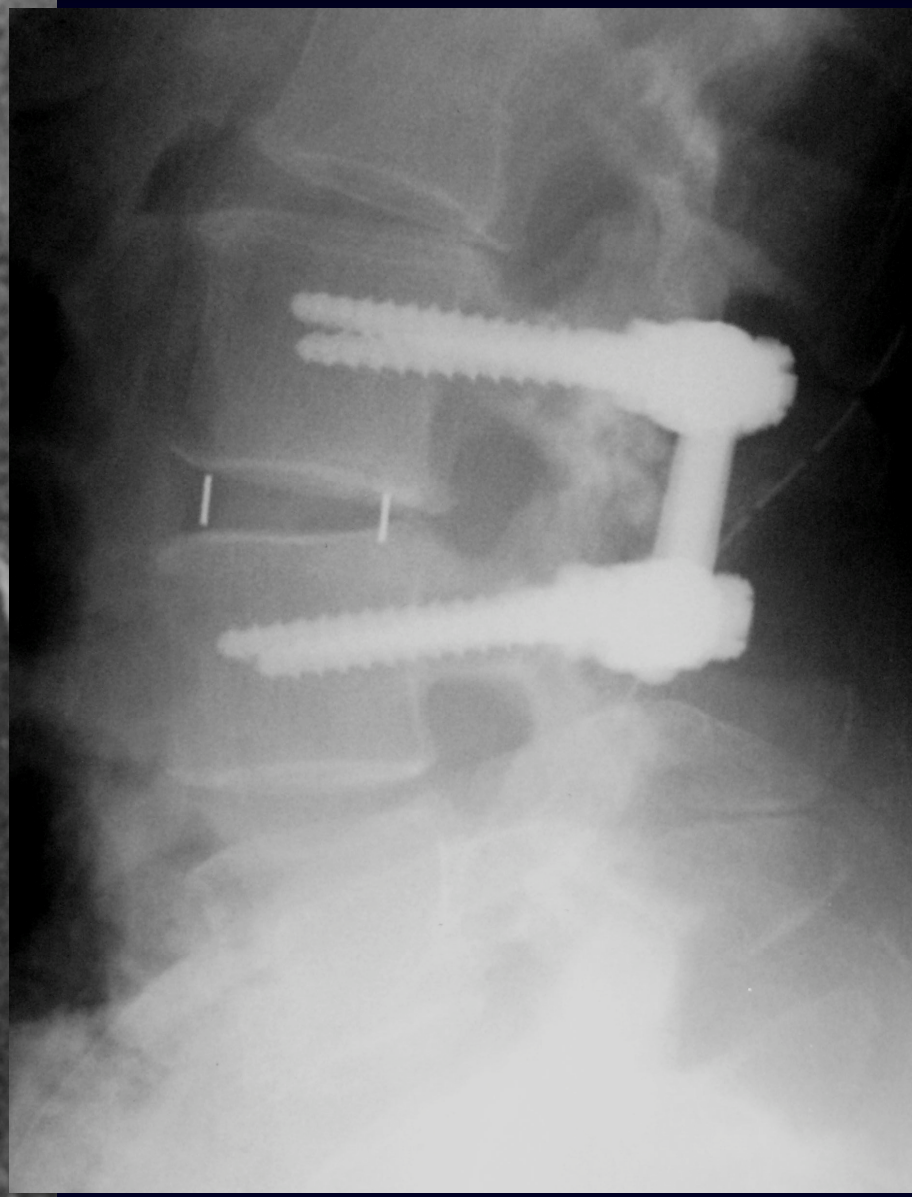

CHIRURGIE LOCALISEE

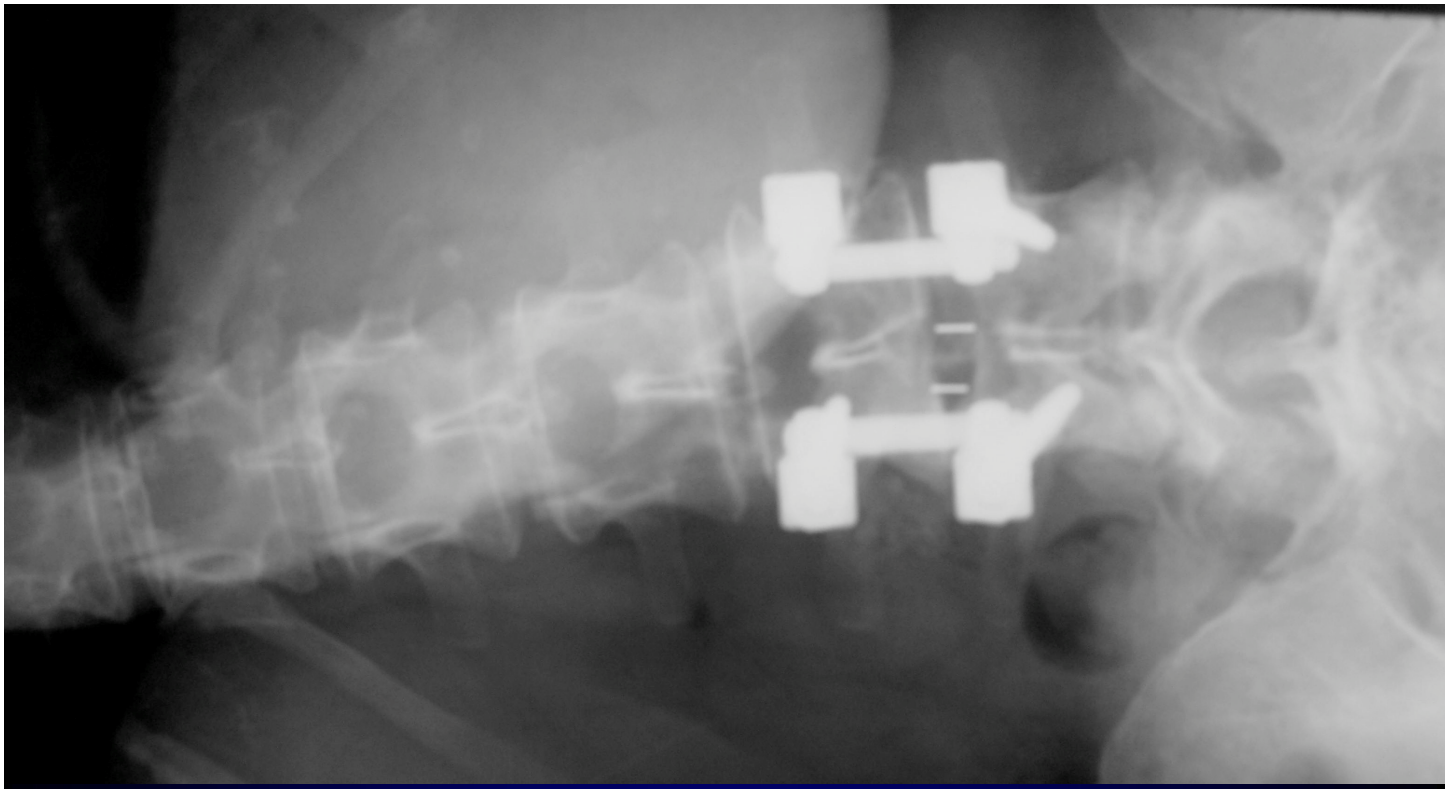

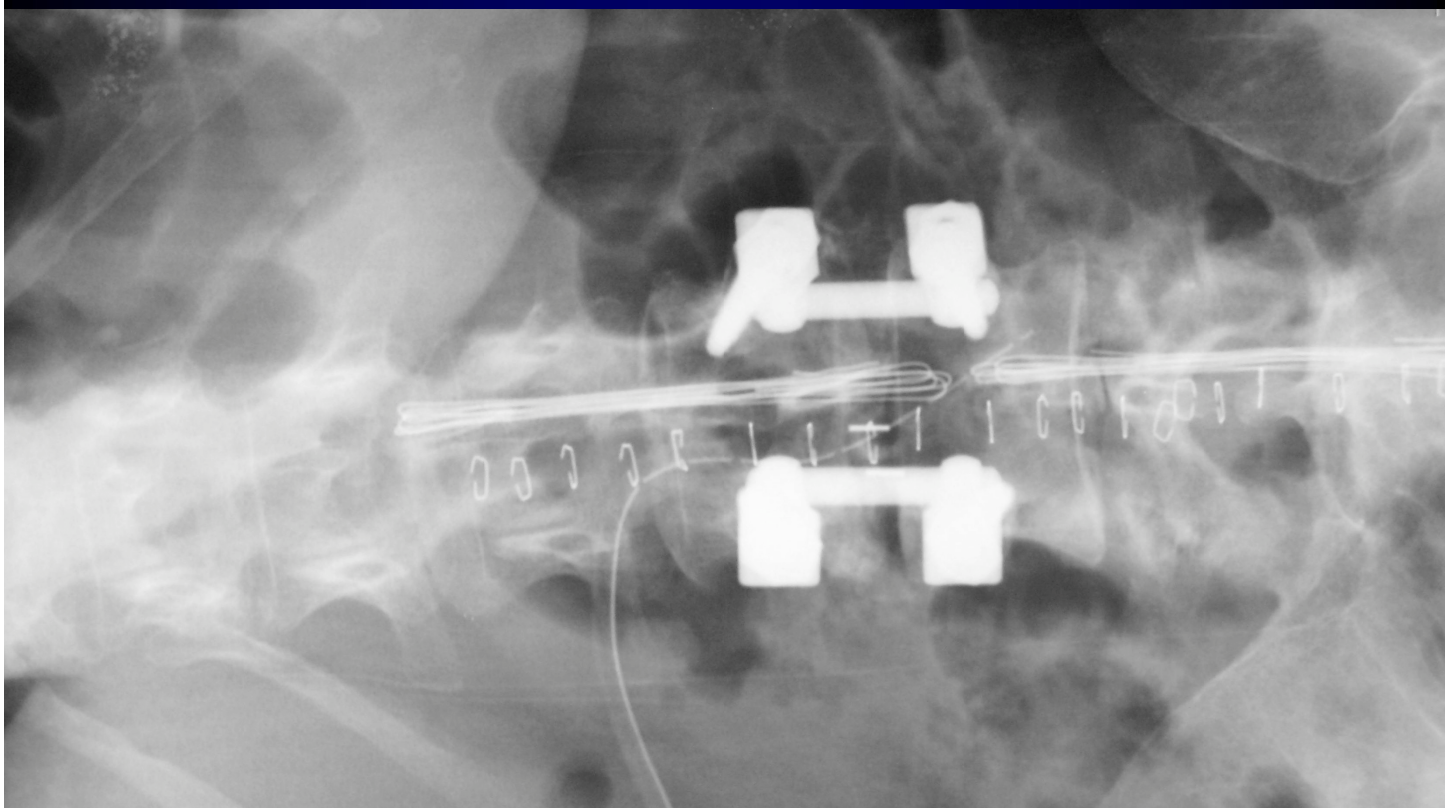

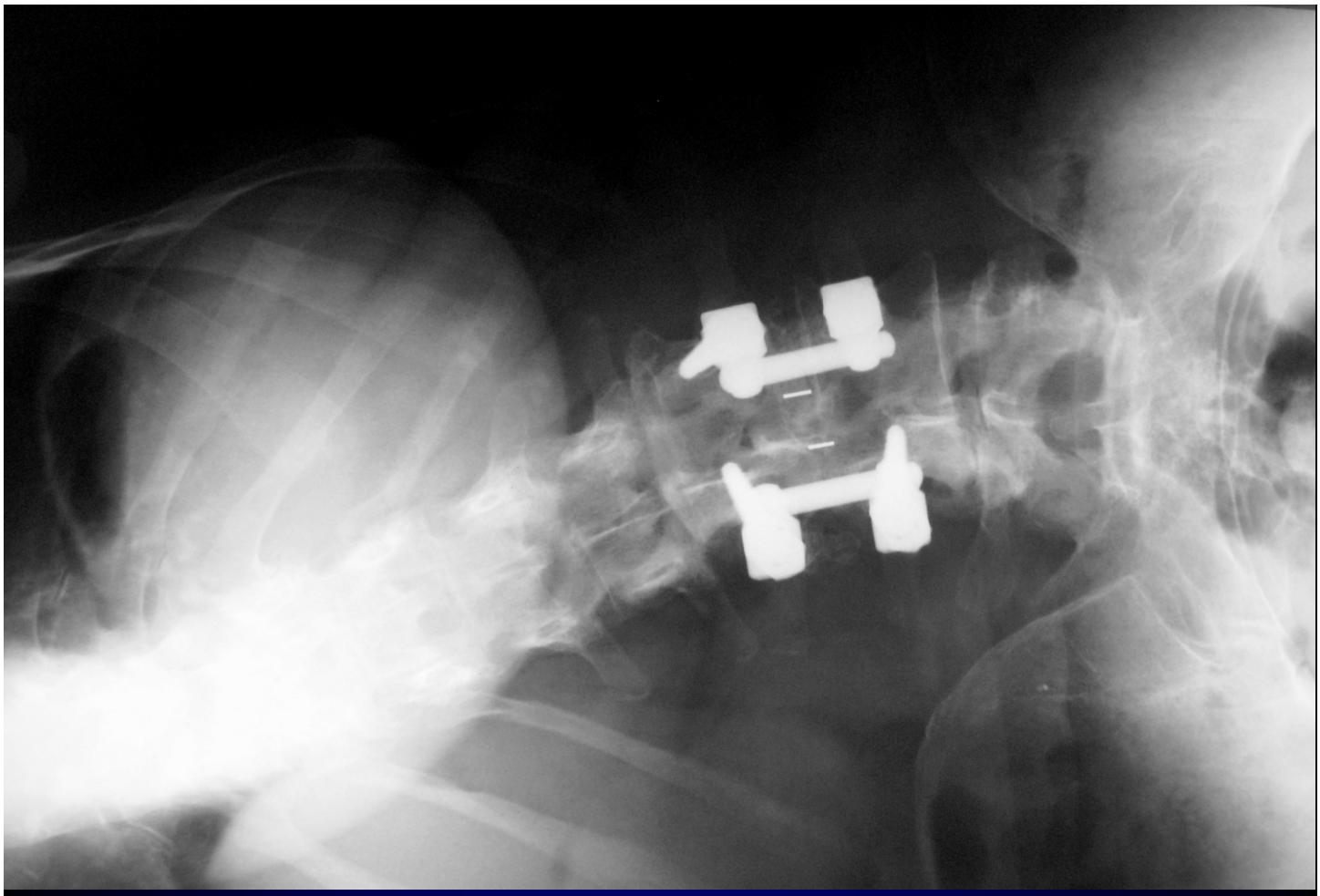

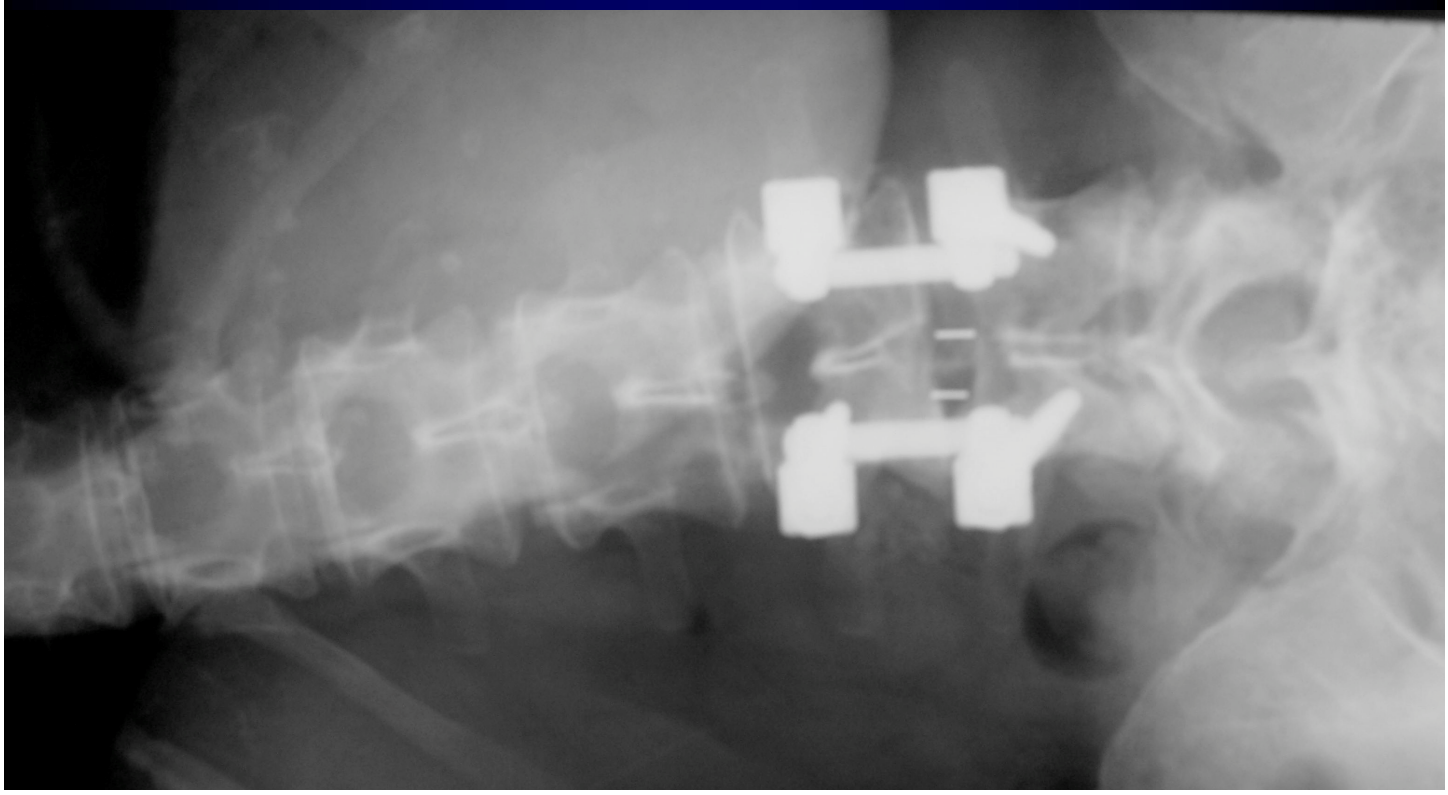

CHIRURGIE PLUS ETENDUE

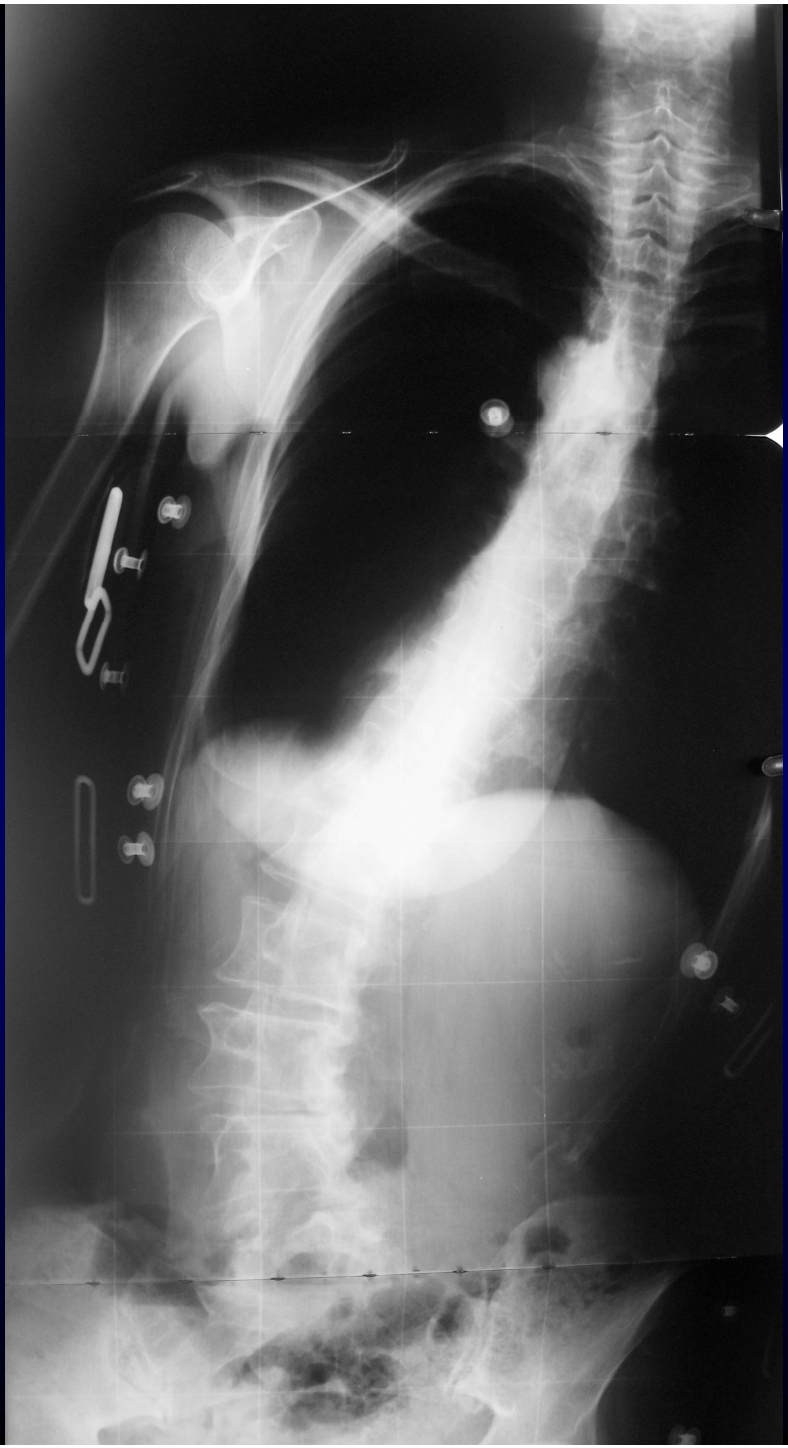

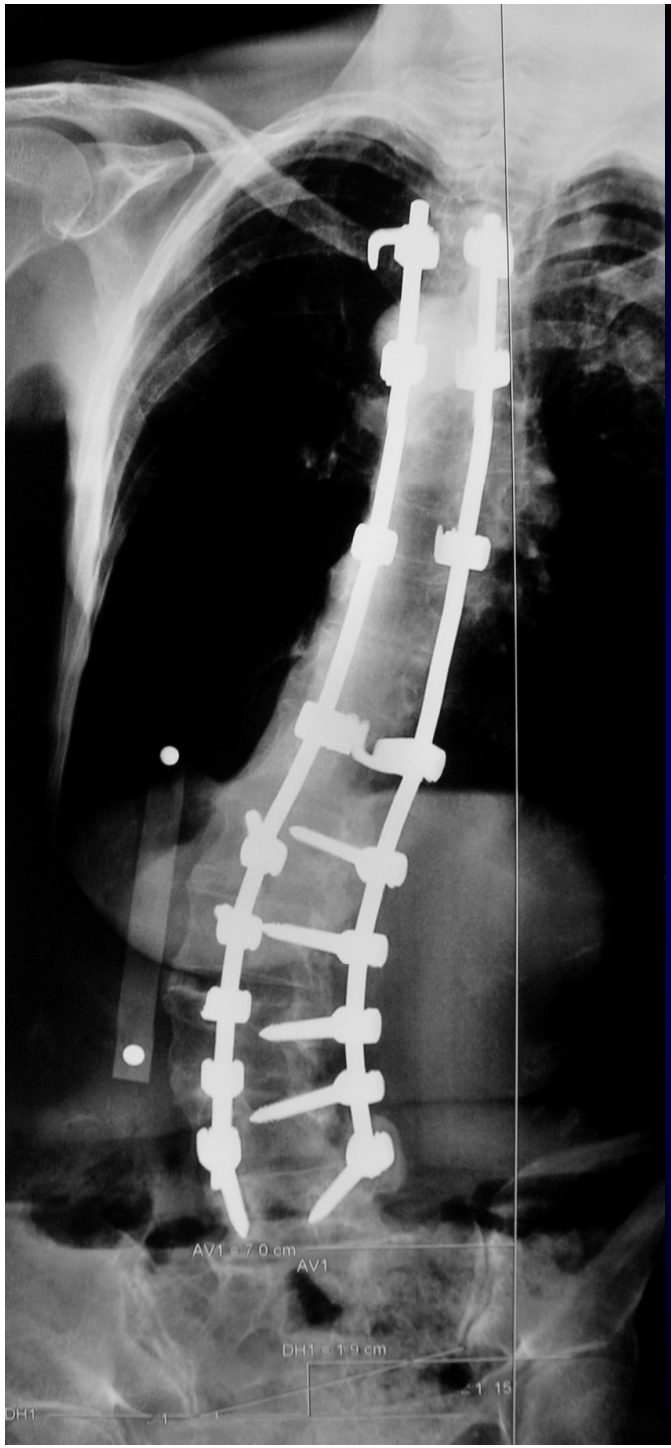
AV1 = 7.0 cm
AV1
DH1 = 1.9 cm
1.15
DH1

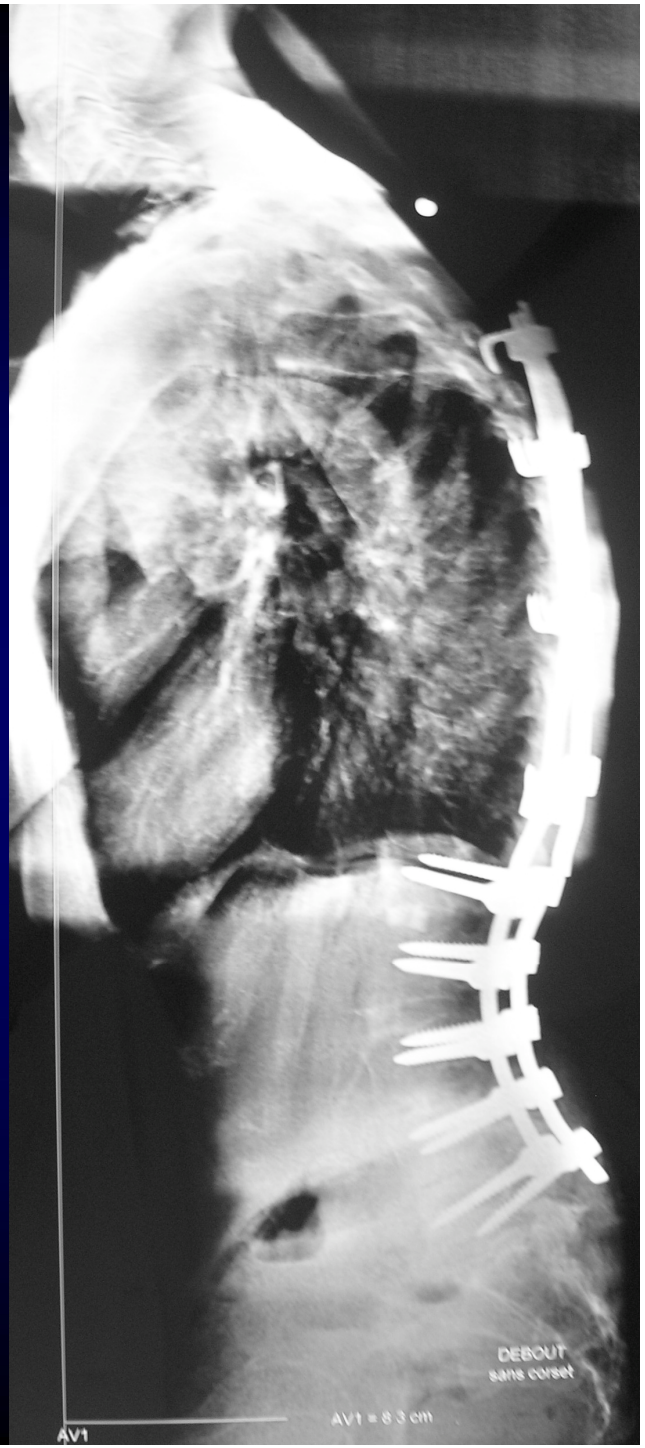
DEBOUT
sans corset
AV1 = 8.3 cm
AV1

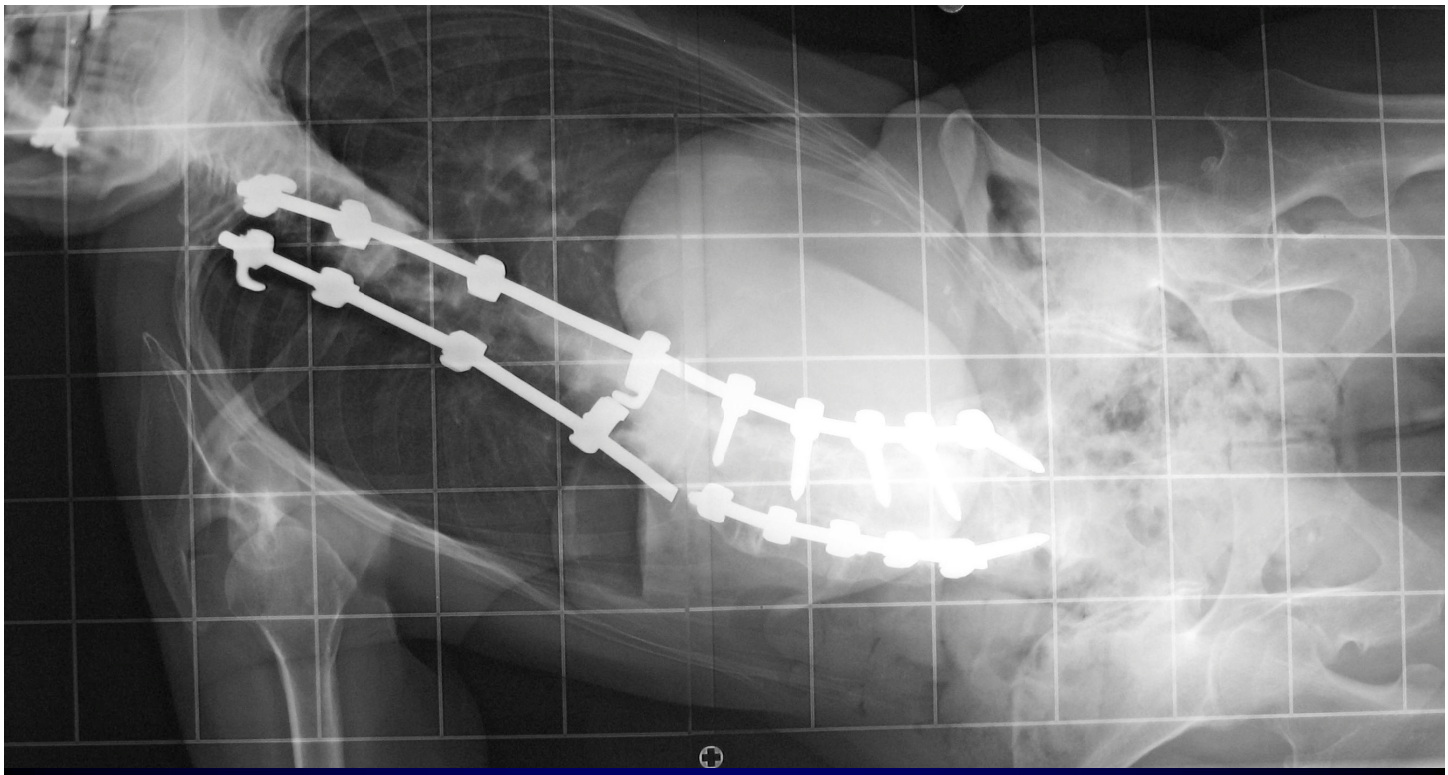

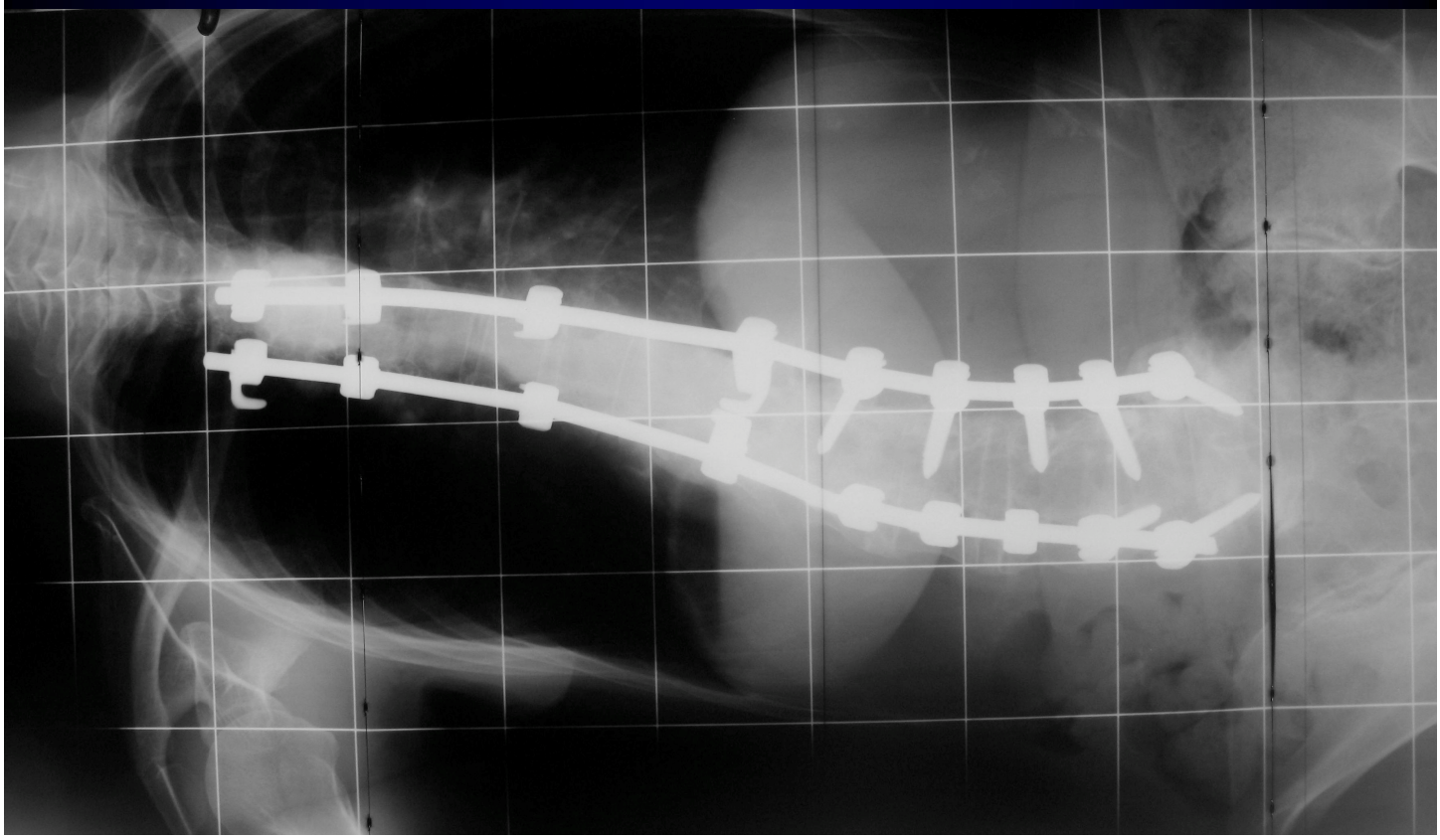

TRAITEMENT

- MEDICAL (Dopamine)

- REEDUCATION
- TRAITEMENT ORTHOPEDIQUE

- TOXINE BOTULINIQUE (Djaldetti , J Neurol. , 2006)

- STIMULATION SOUS THALAMIQUE , PALLIDALE

- CHIRURGIE RACHIDIENNE (Babat , Spine , 2004)

TRAITEMENT ORTHOPEDIQUE

STIMULATION PALLIDALE

J Neurosurg 103:1081–1083, 2005

Camptocormia in a patient with Parkinson disease: beneficial effects of pallidal deep brain stimulation

Case report

FEDERICO MICHELI, M.D., PH.D., MARÍA G. CERSÓSIMO, M.D., AND FABIAN PIEDIMONTE, M.D.

Parkinson's Disease and Movement Disorders Unit, Hospital de Clínicas "José de San Martín," Buenos Aires, Argentina

QuickTime™ et un
décompresseur H.264
sont requis pour visionner cette image.

DYSTONIE GENERALISEE (Pr A. ROUGIER)

CHIRURGIE RACHIDIENNE

- **INSTRUMENTATION POSTERIEURE LONGUE**
- **ETAYAGE de la COLONNE ANTERIEURE (CAGES)**
- **EQUILIBRES CORONAL & SAGITTAL PARFAITS (HYPERCORRIGER …)**

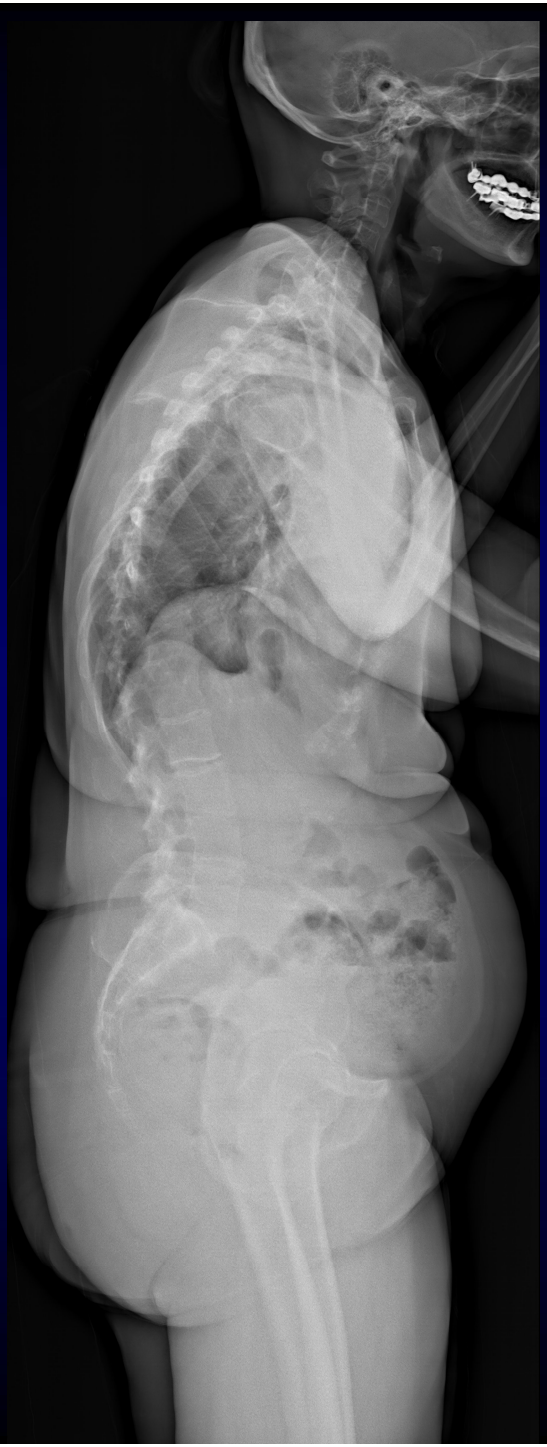

15.4°
21.9 cm

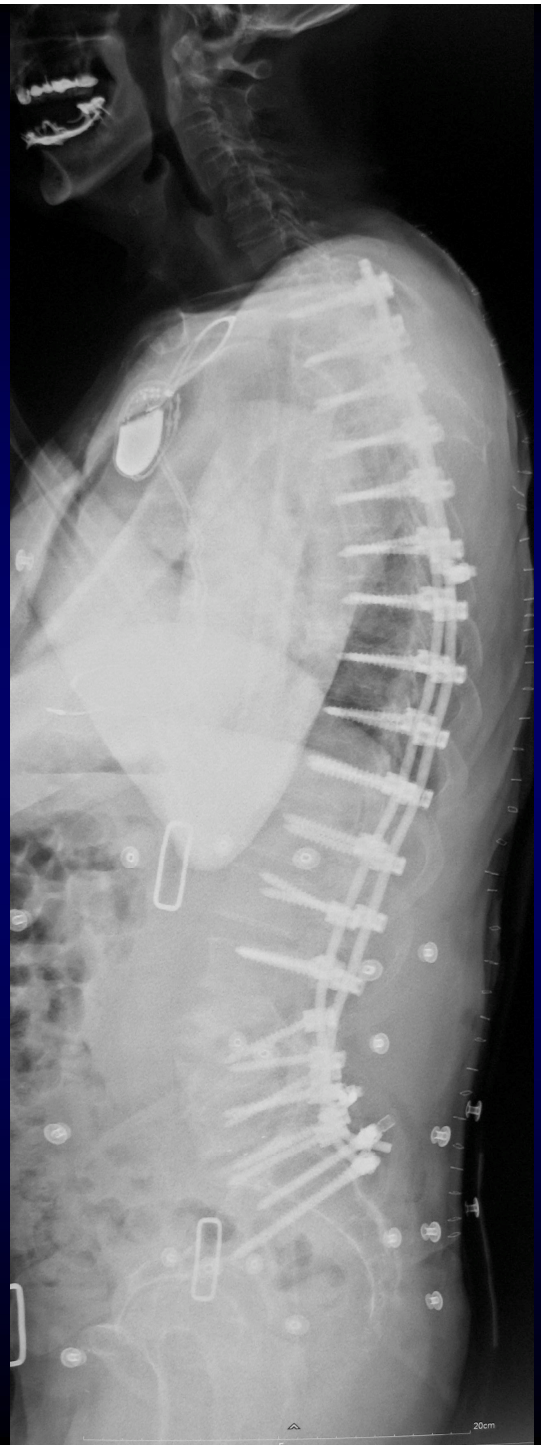
20cm

QuickTime™ et un
décompresseur Animation JPEG OpenDML
sont requis pour visionner cette image.

QuickTime™ et un
décompresseur Animation JPEG OpenDML
sont requis pour visionner cette image.

CONCLUSIONS

- TABLEAUX SEVERES / DYSTONIE AXIALE
- DESEQUILIBRE MIXTE
- CAUSE AGGRAVANTE FREQUENTE
- TRAITEMENT DIFFICILE & CONTROVERSE