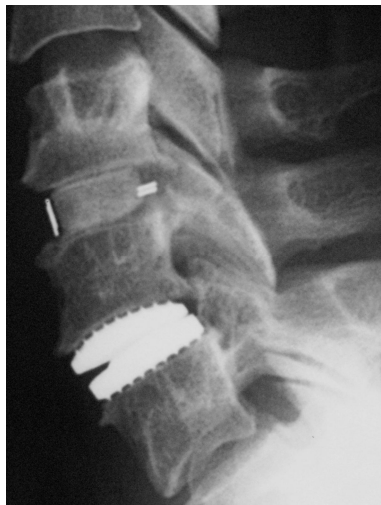

# **HYBRID RECONSTRUCTION after ANTERIOR CERVICAL DECOMPRESSION in case of D.D.D.**



**JM VITAL , V POINTILLART**  
**Spinal Unit , Tripode , Bordeaux , France**

**Deuxième partie**

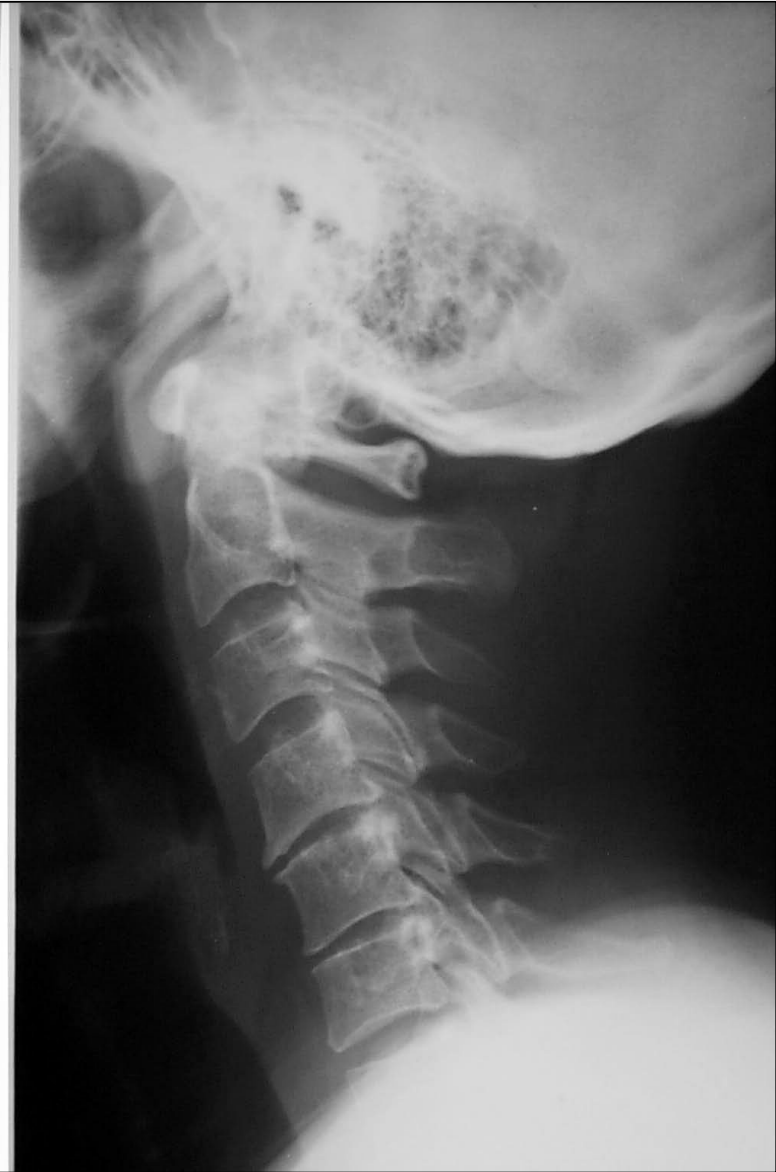
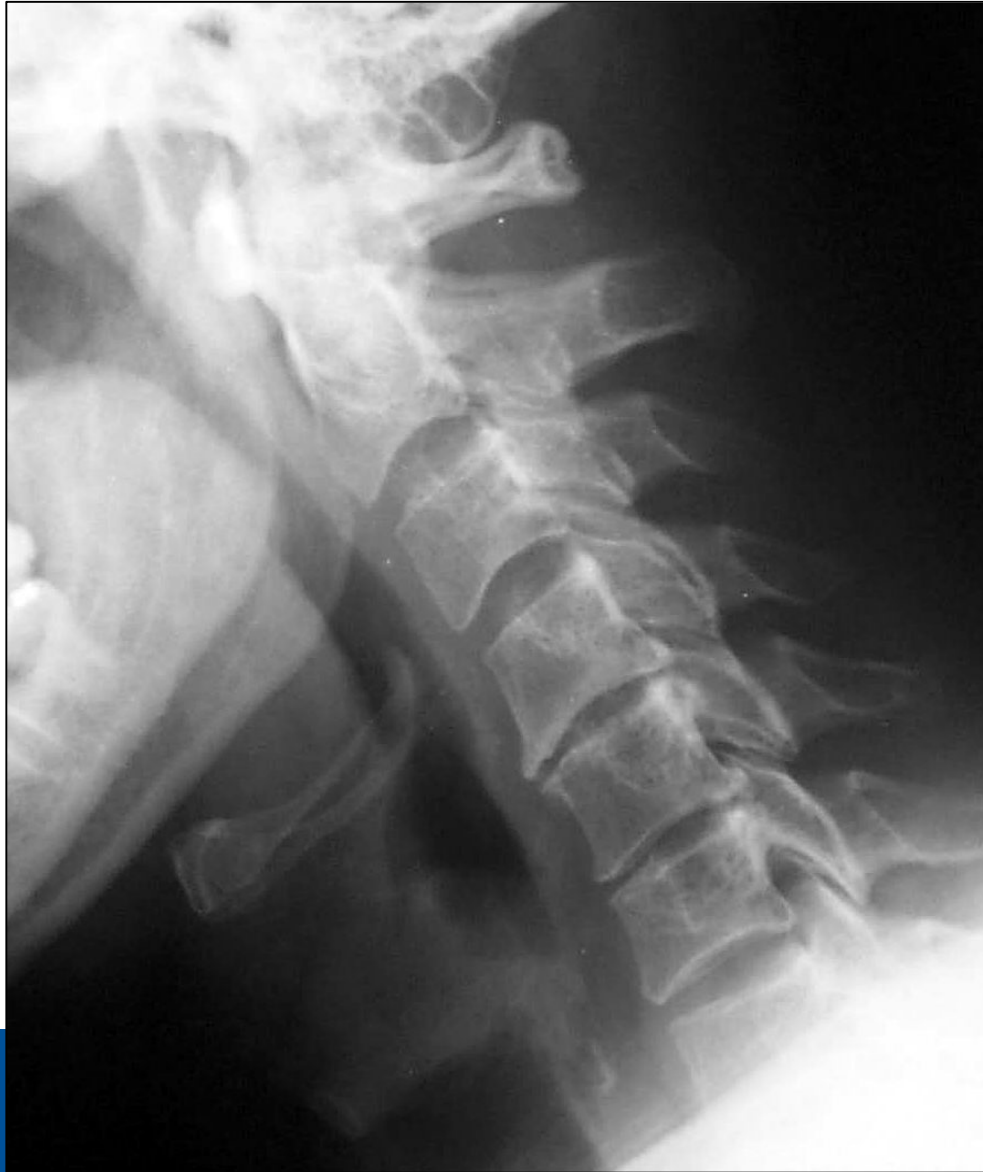
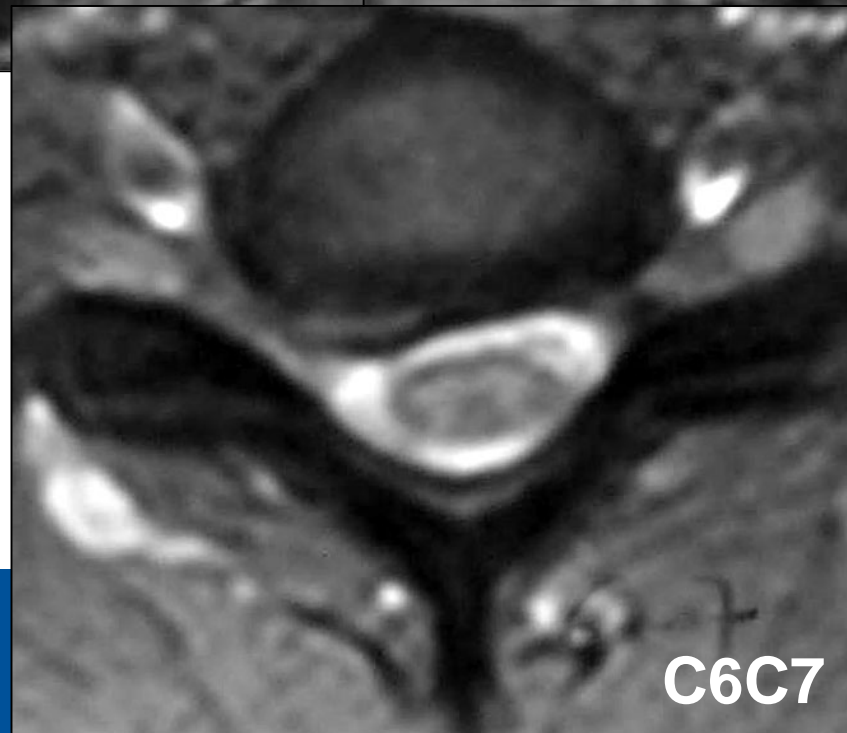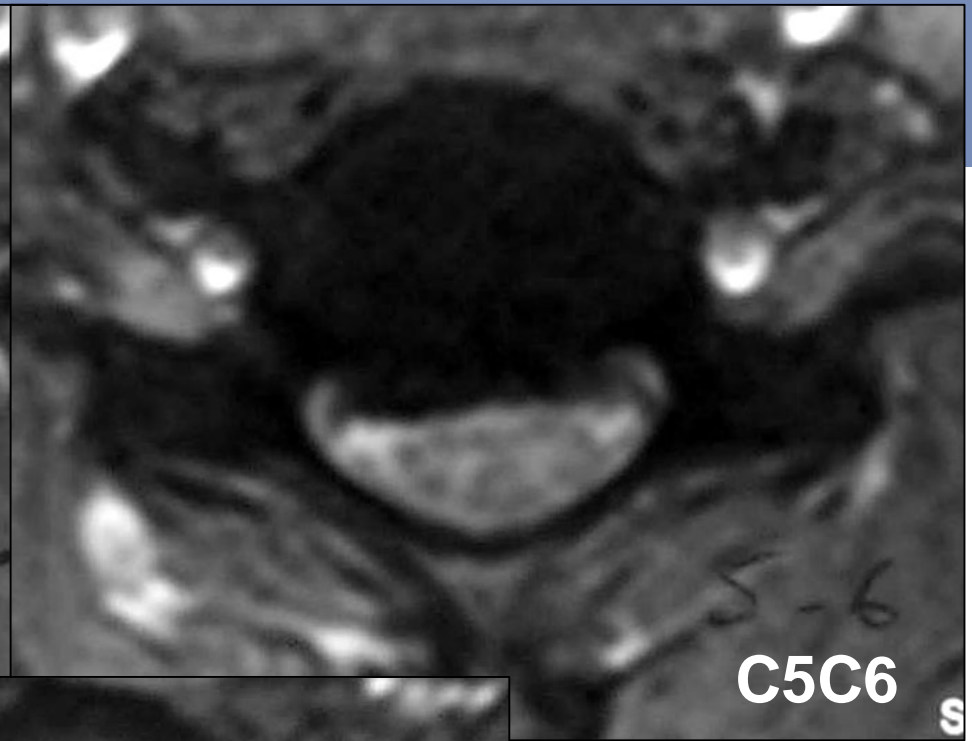
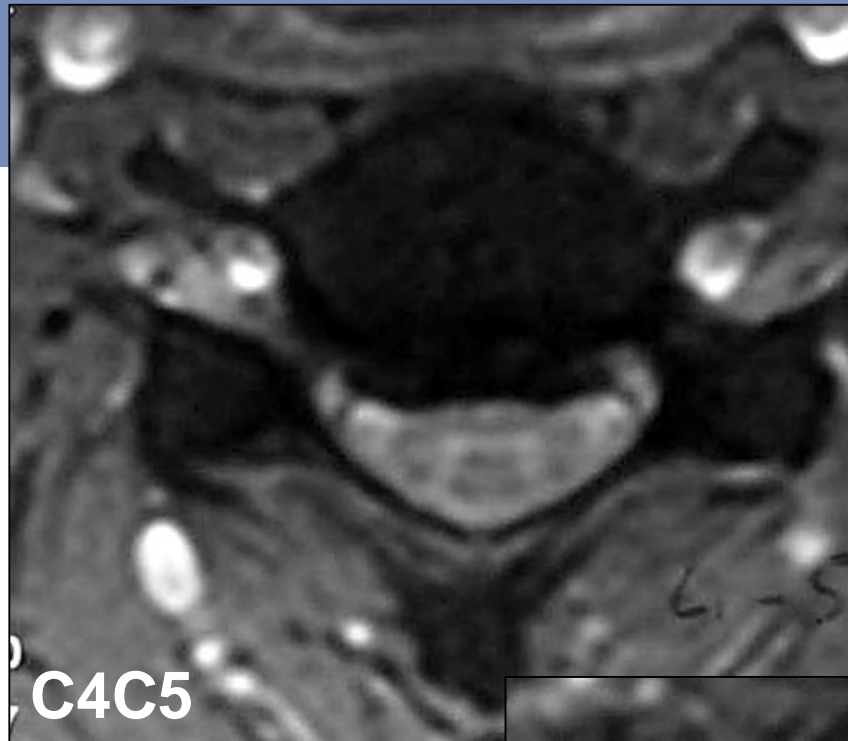
**Summer University**  
**Rome 2007**

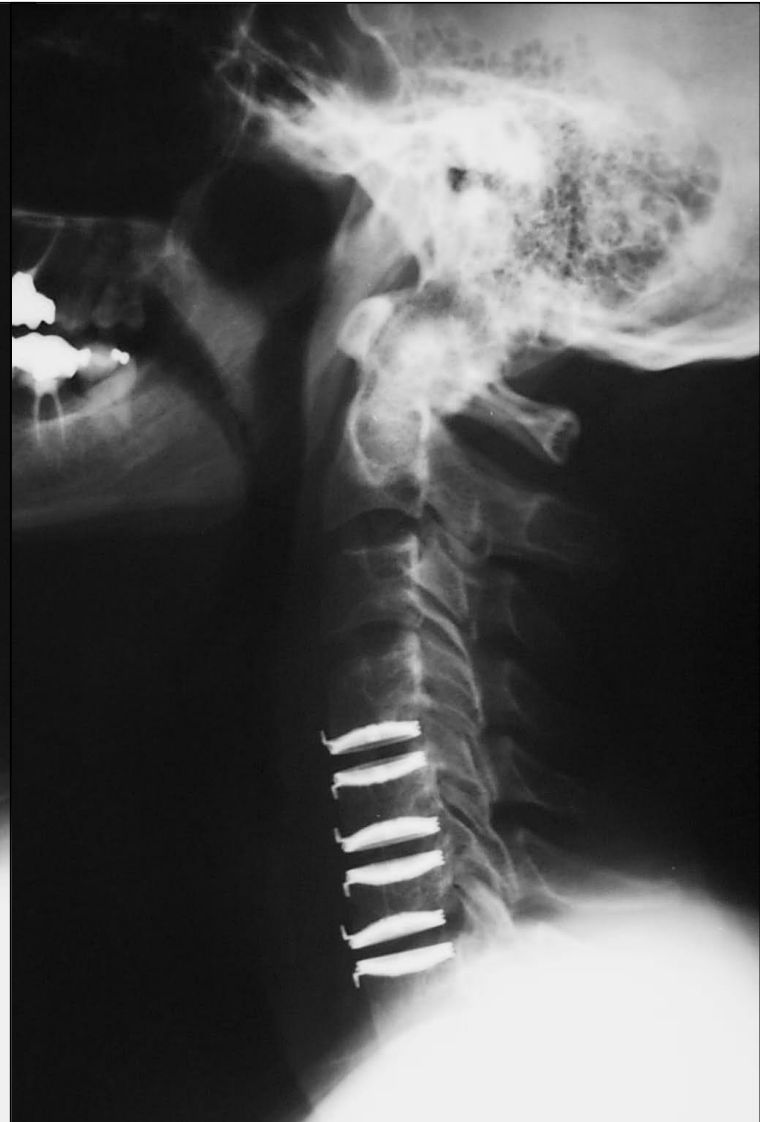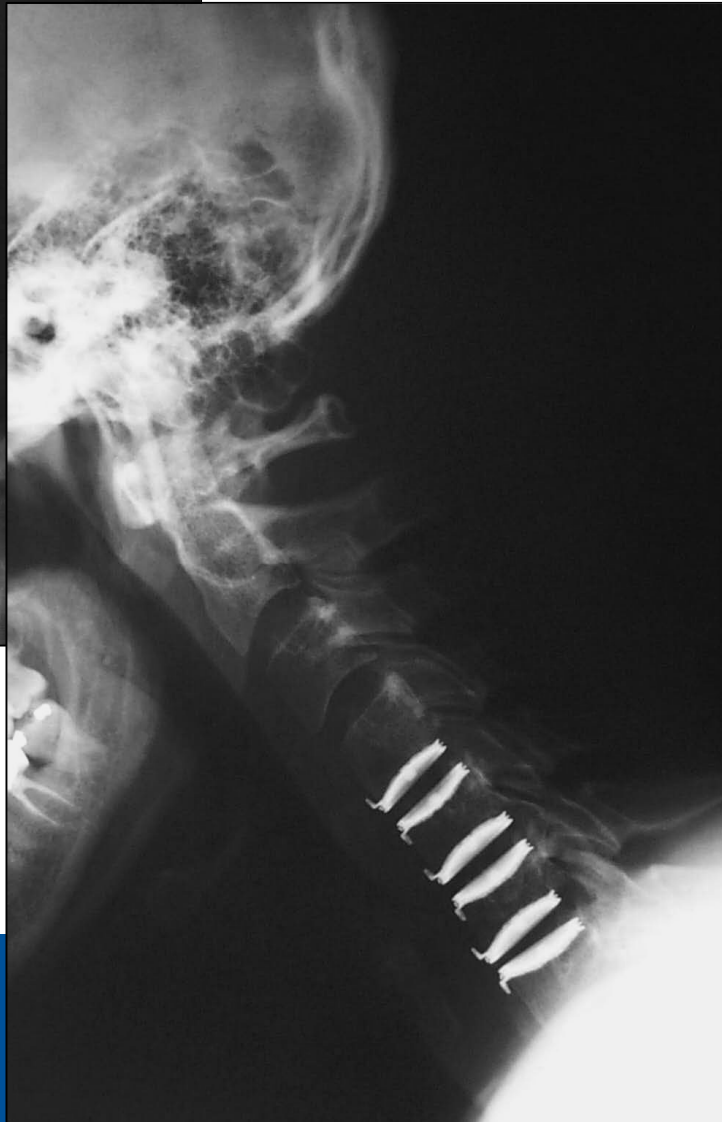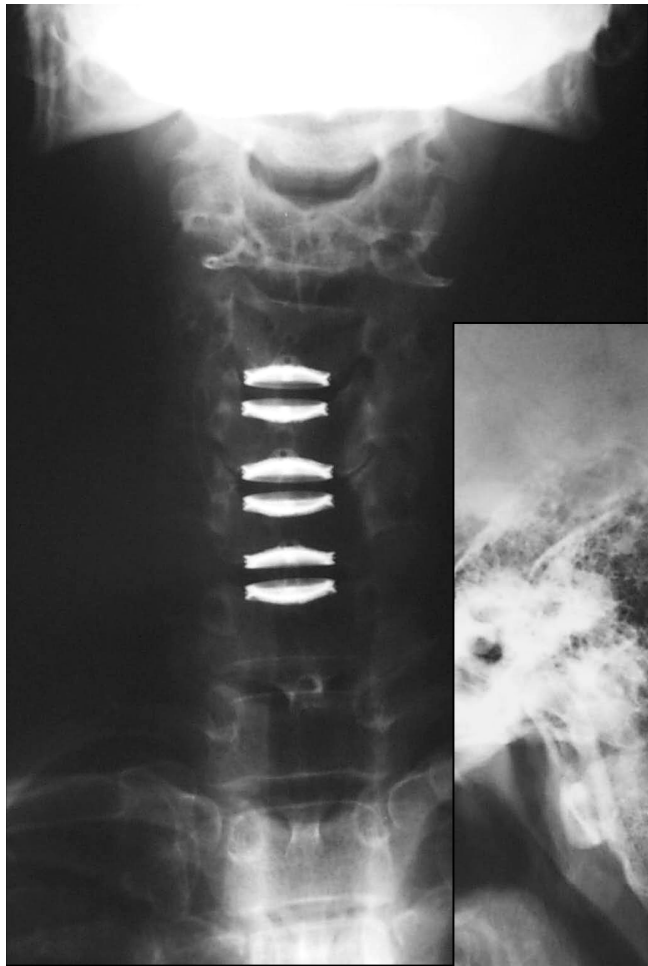# THREE ADJACENT HERNIATIONS



# Male, 45 Y, C7 right cervicobrachialgia



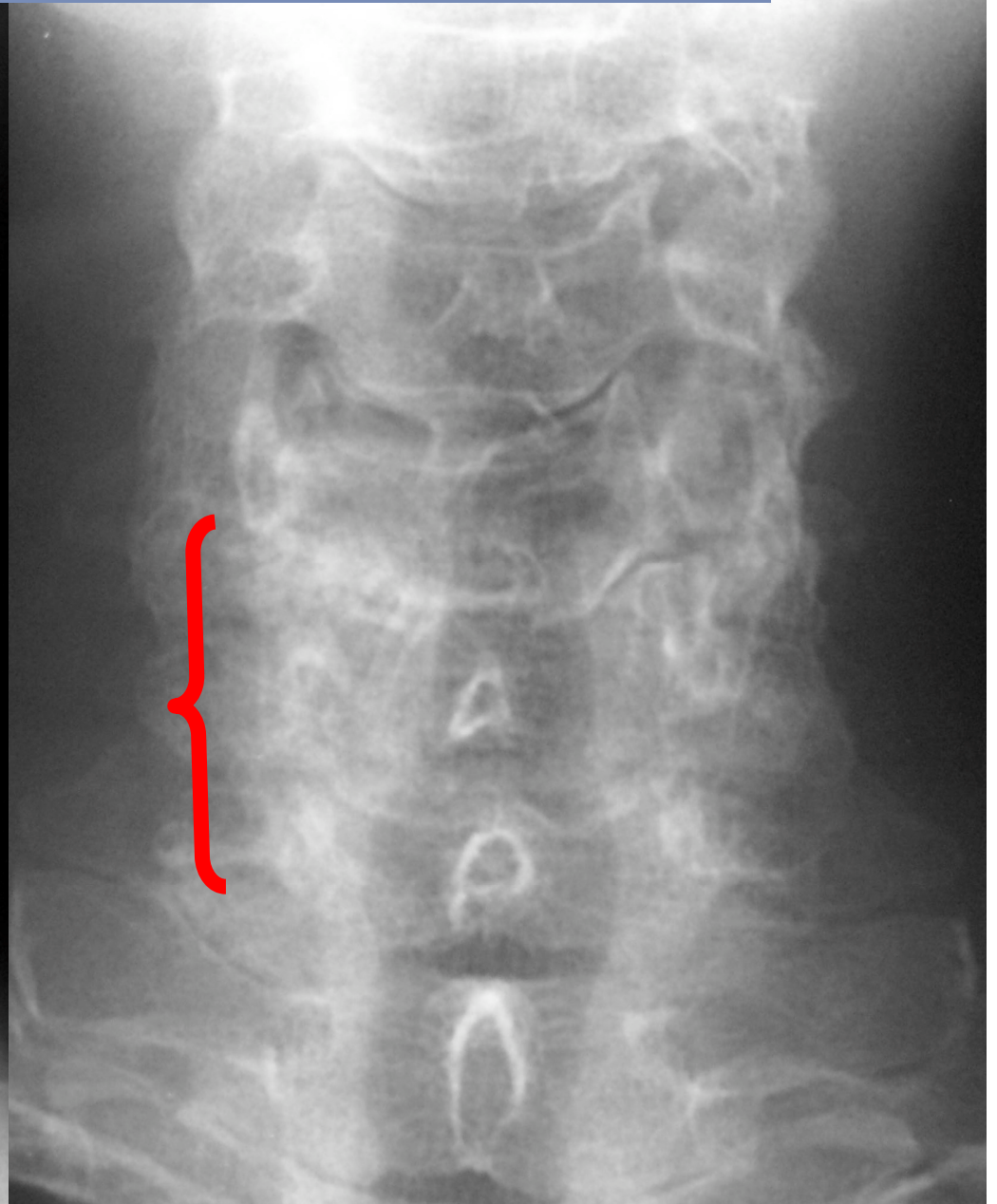
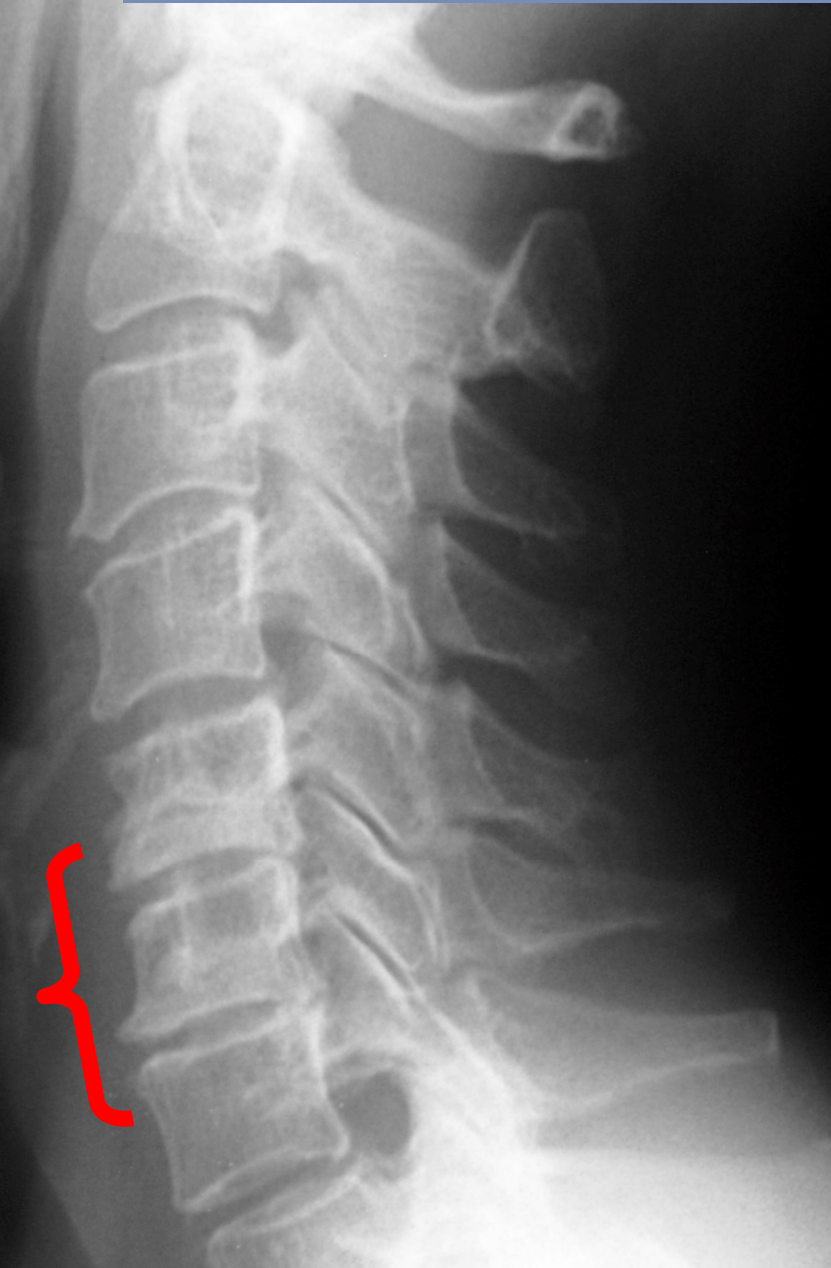



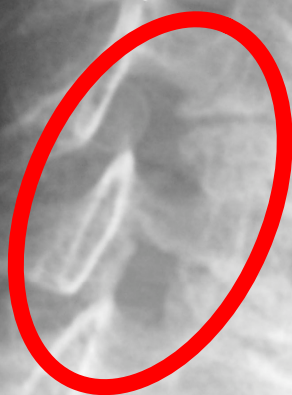- **TWO or MORE CAGES**



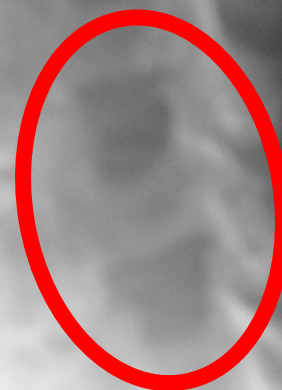**Female , 53 y , rigth C.B.**



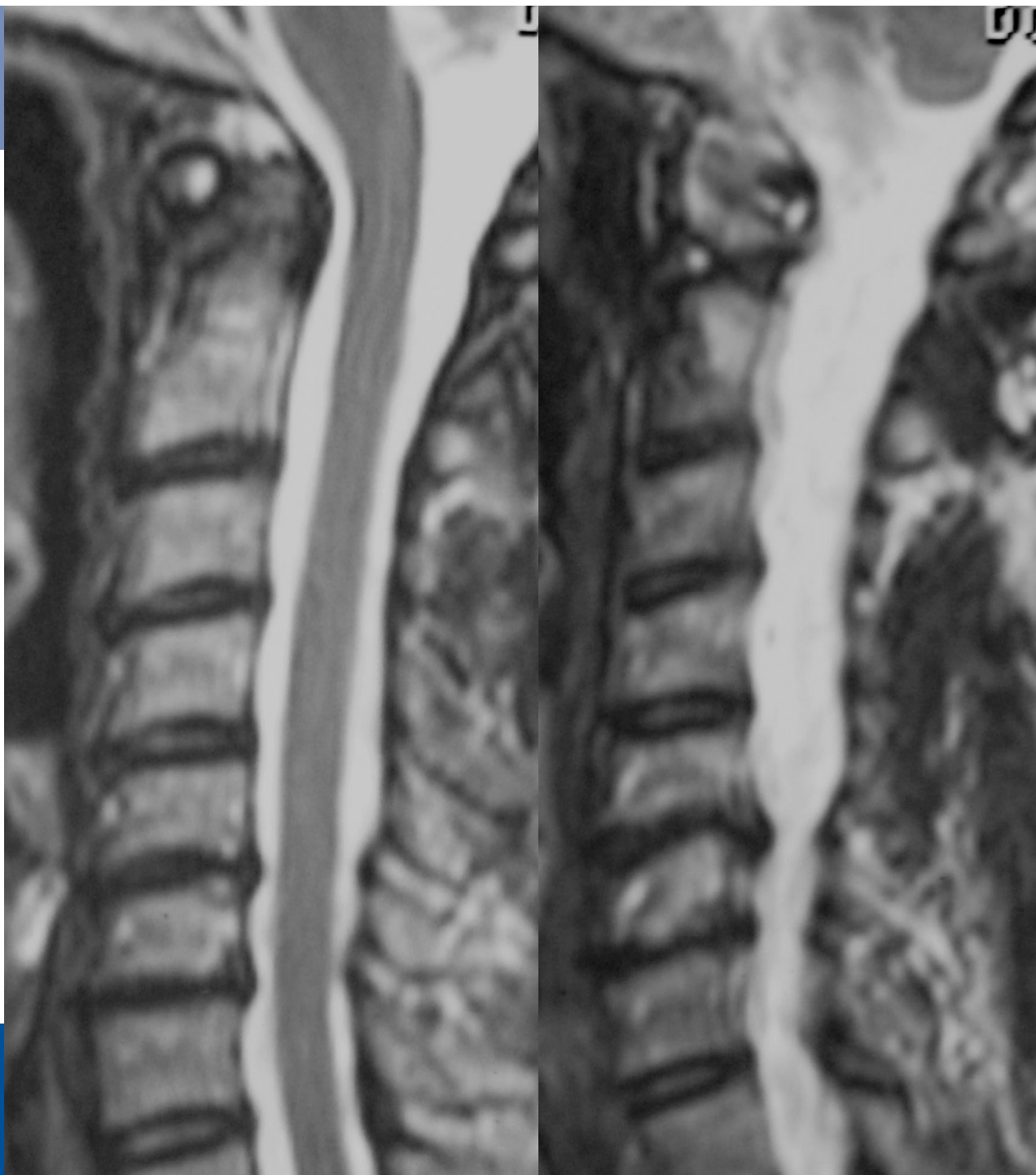
R



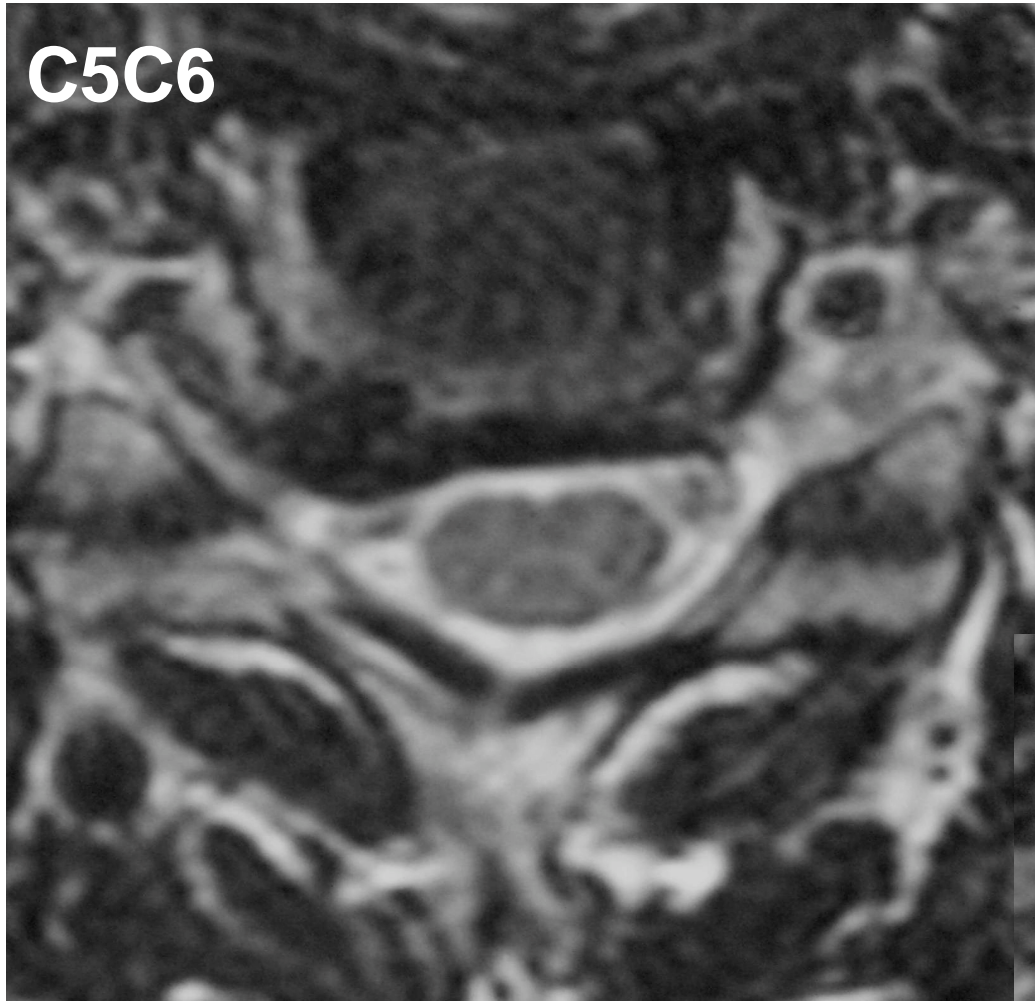
L



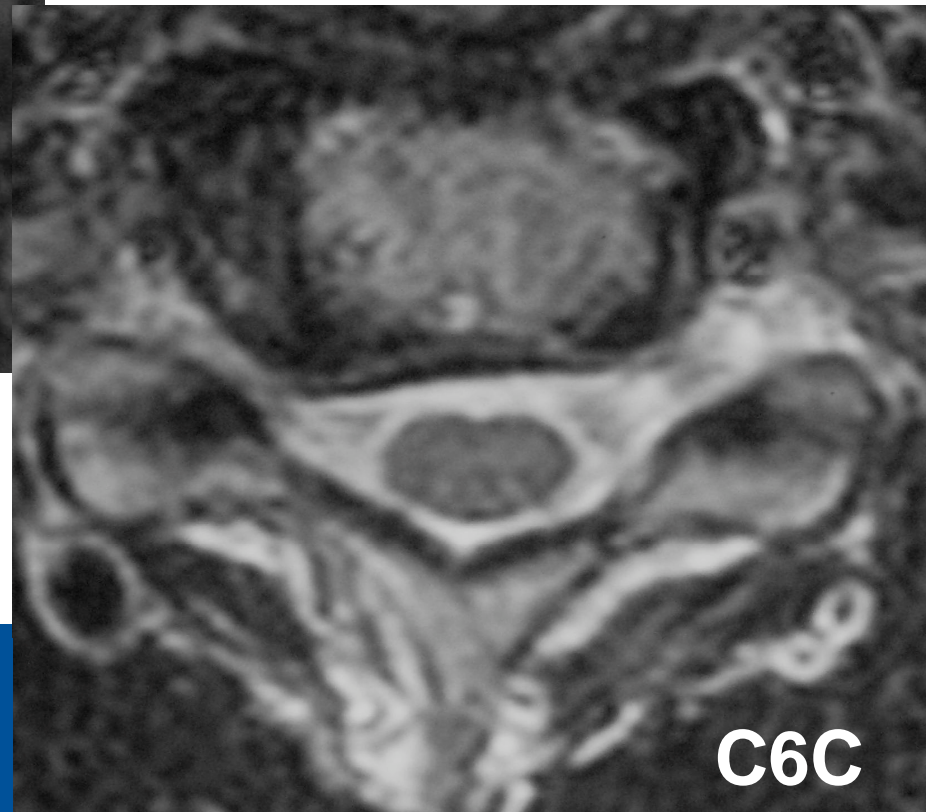




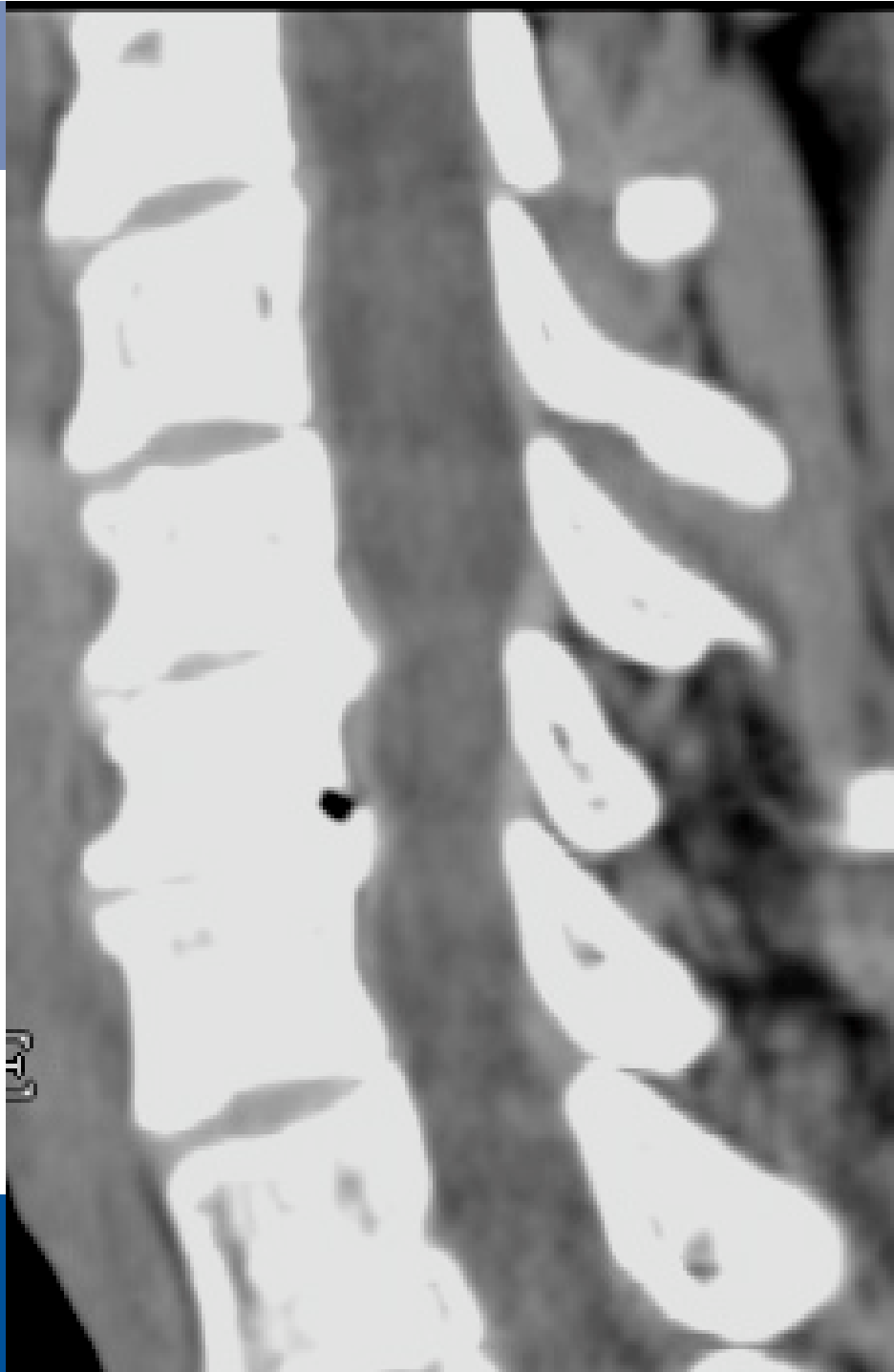
C5C6



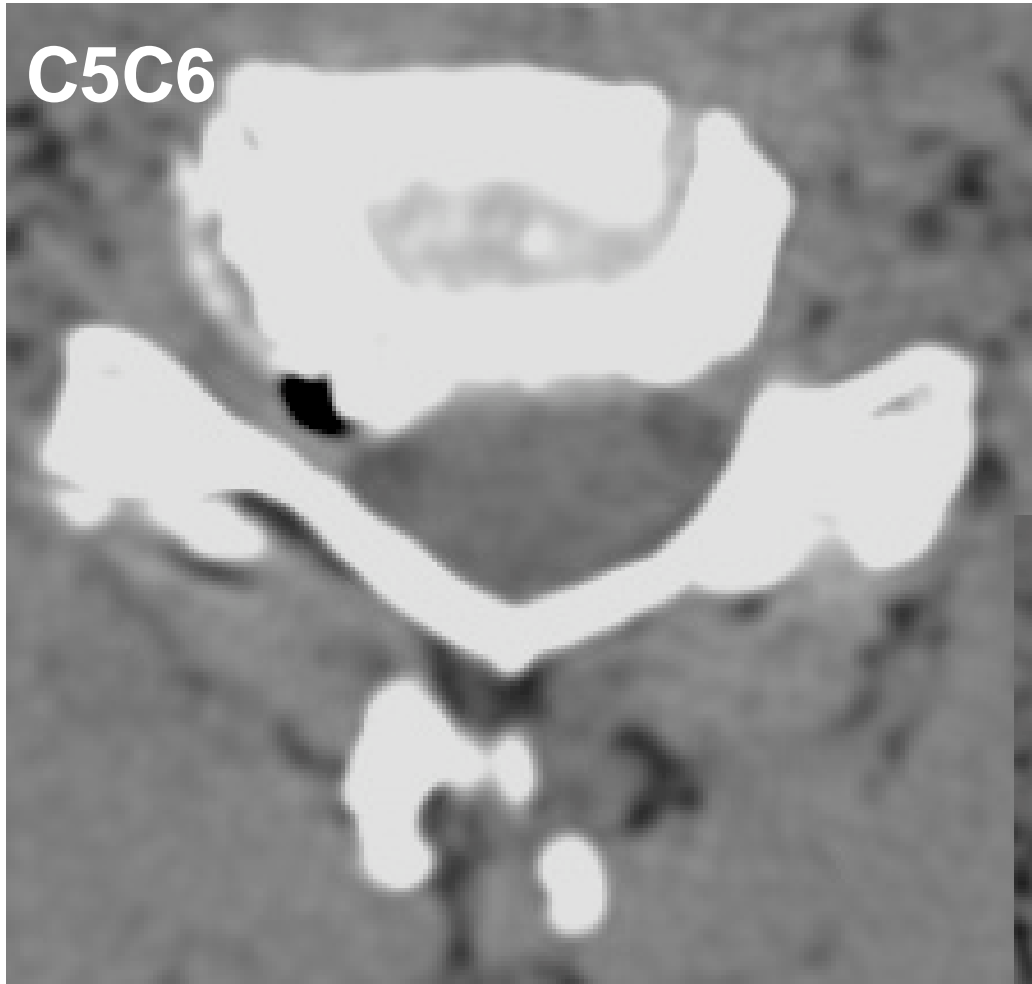
C6C



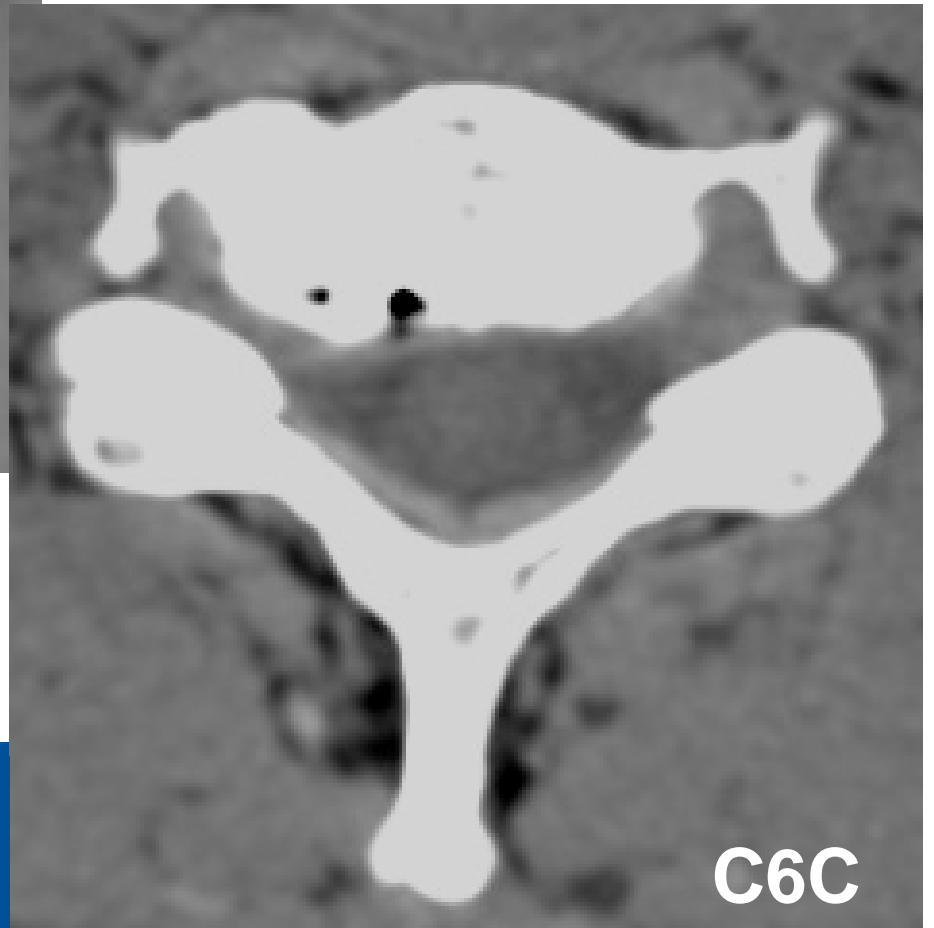


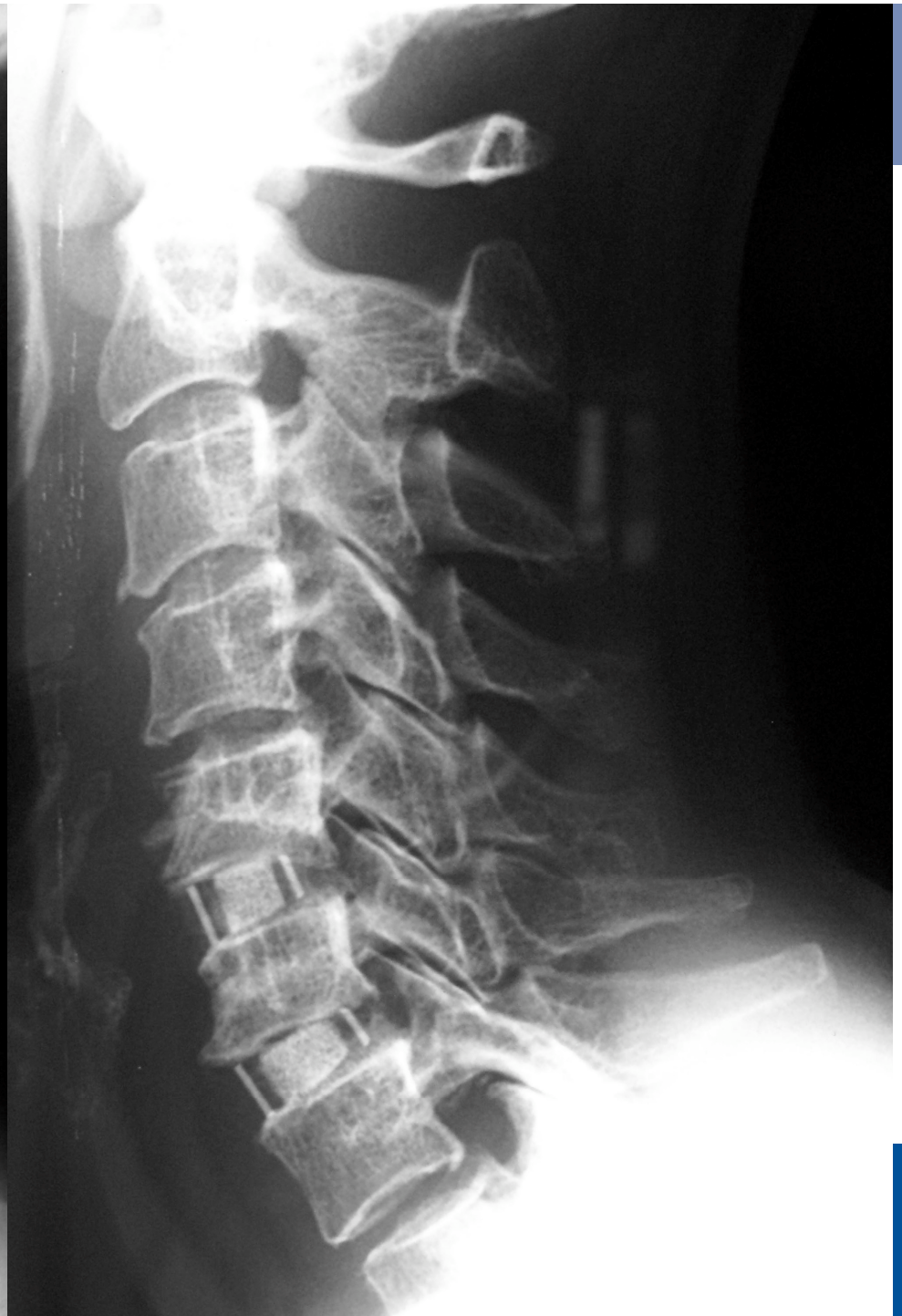
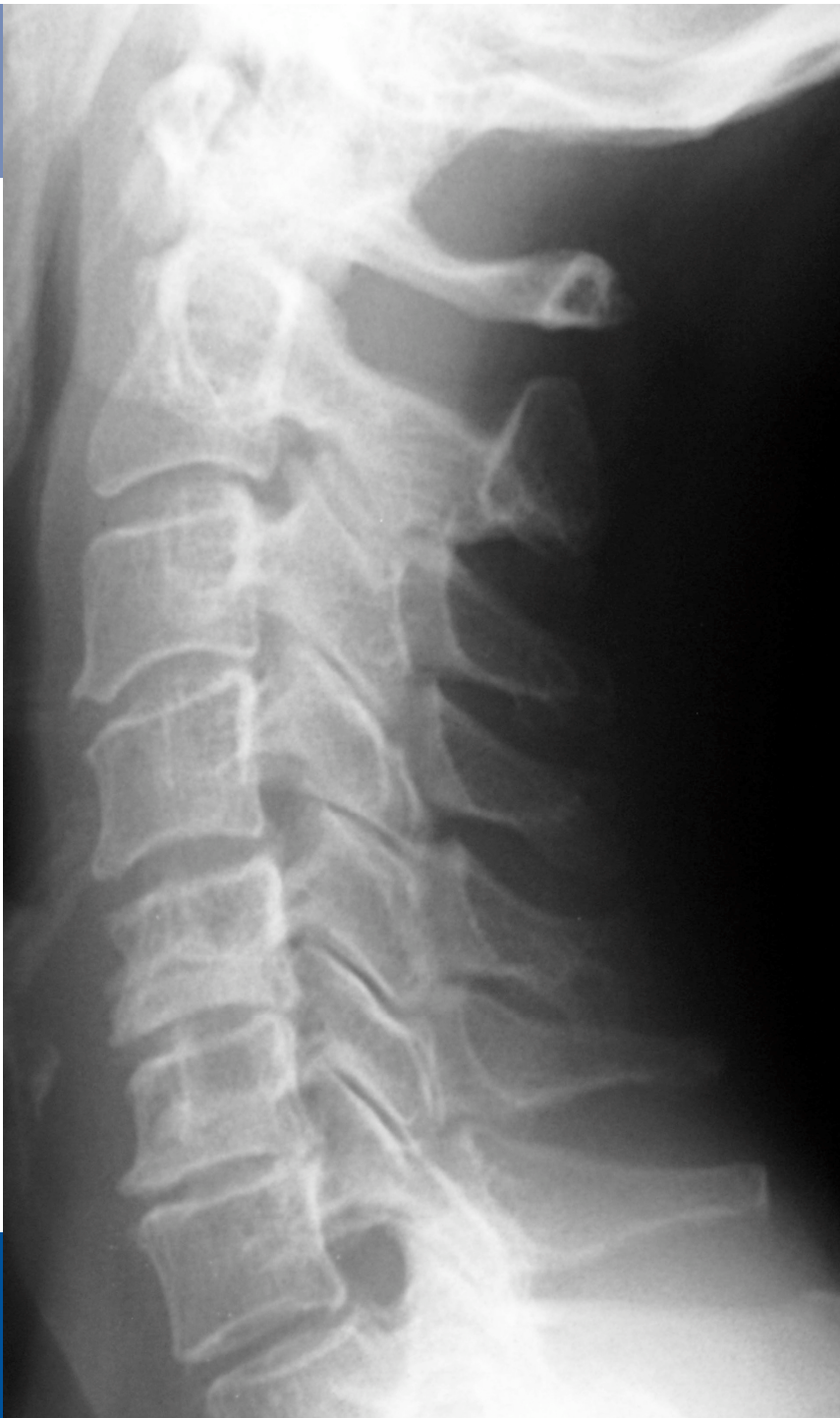
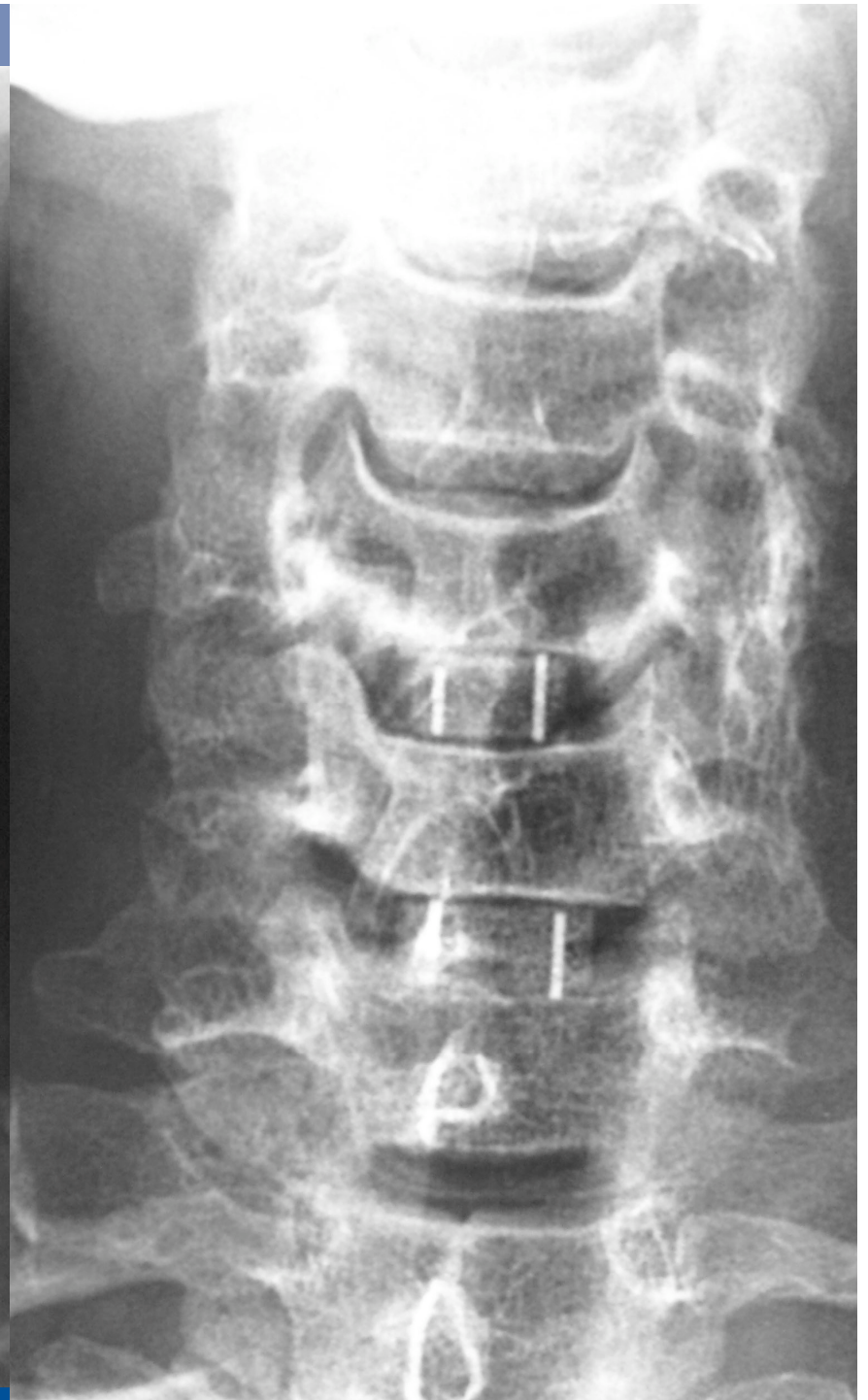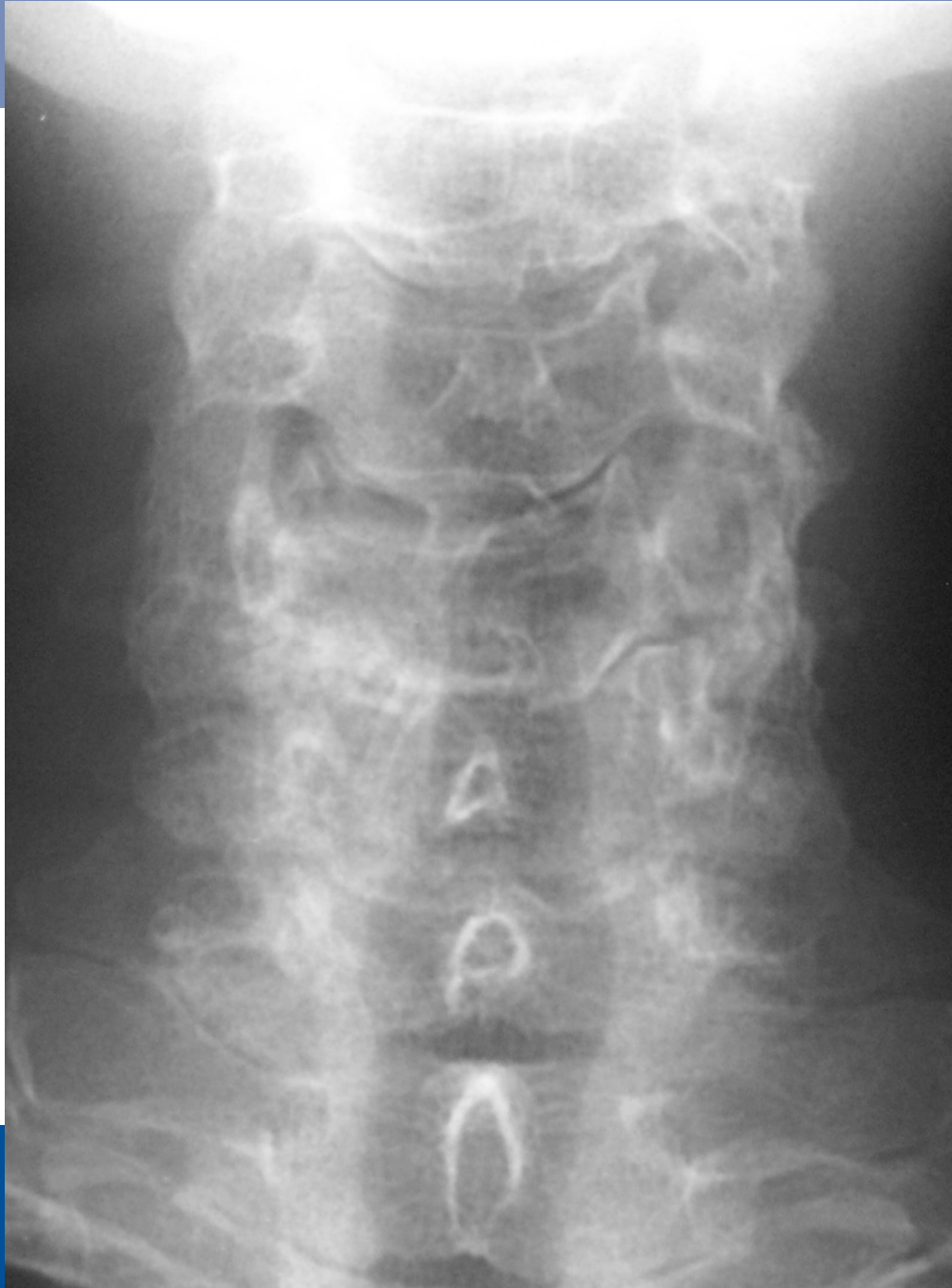C5C6



C6C

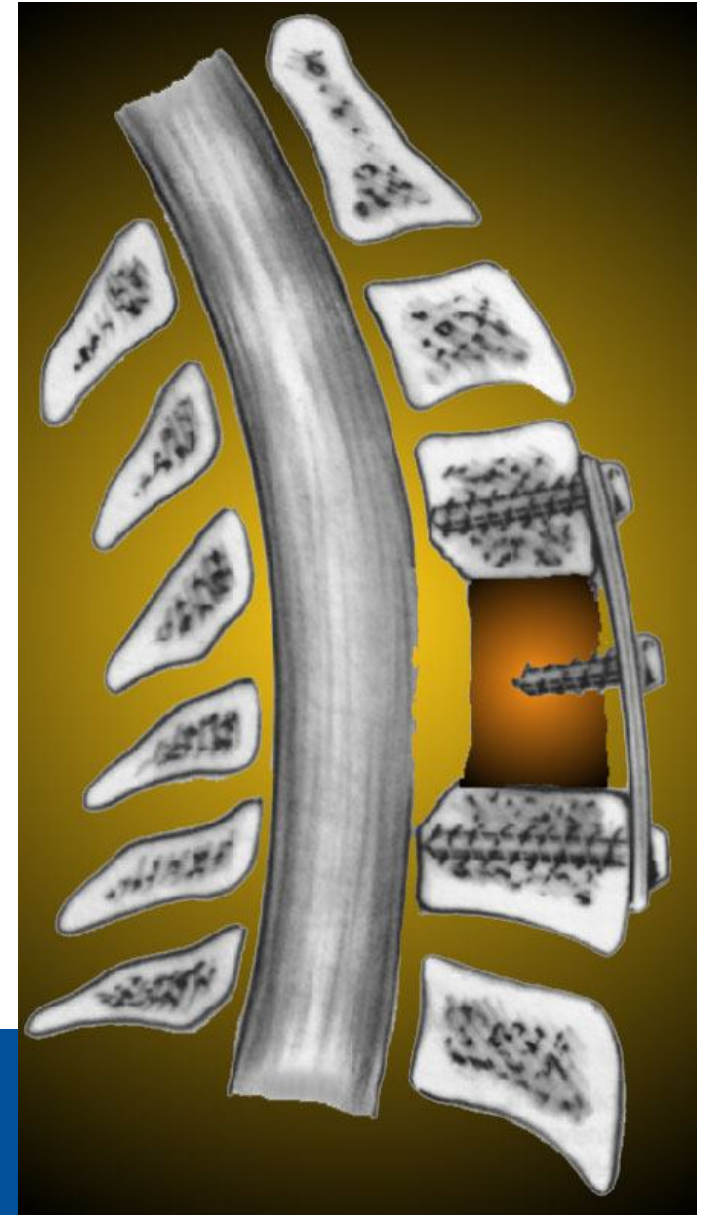
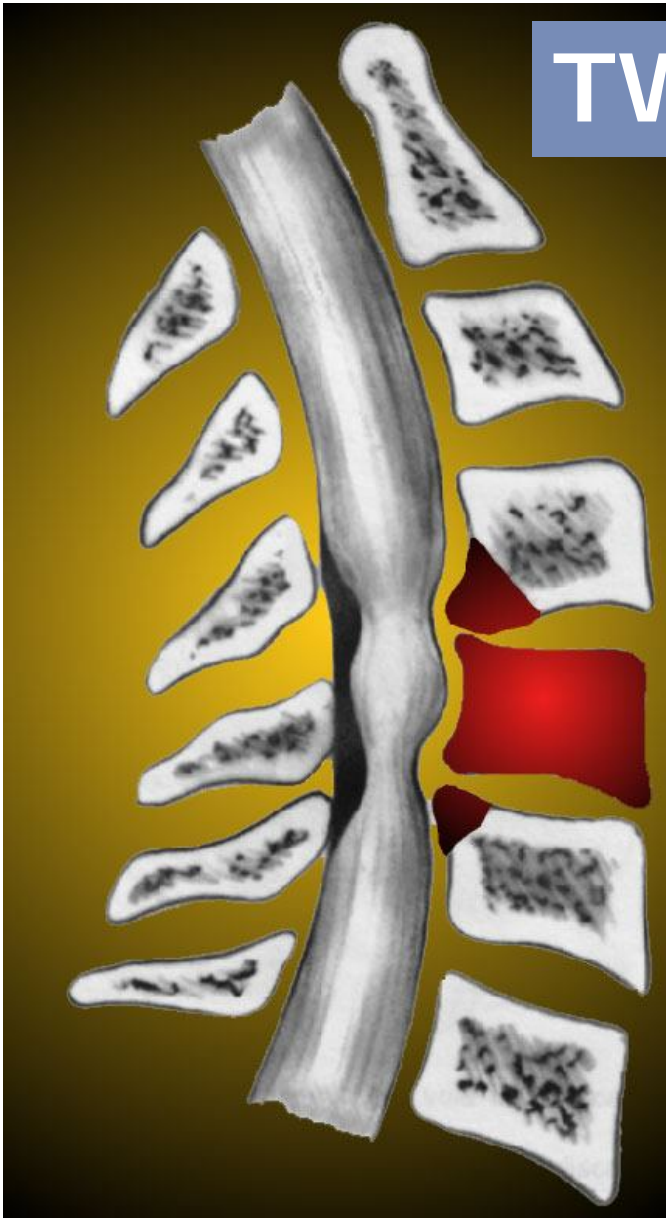




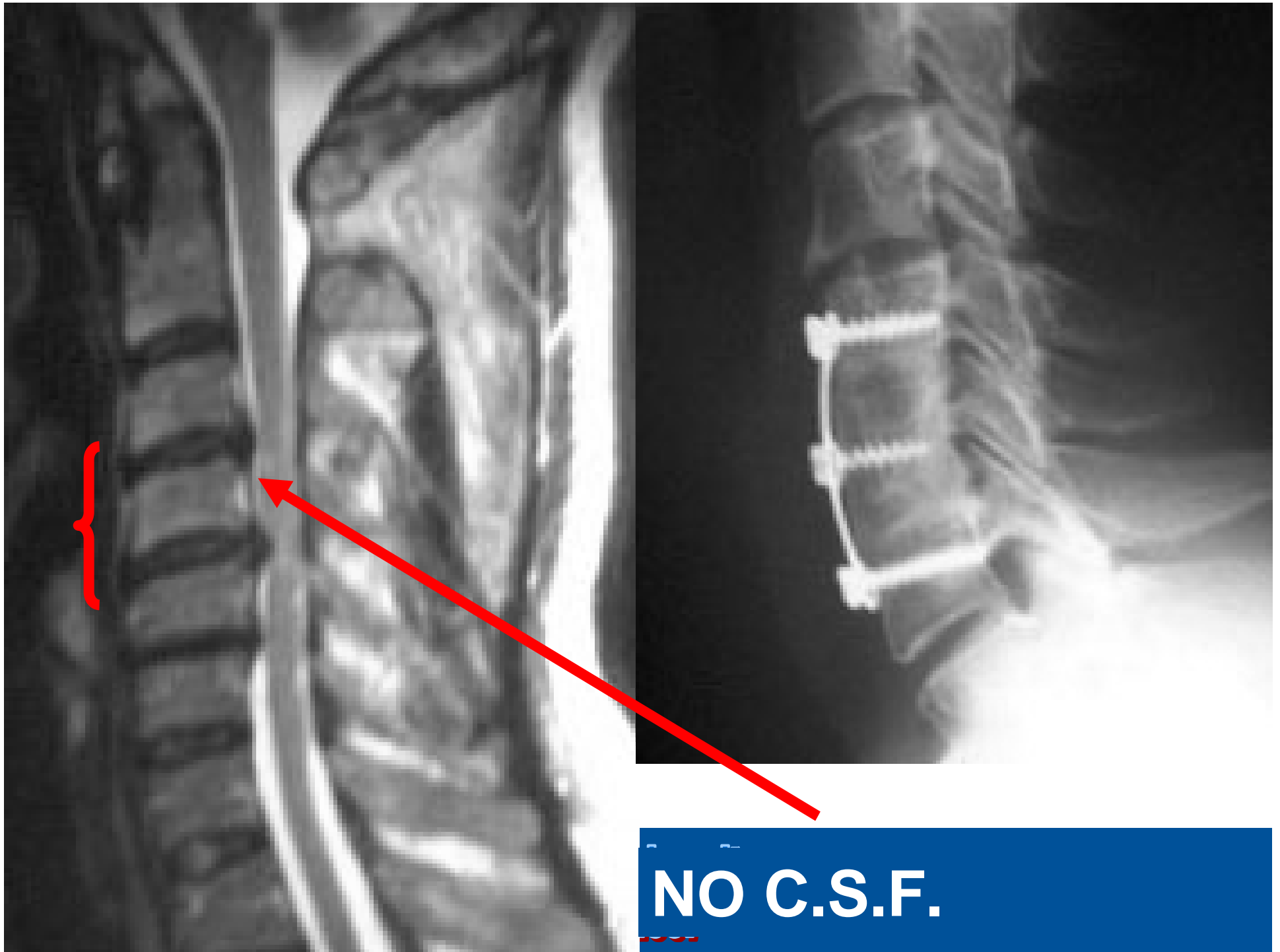




# TWO CAGES ALTERNATIVE

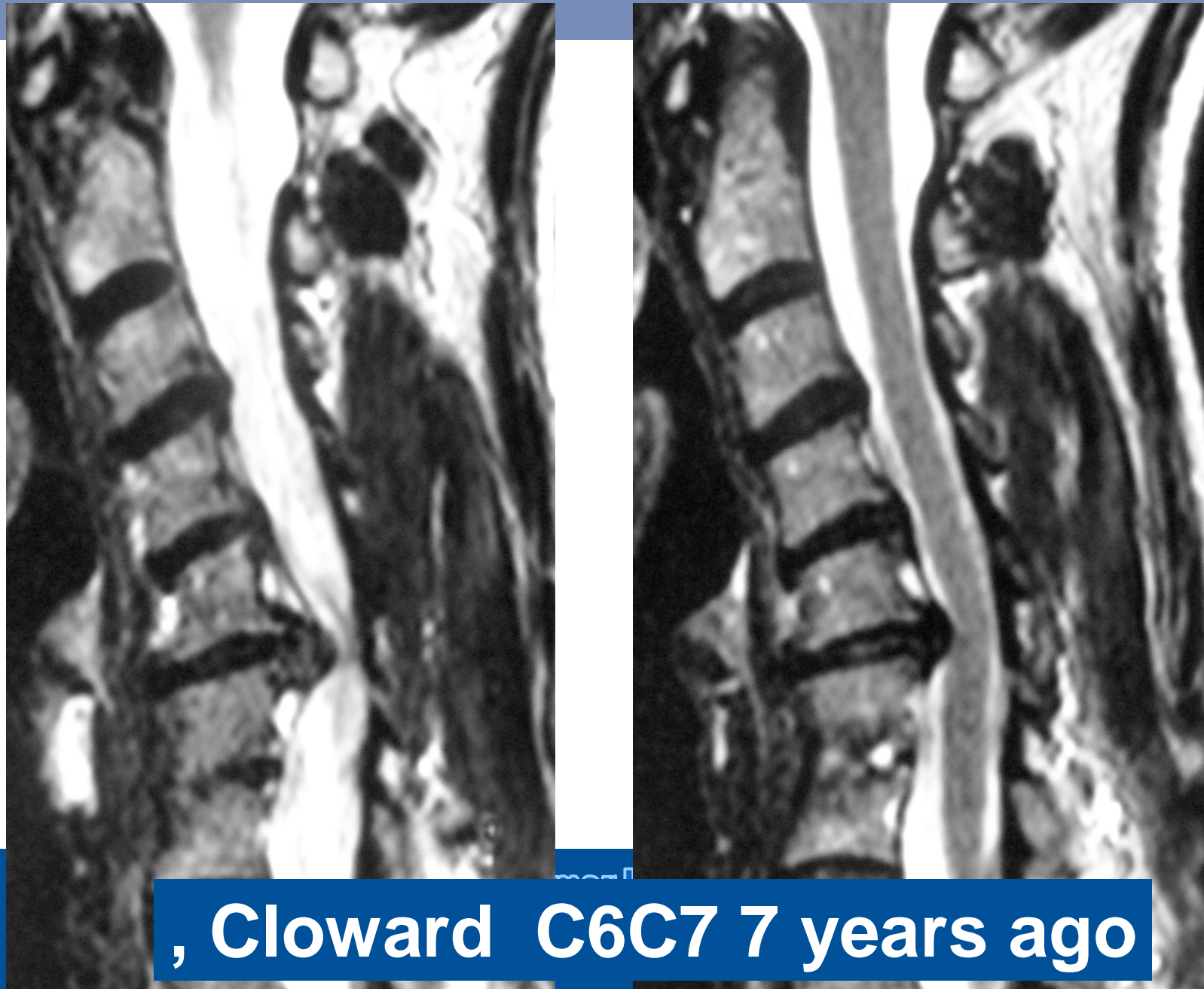


Subtotal Corpectomy



- DELAYED **HYBRID** RECONSTRUCTION

**Female , 51 y , rigth C6 cervicobrachialgia**

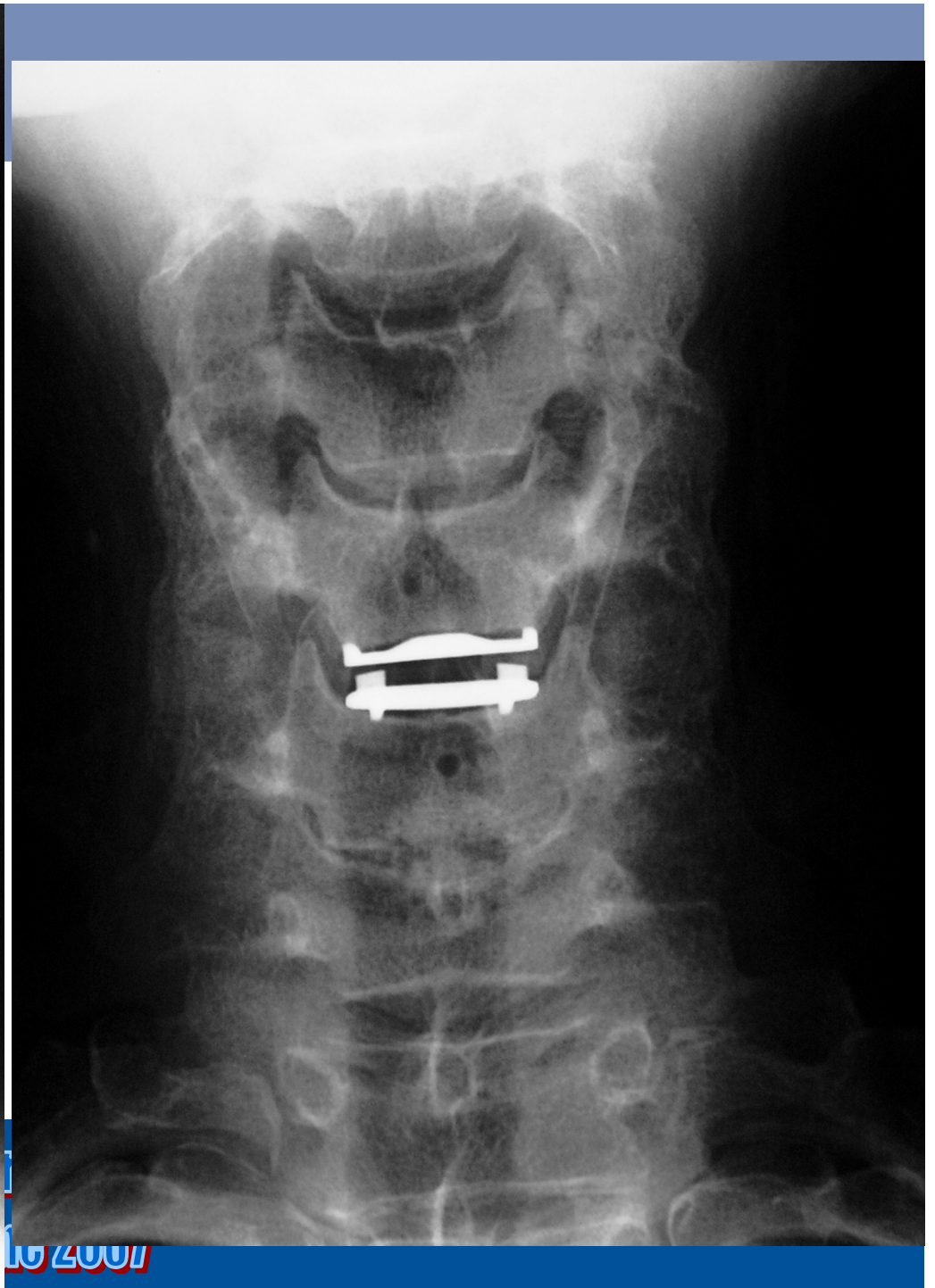
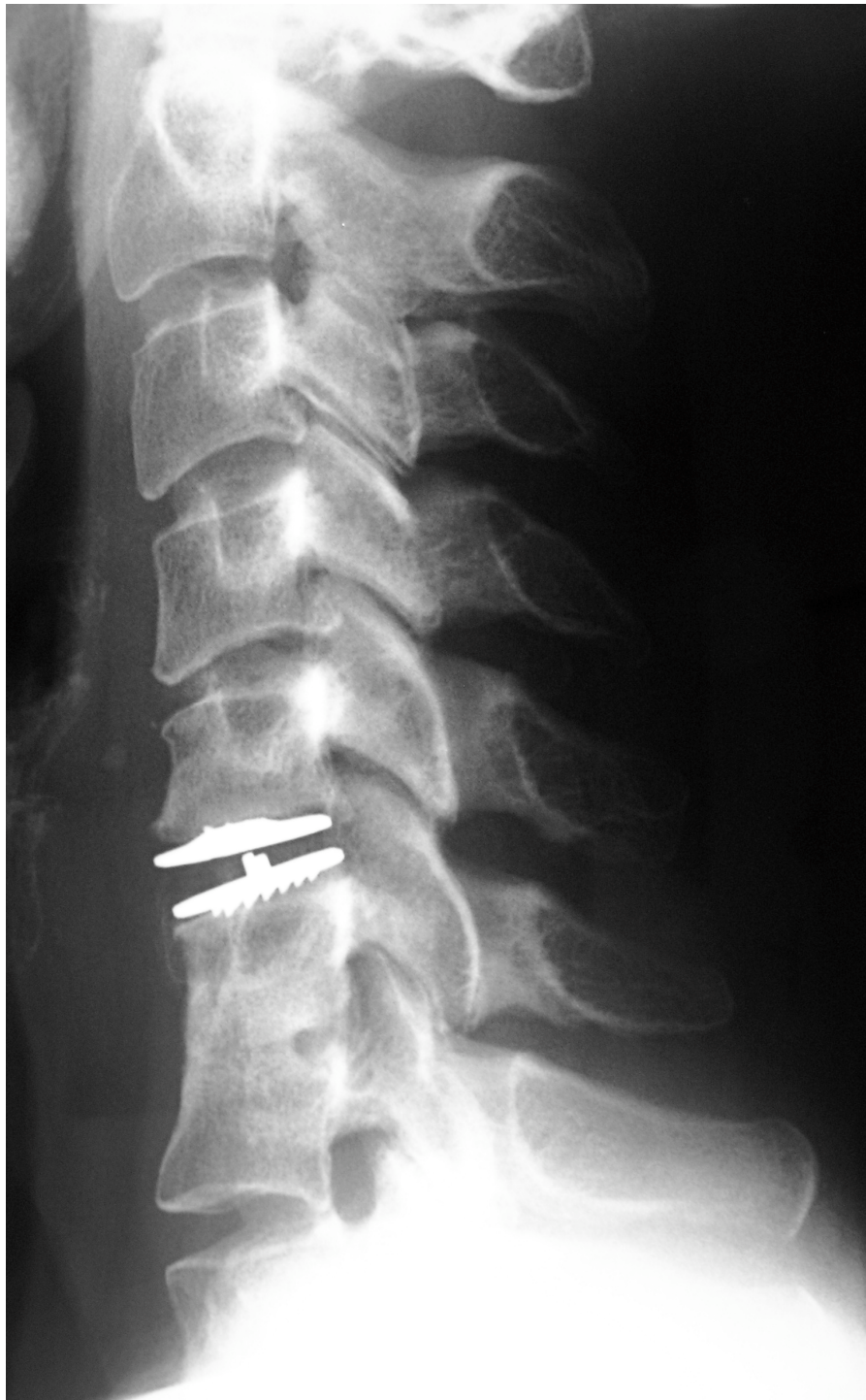

**, Cloward C6C7 7 years ago**

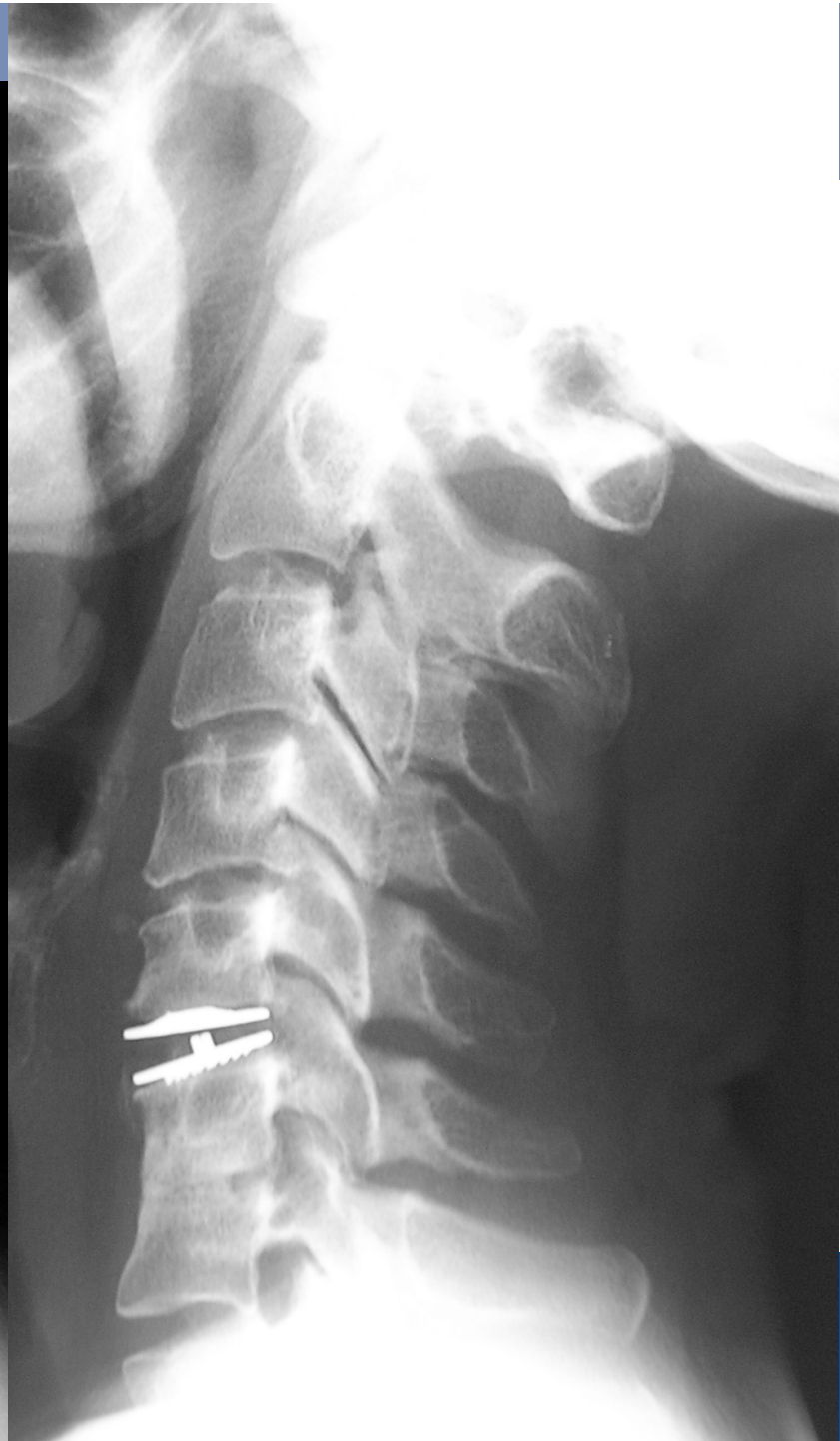
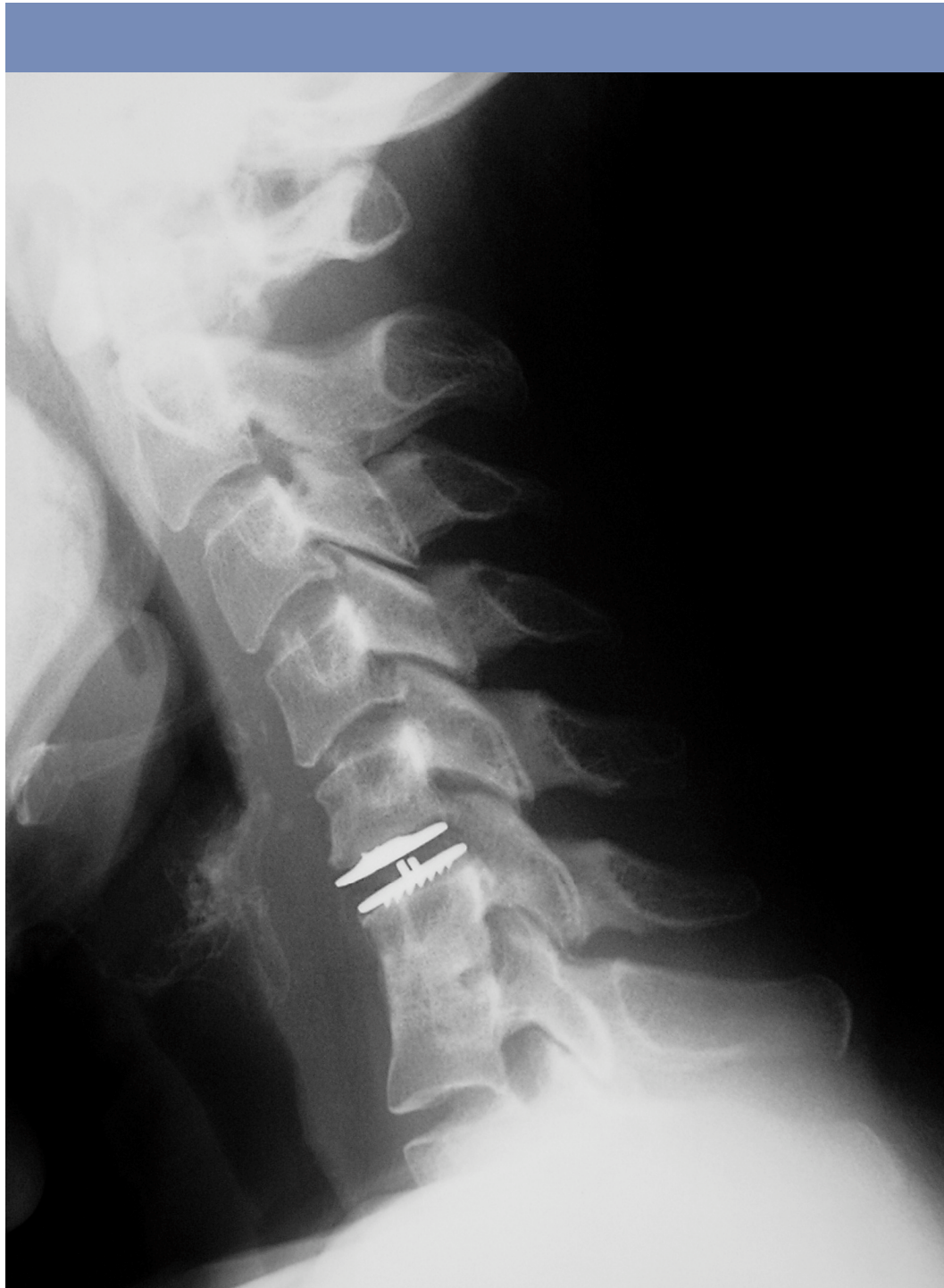
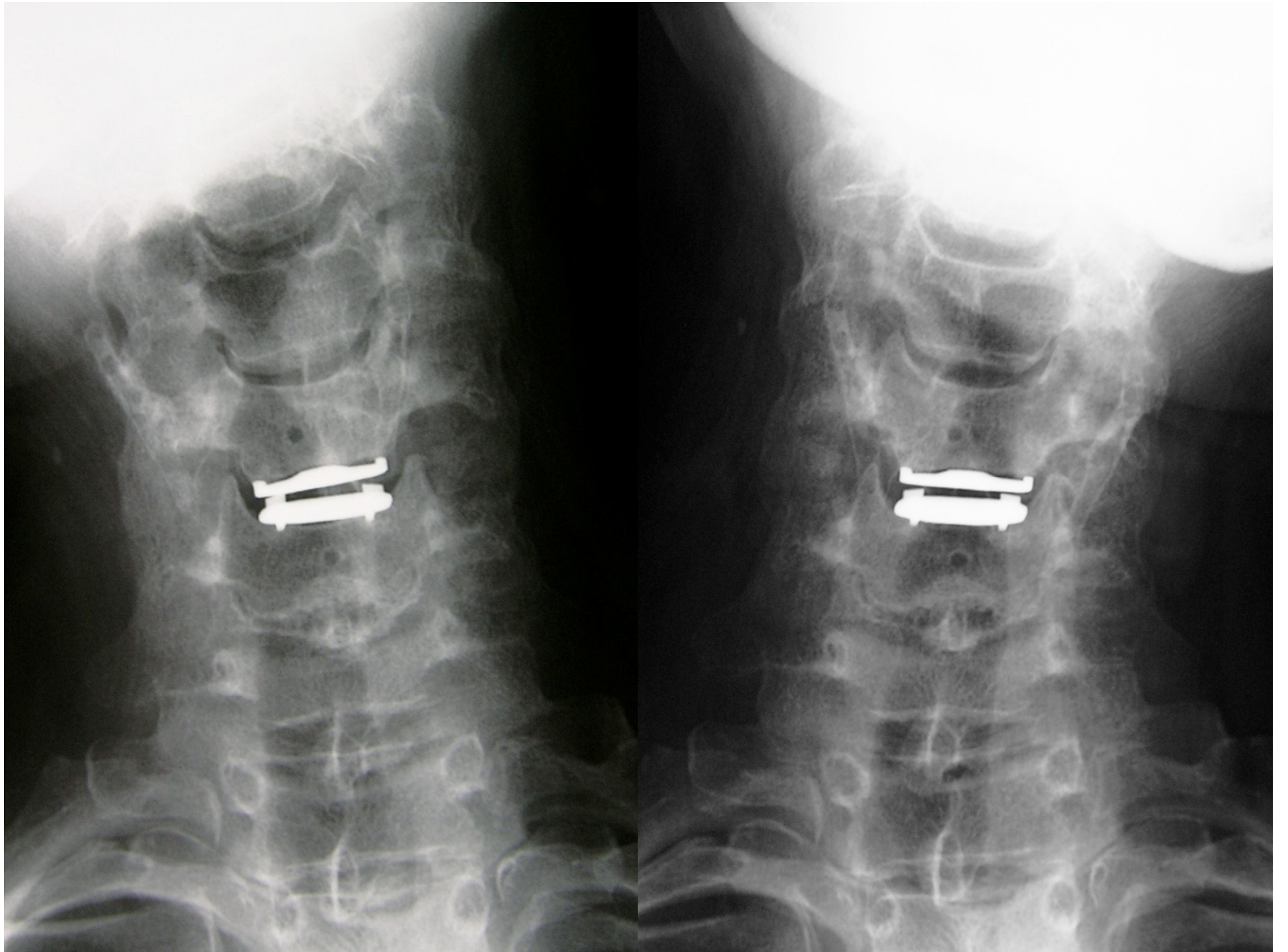


**C5C6**

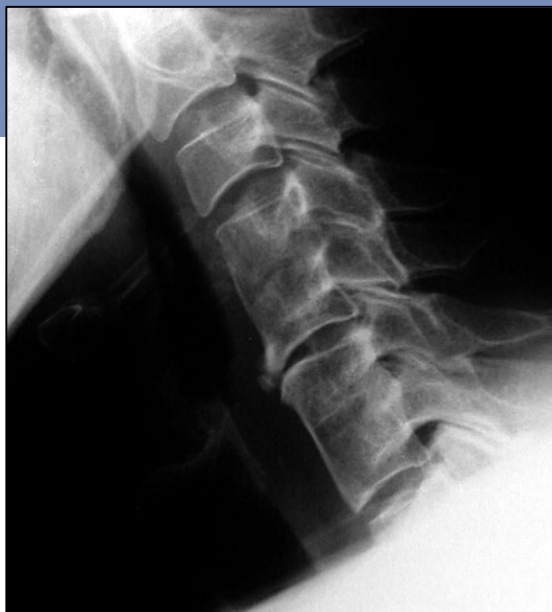











**Fusion C6C7**

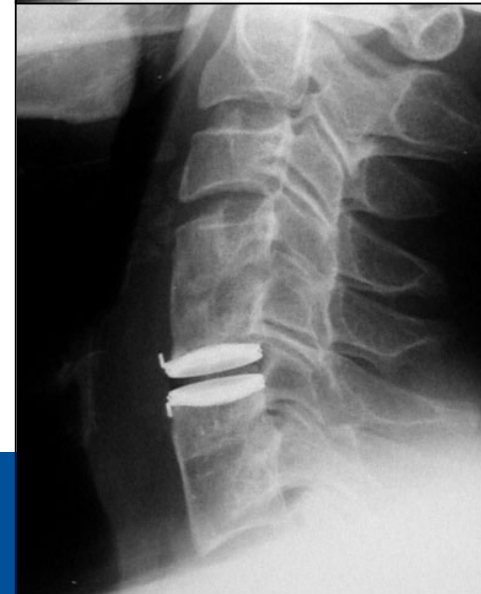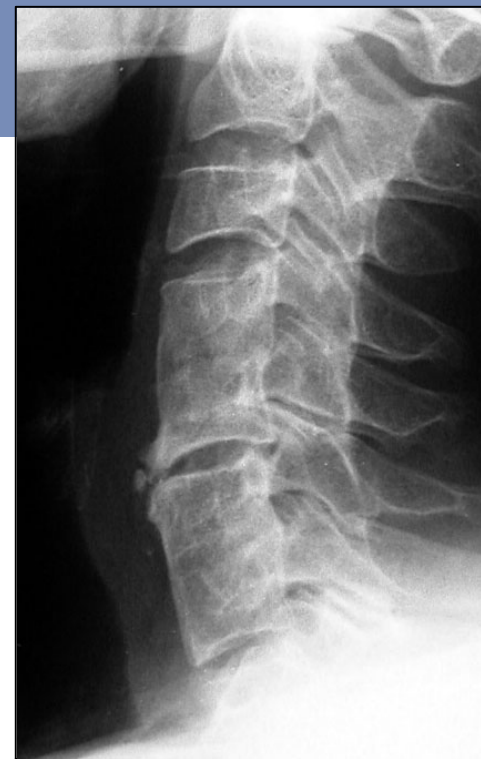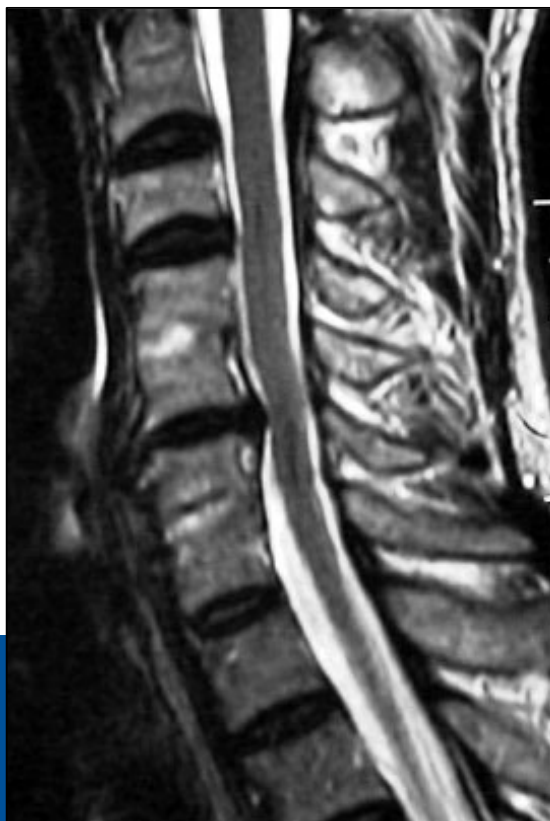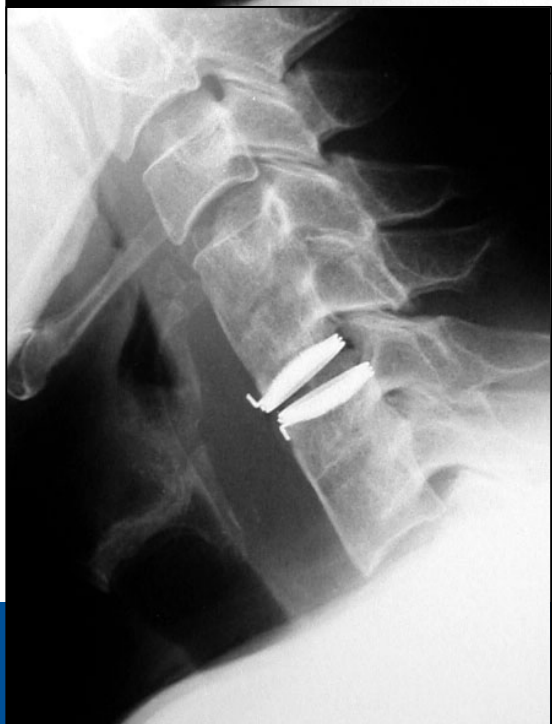**1996**

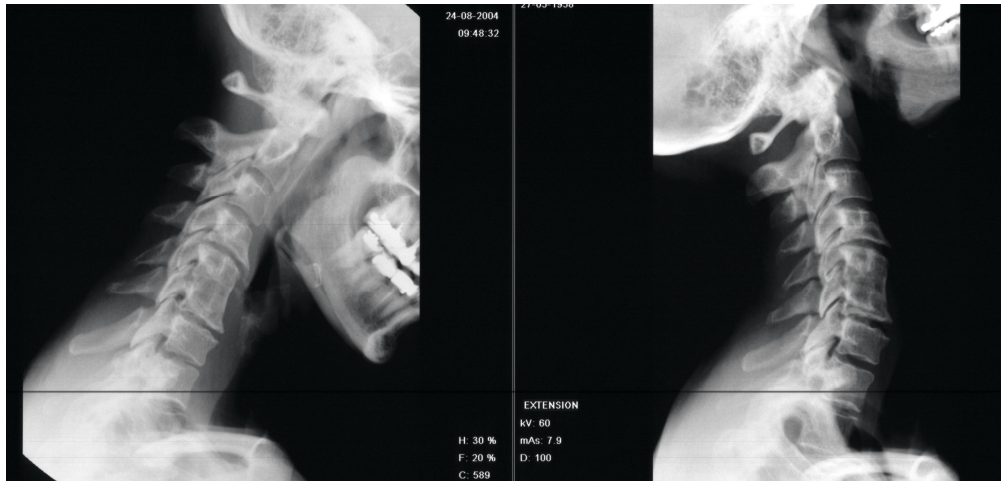
**Fusion C3C4**

**1999**

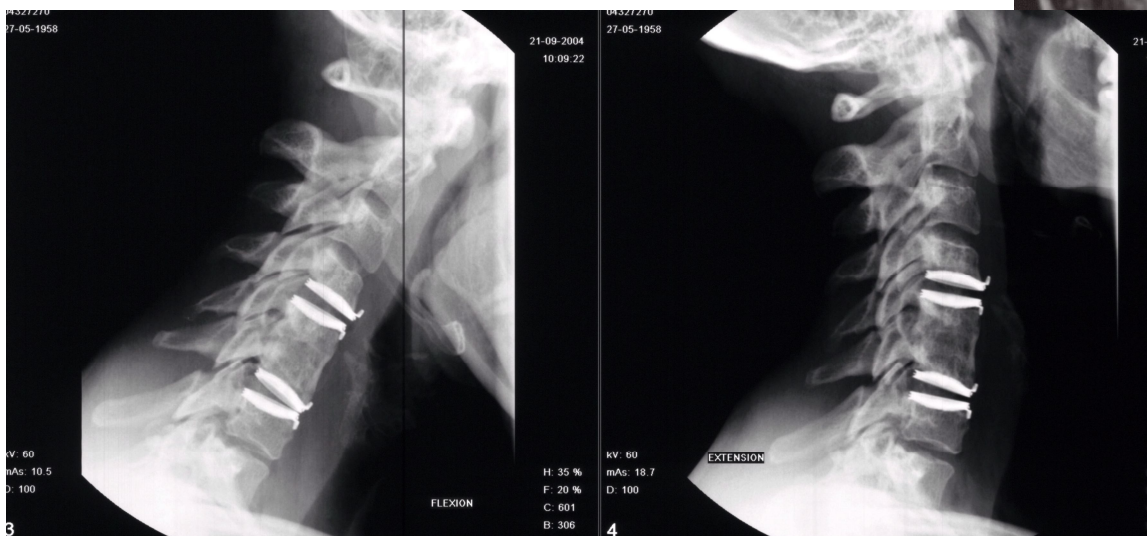
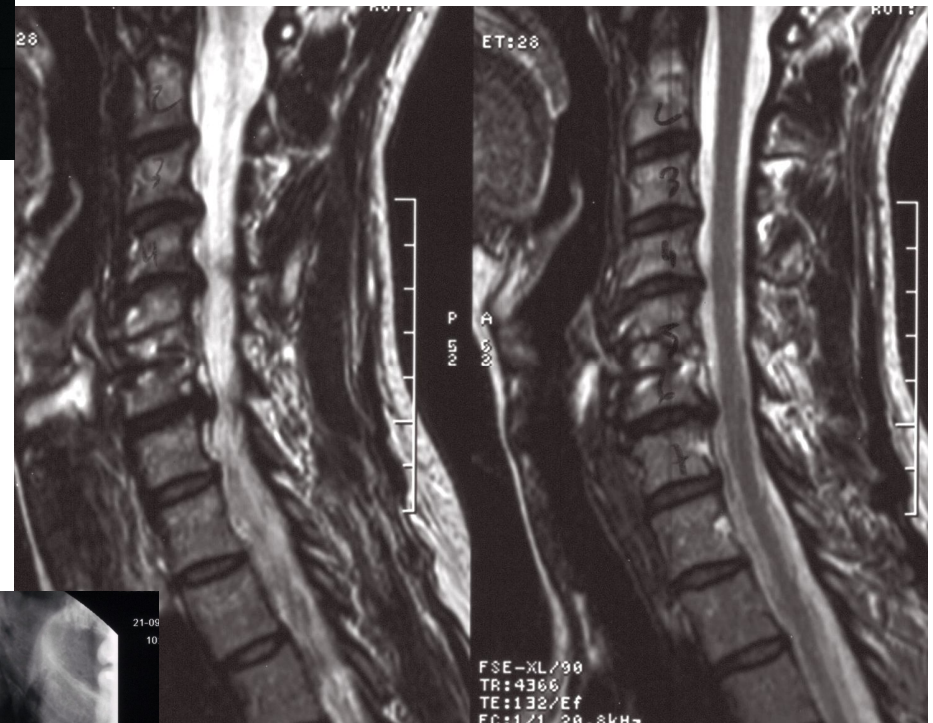
**DDD C5C6**

**2003**





**Female , 47 Y**  
**Operated 5 years earlier**

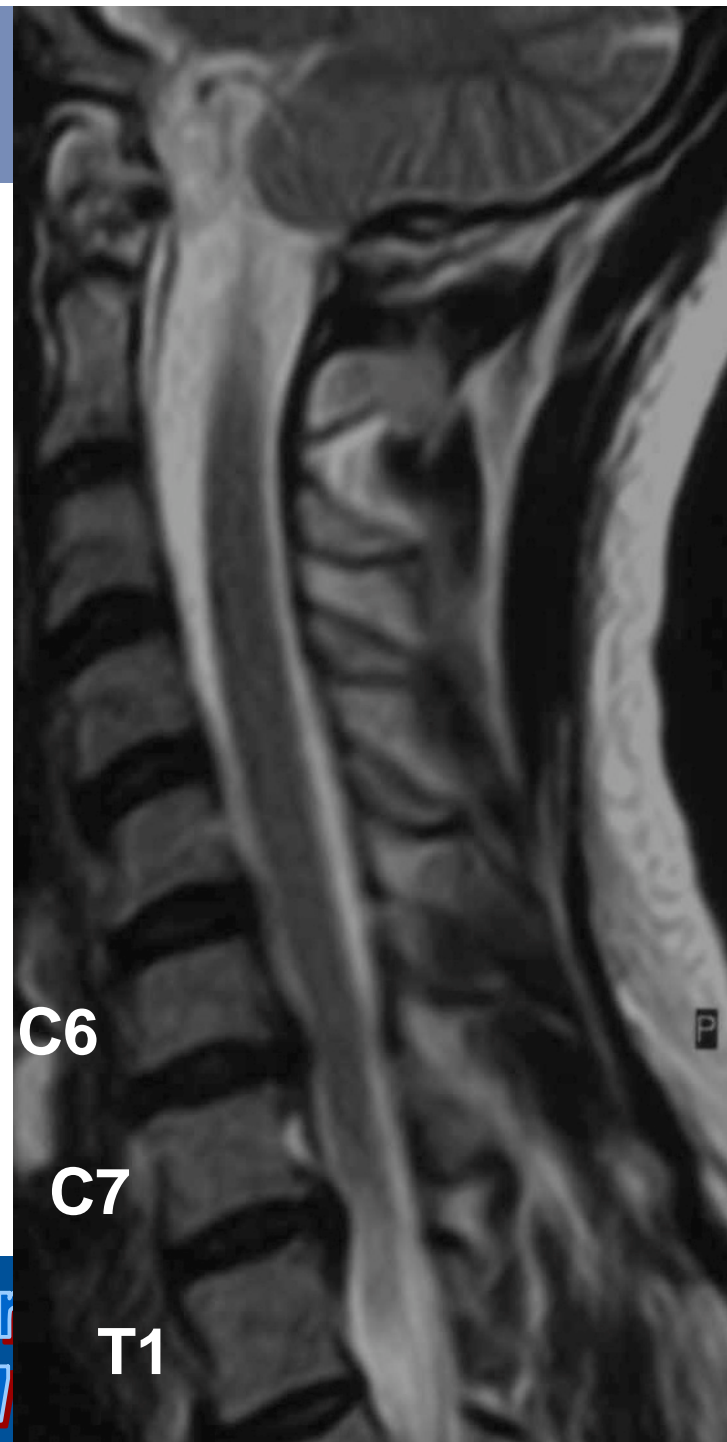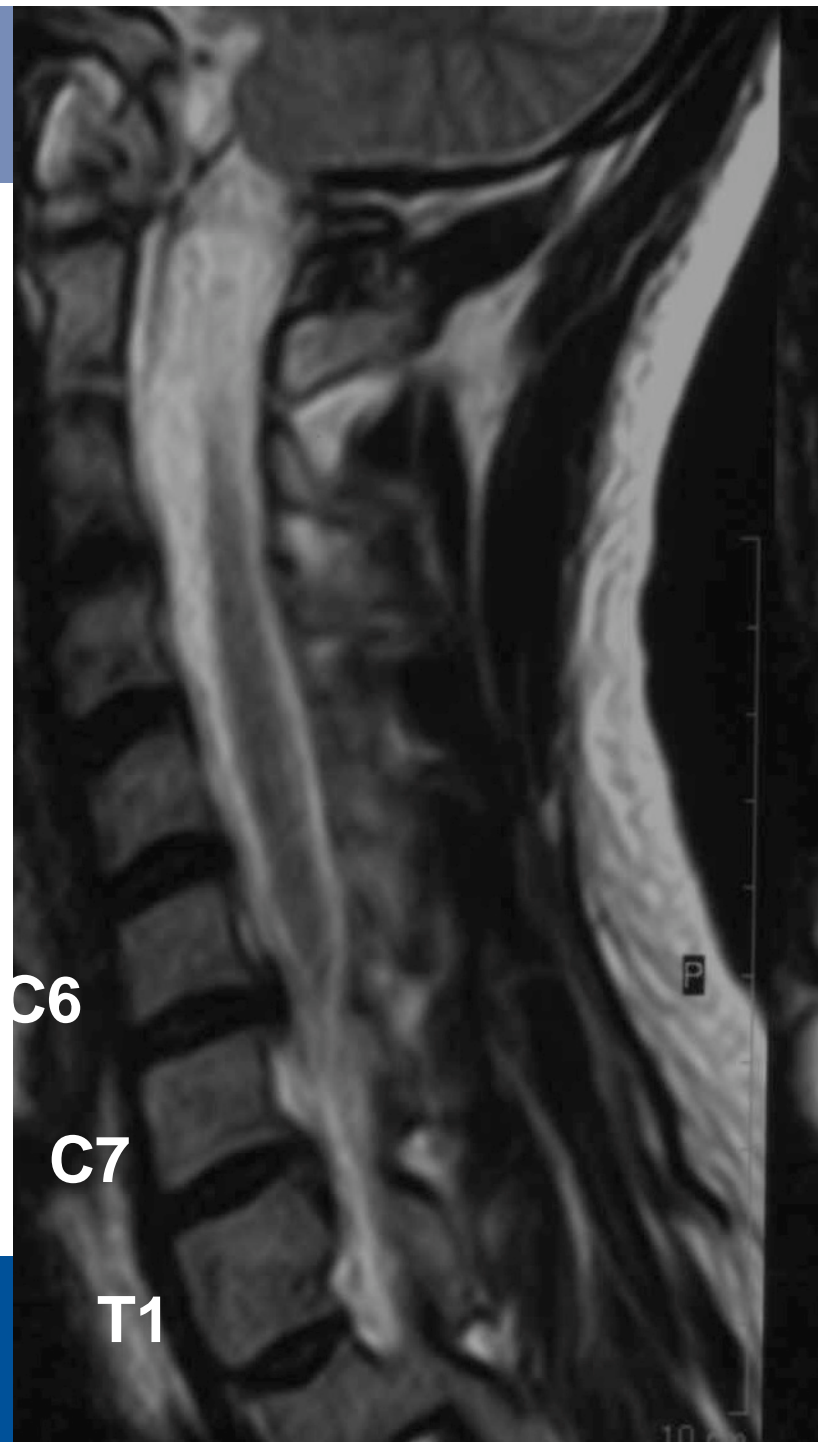


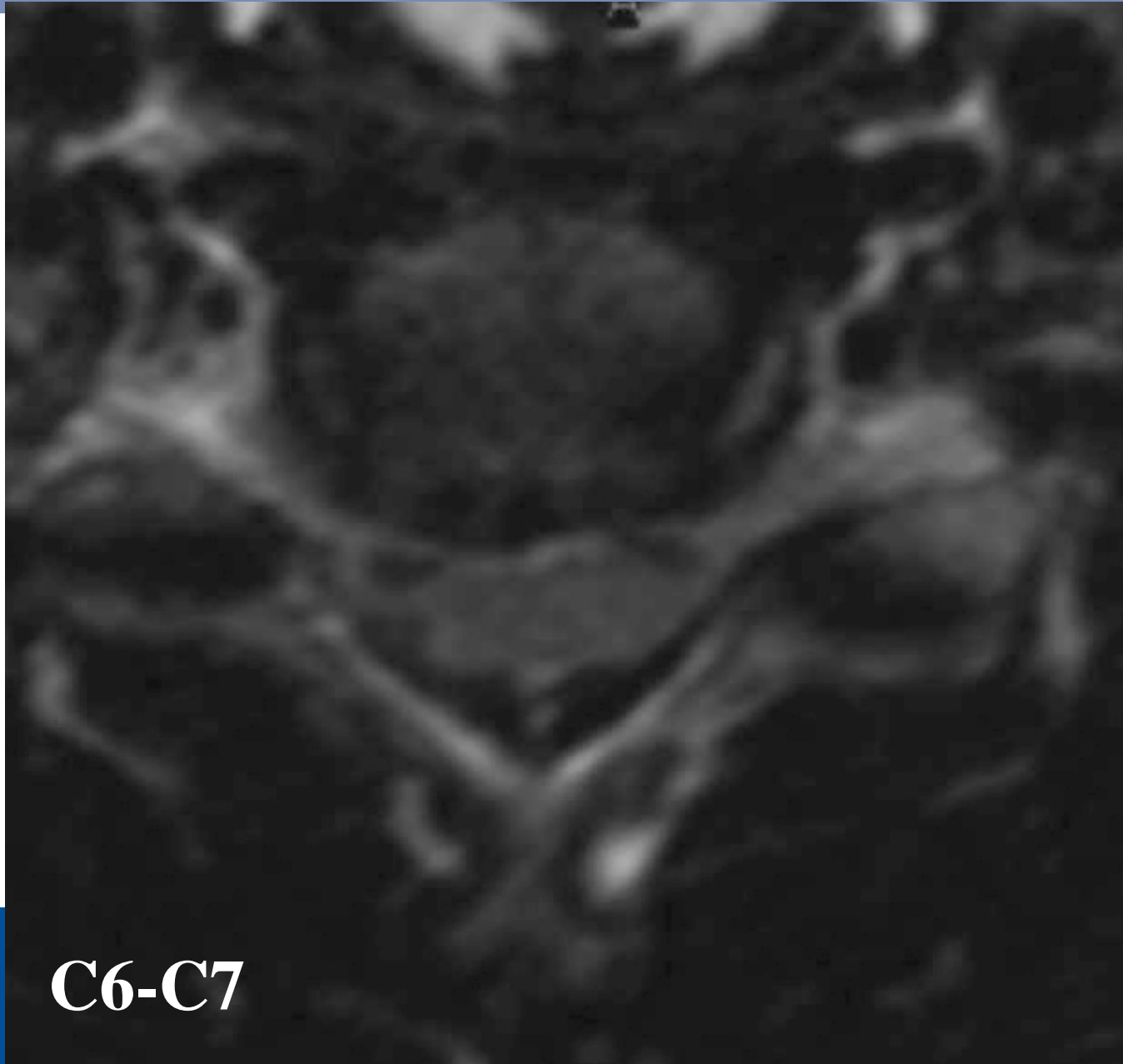
- **CONCOMITANT HYBRID RECONSTRUCTION**

**Mr GUT. born on 1964 june 27th**

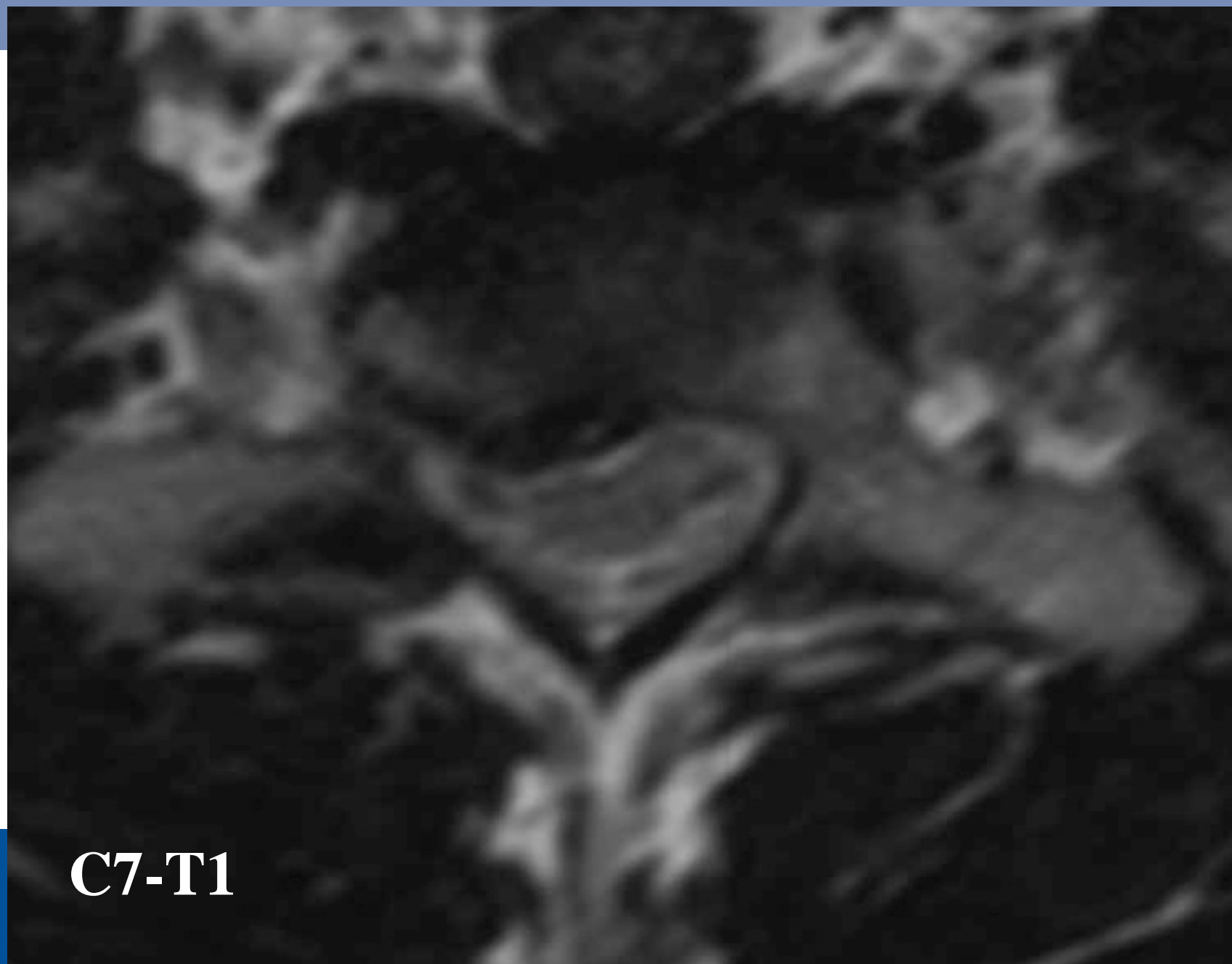
- **Right cervicobrachialgia C7+C8 since 14 months**
- **No neurologic deficit**
- **No pyramidal syndrom**
- **Physiotherapy , no infiltration**



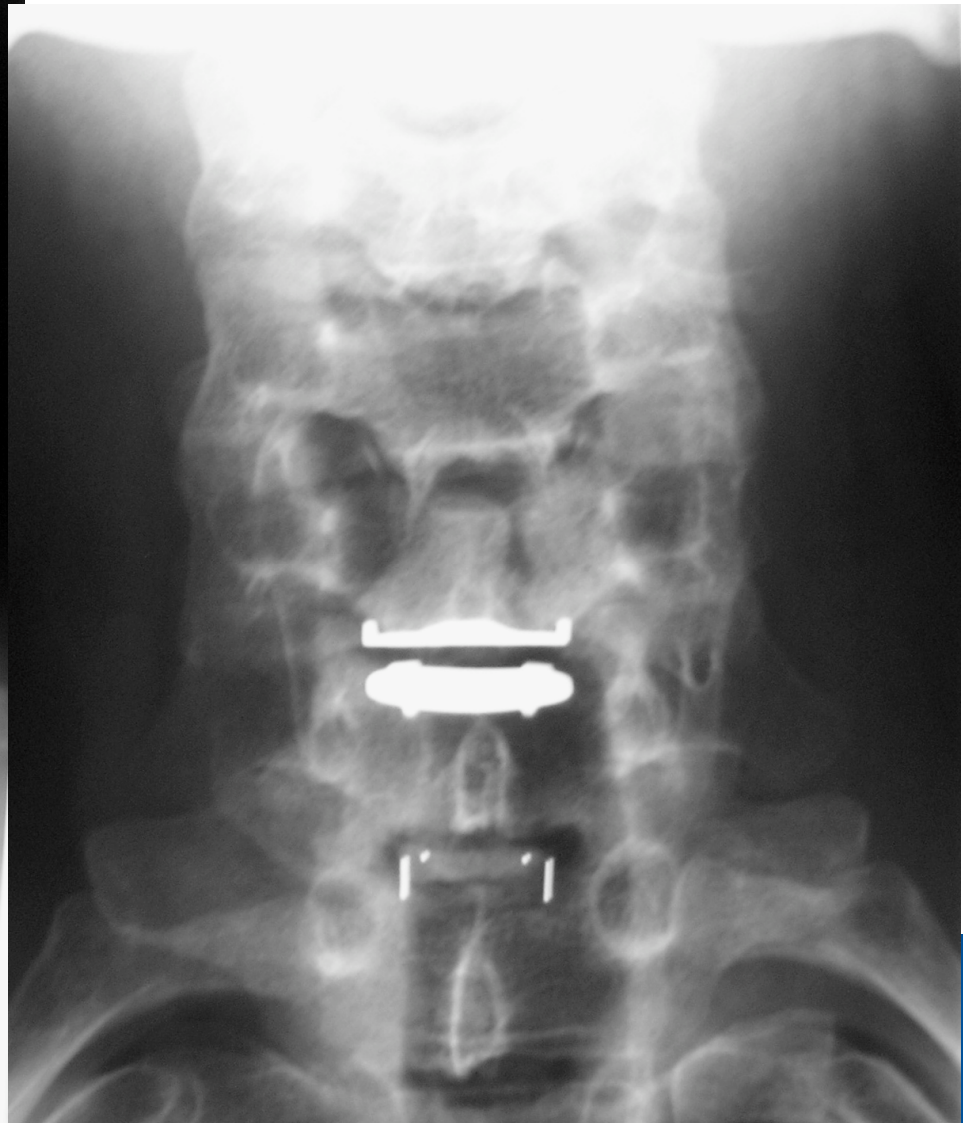
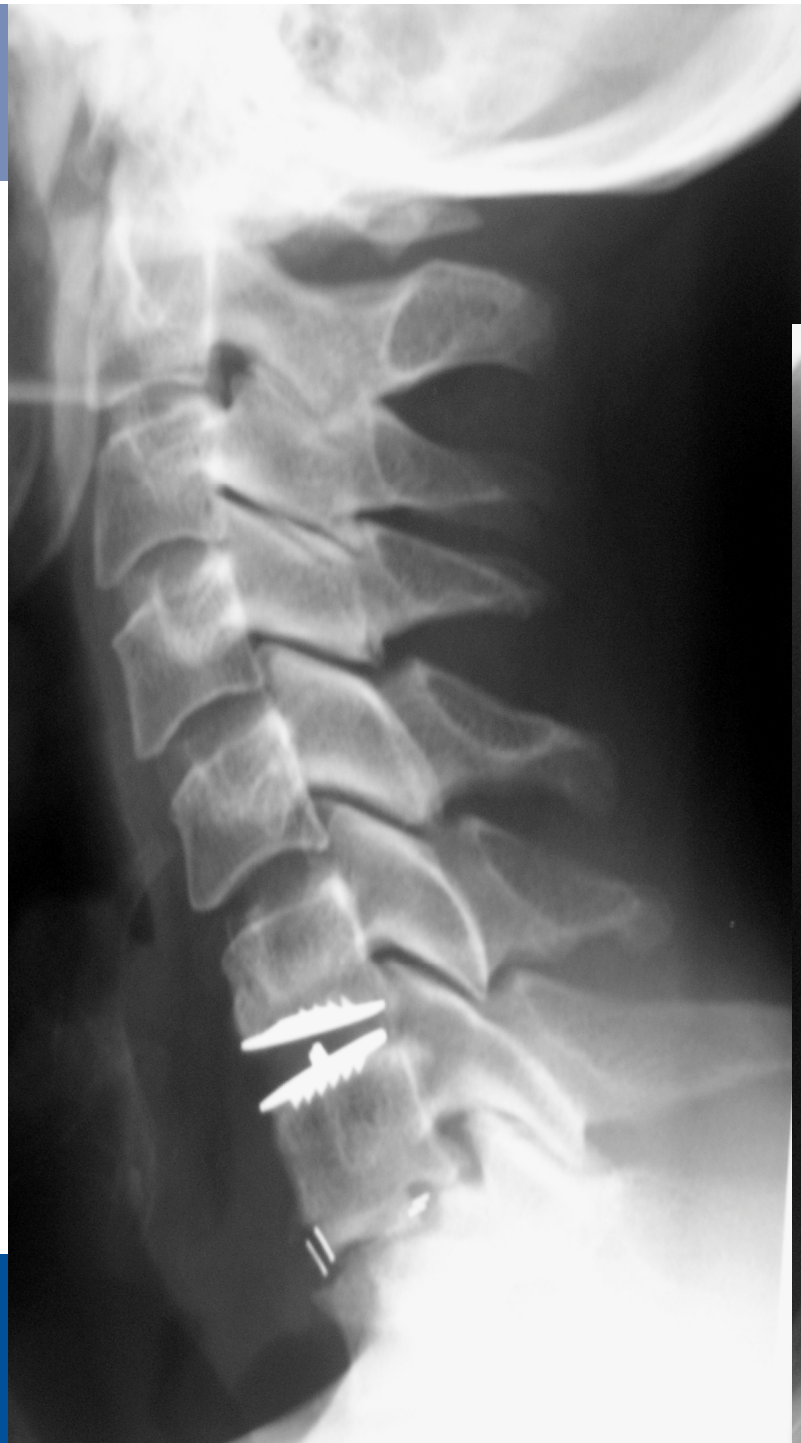


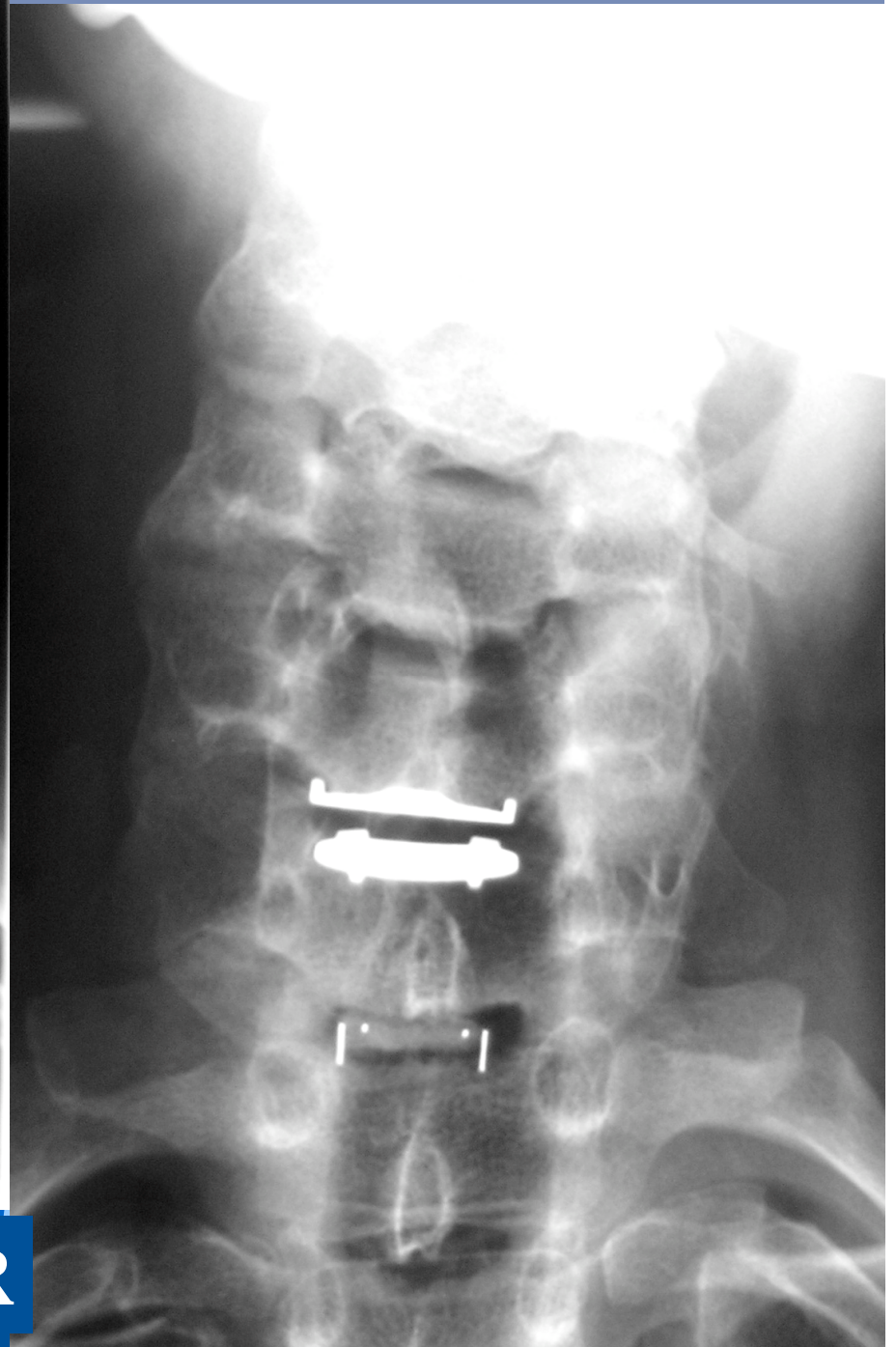
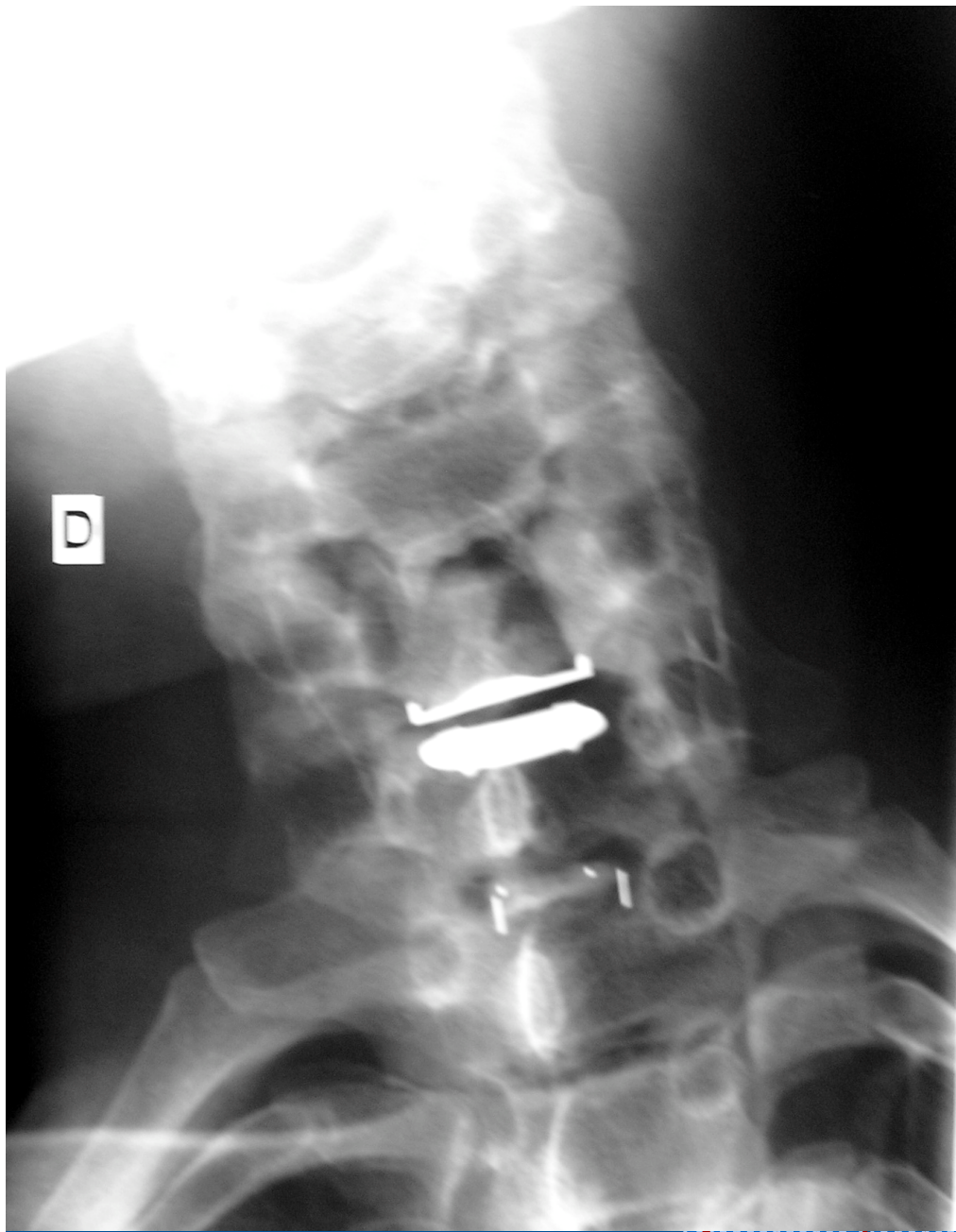**C6-C7**



**C7-T1**

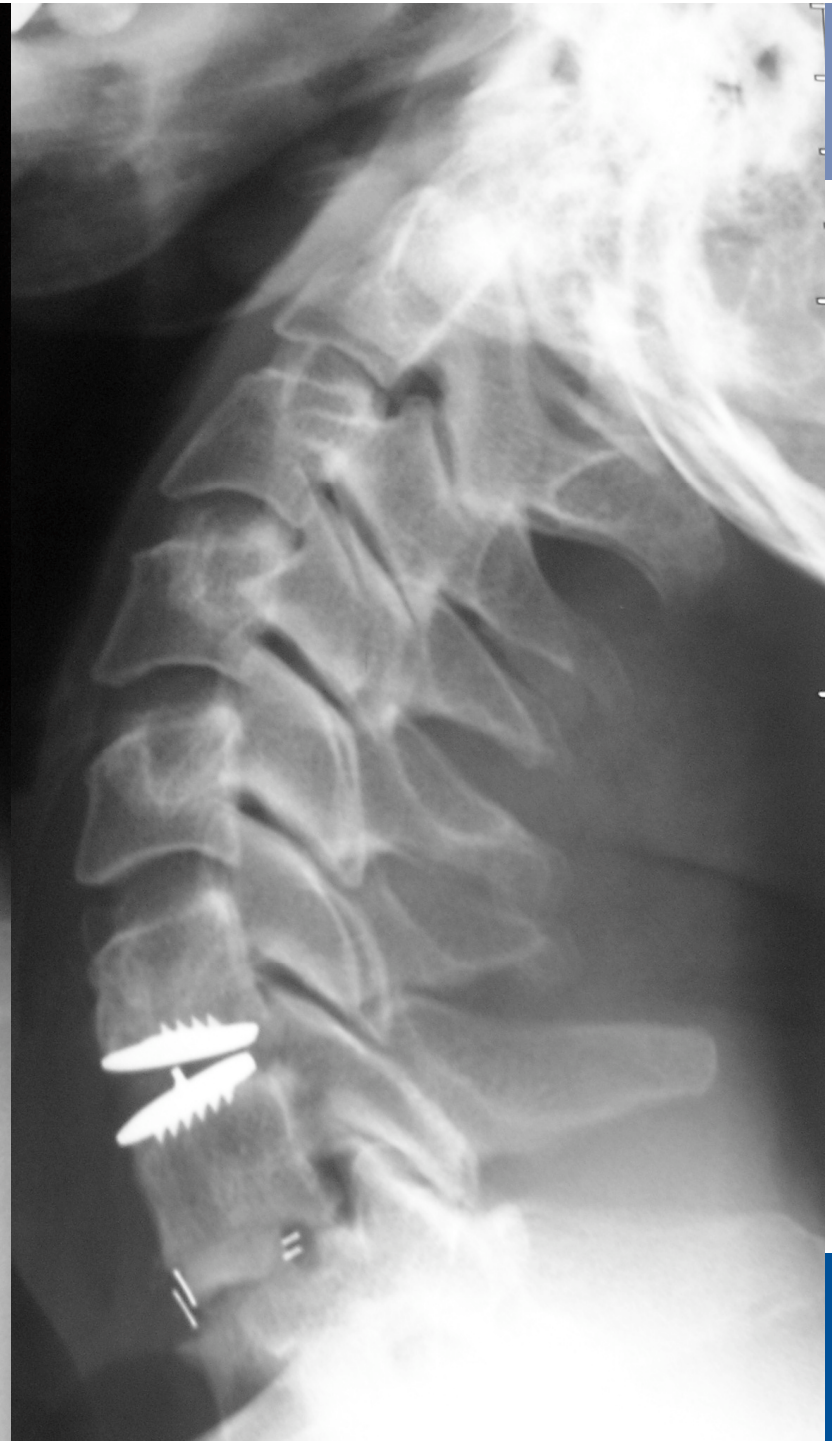
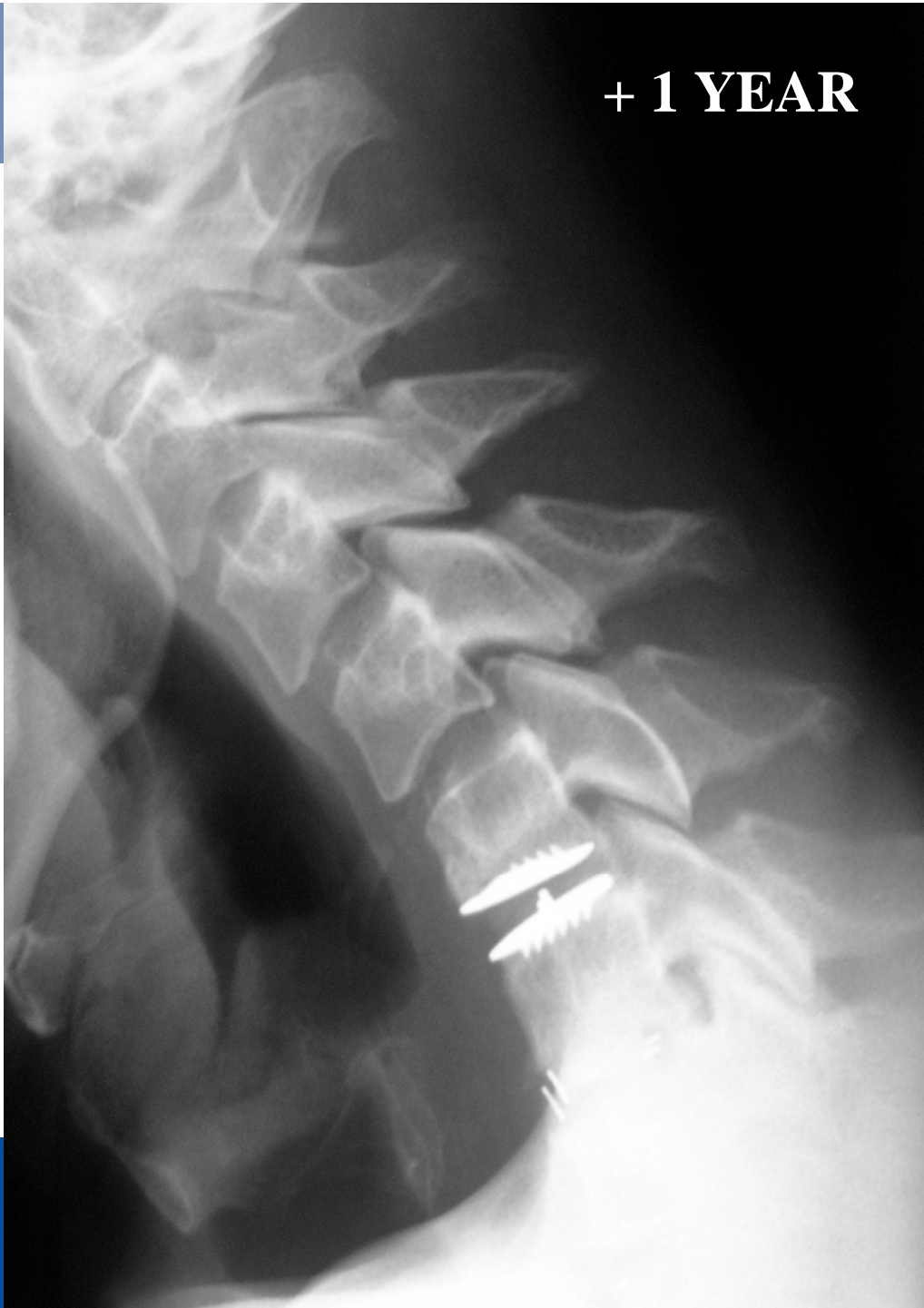




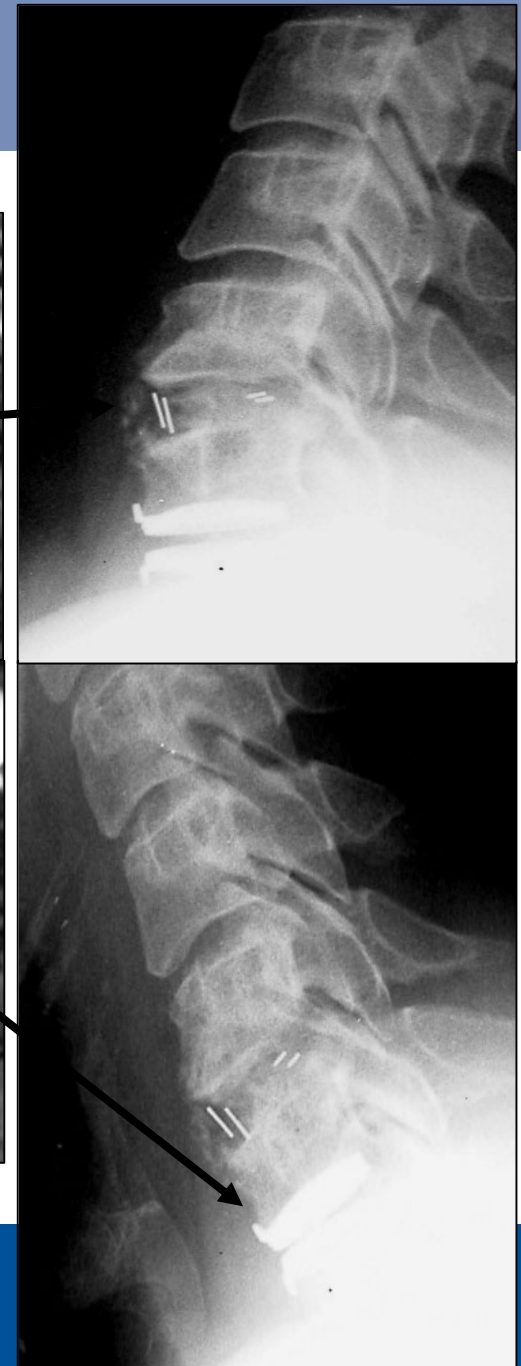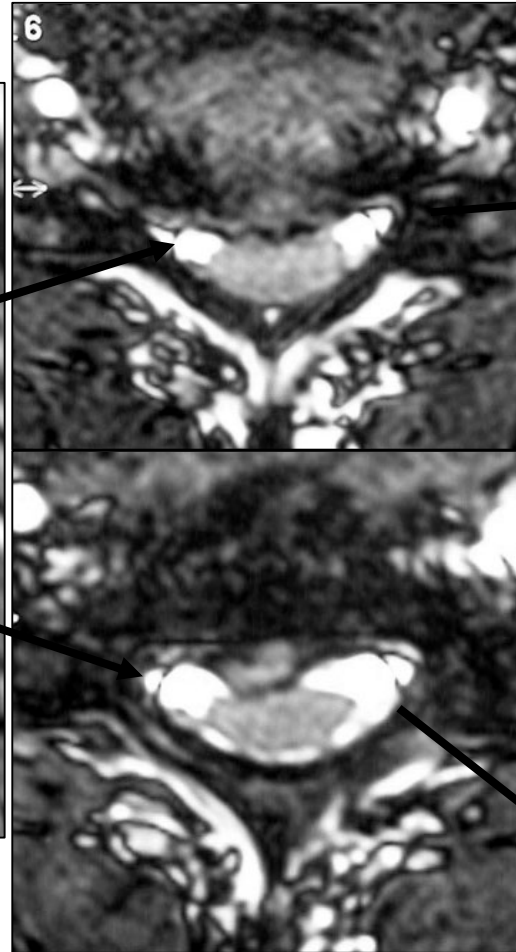
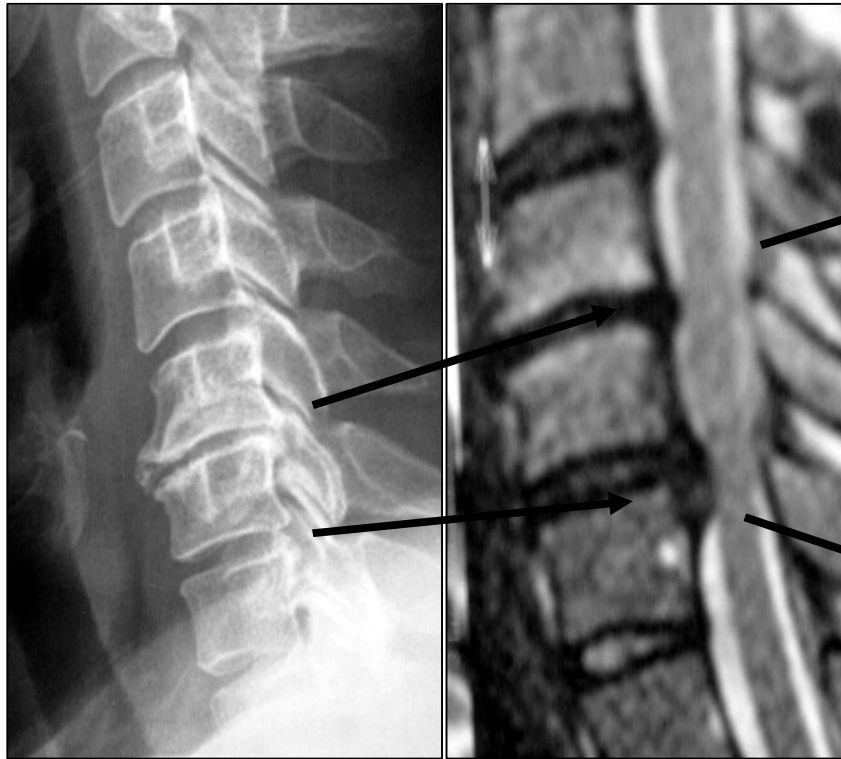
+ 1 YEAR

**+ 1 YEAR**





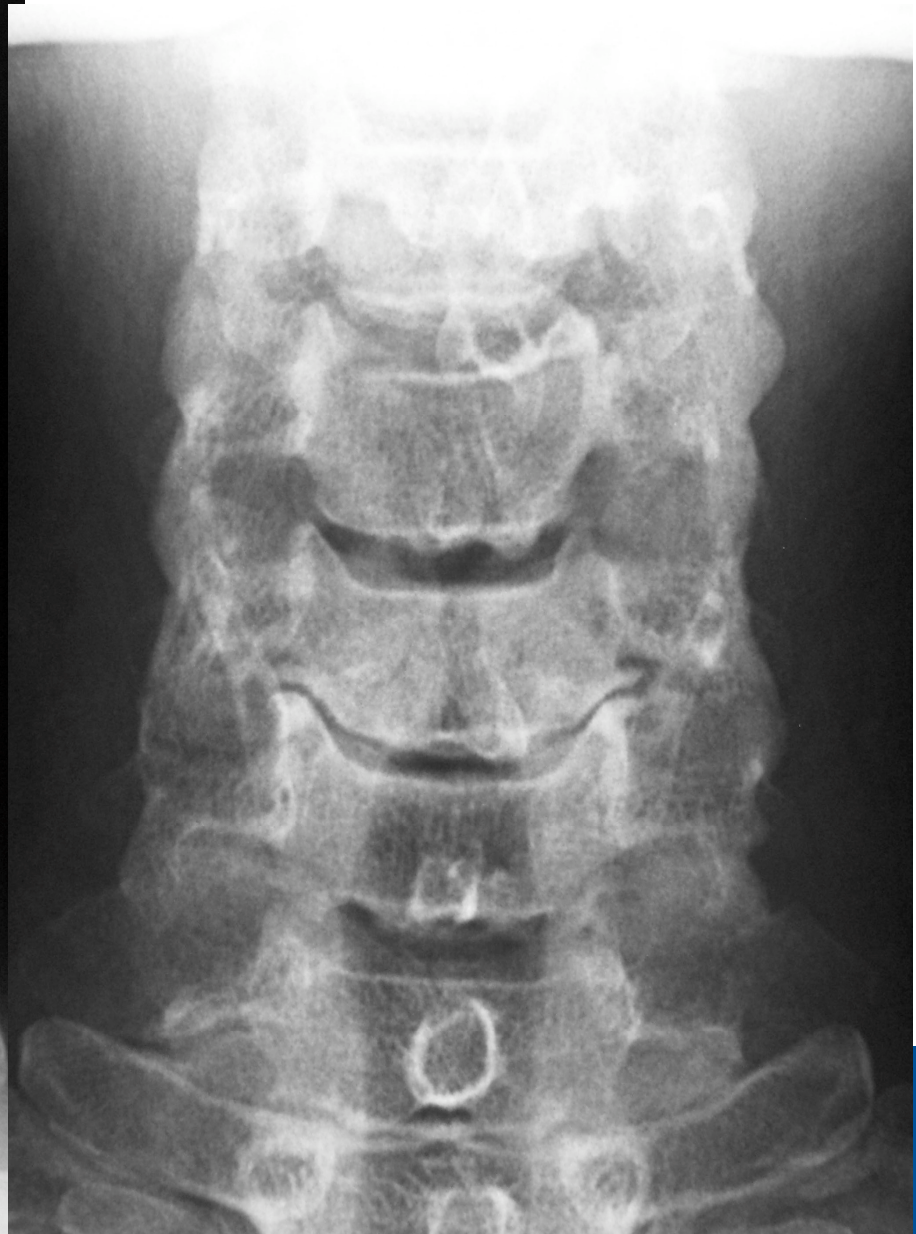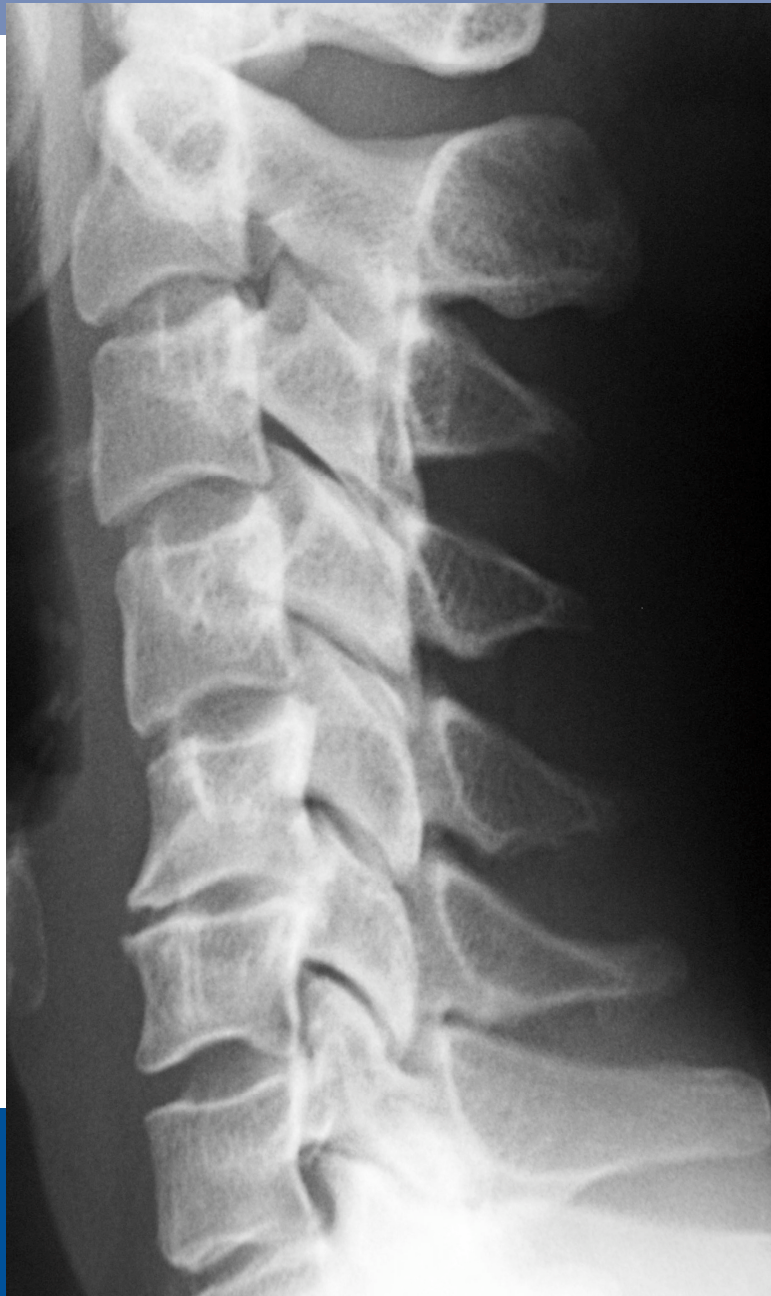# CAGE



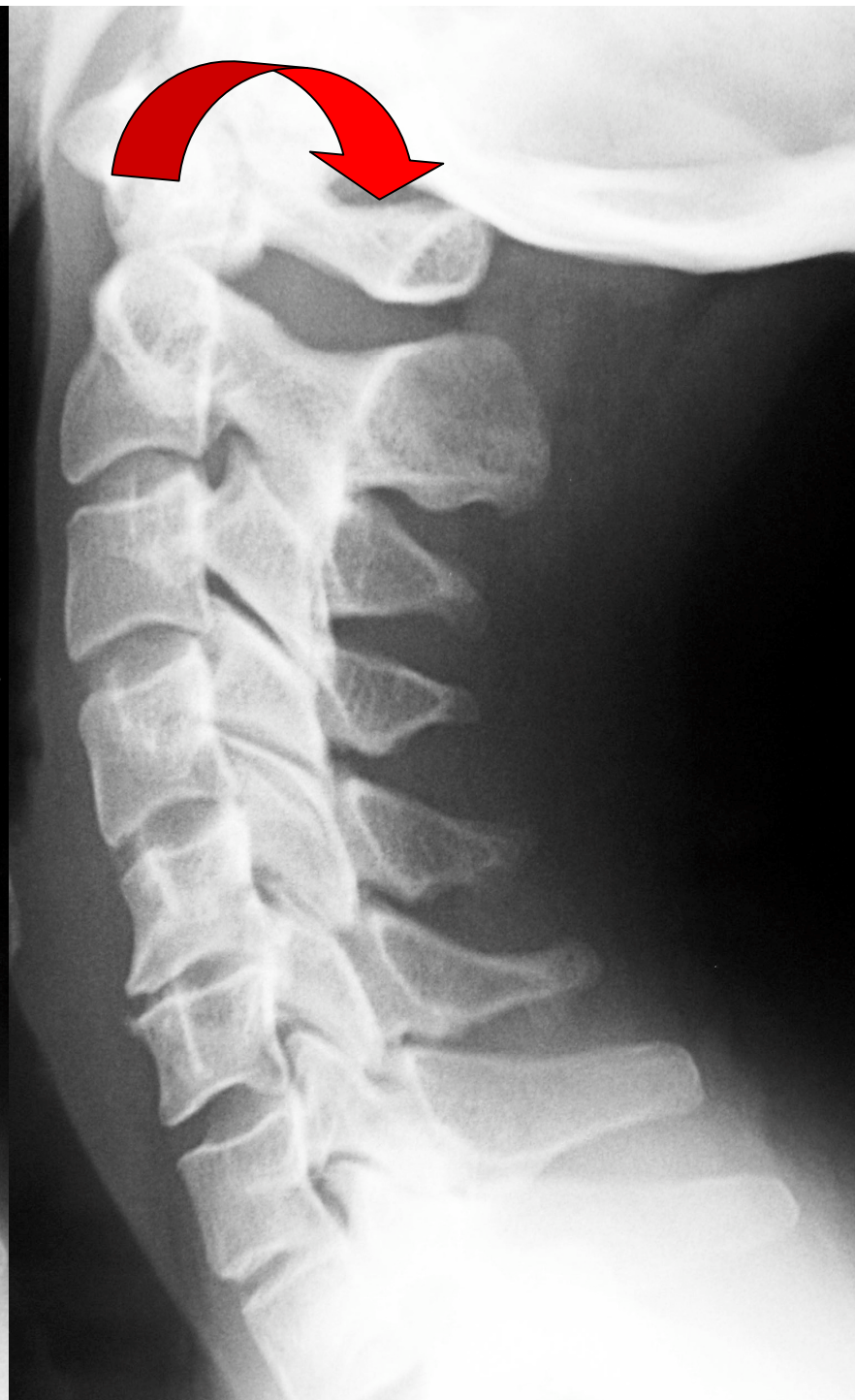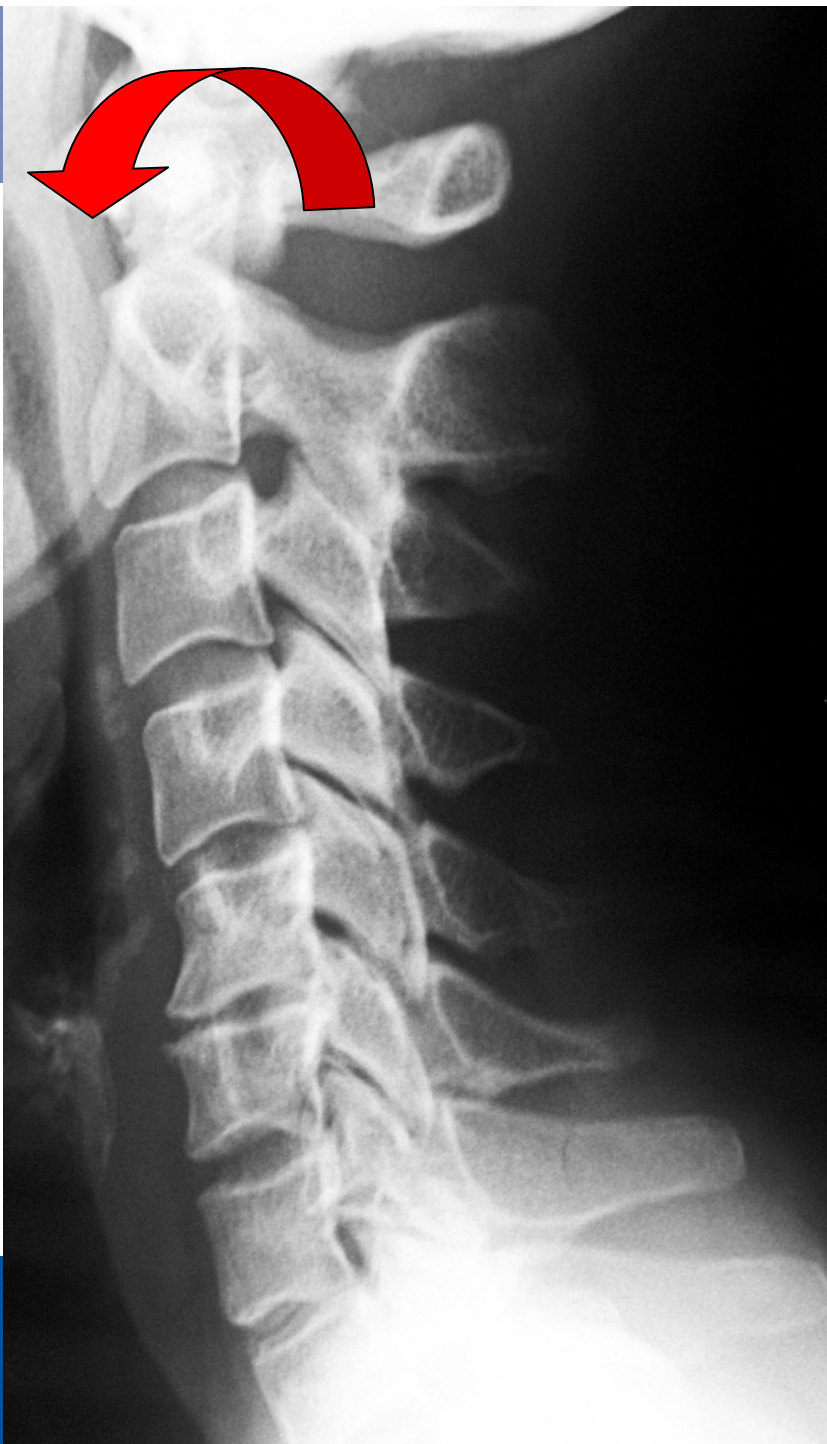# PROTHESIS

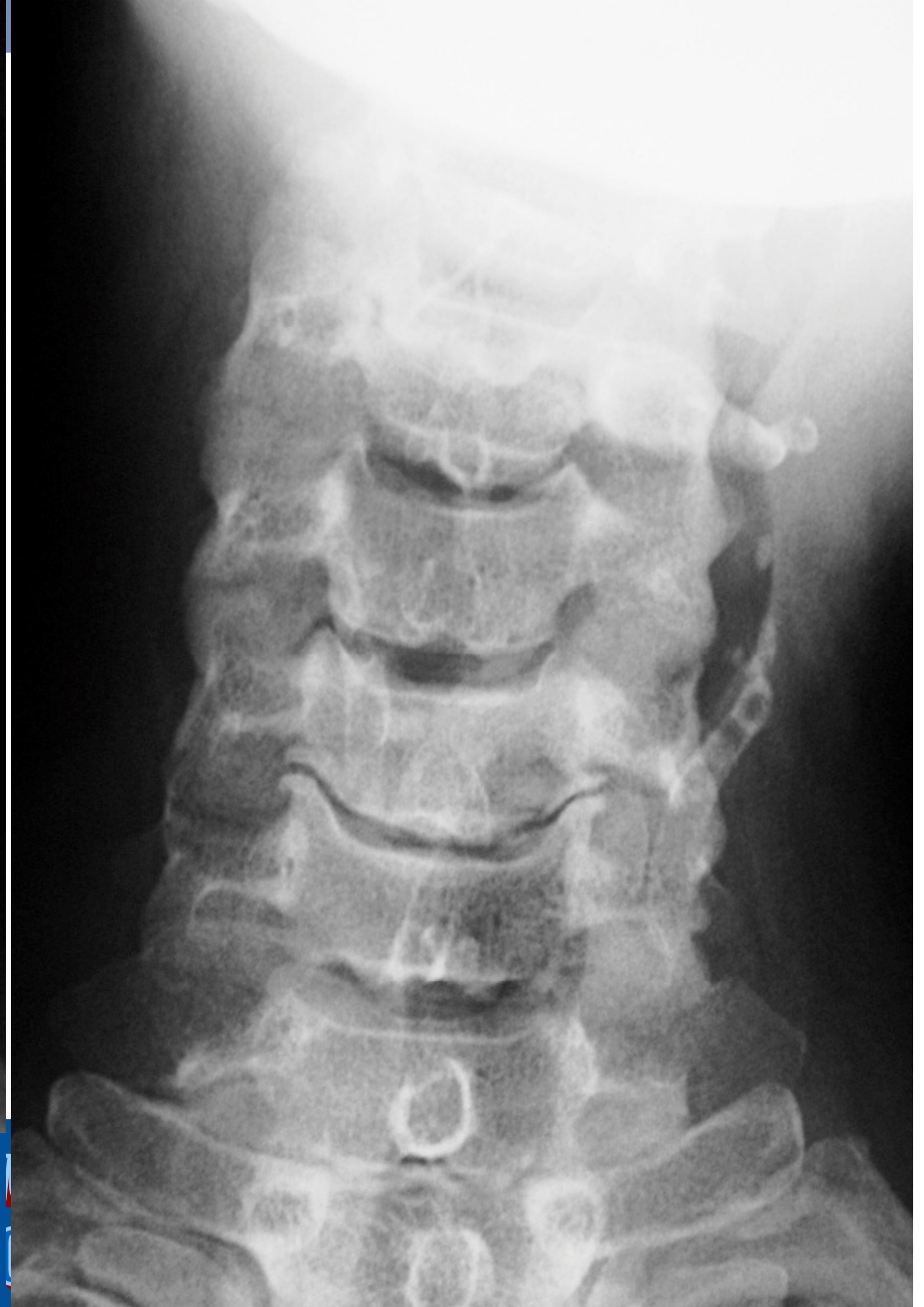
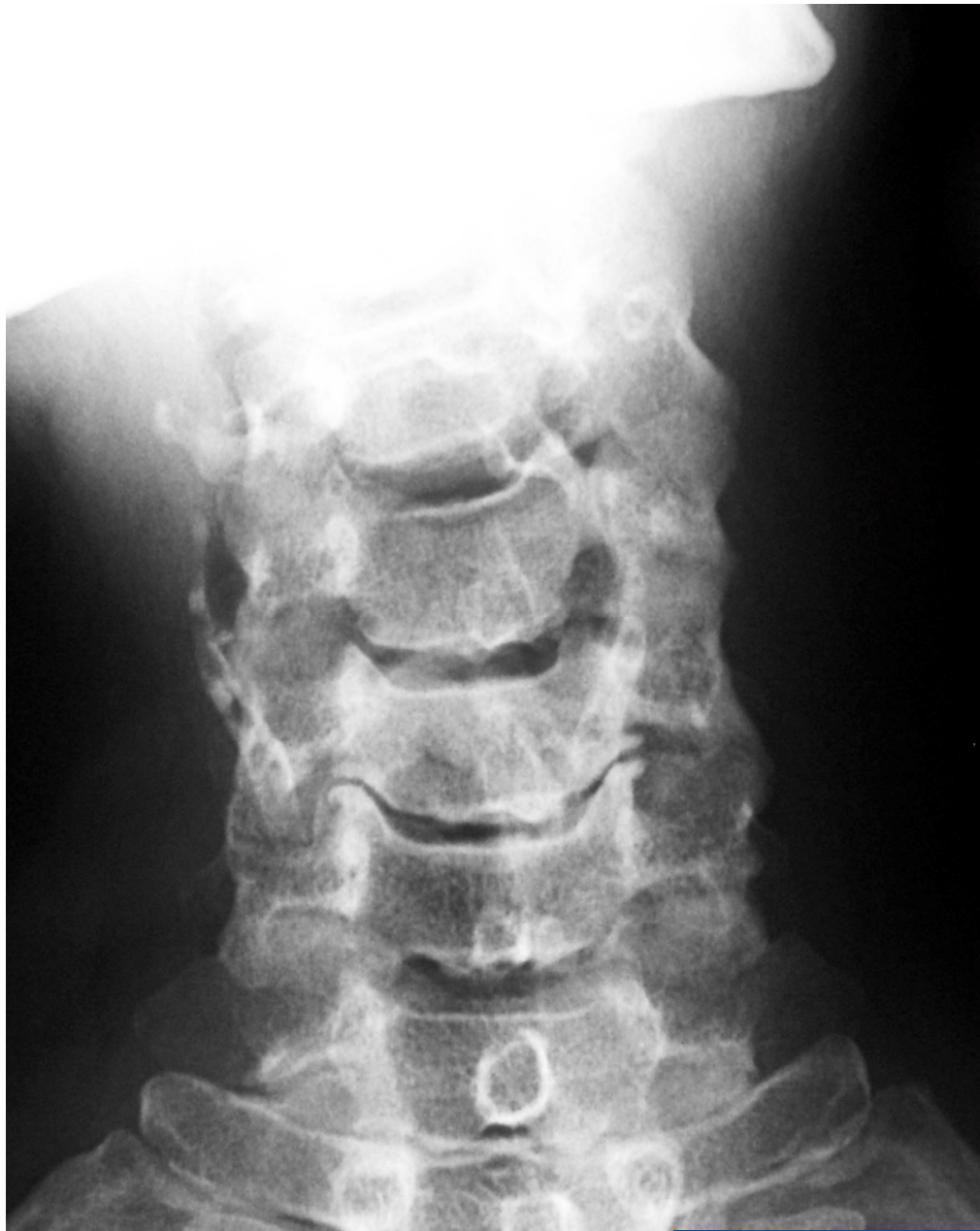
**Female , 37 y , bilateral cervicobrachialgia , Hoffman sign**



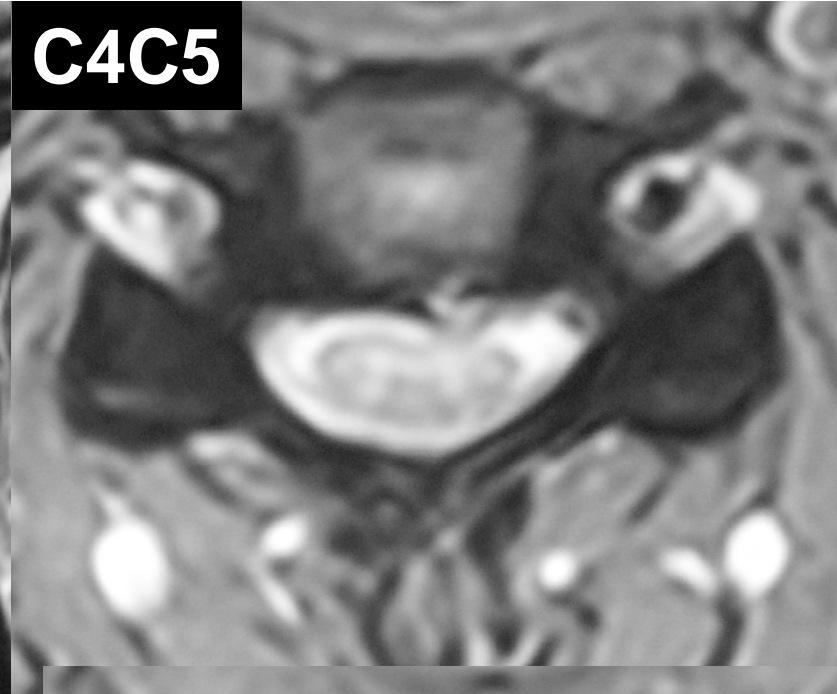




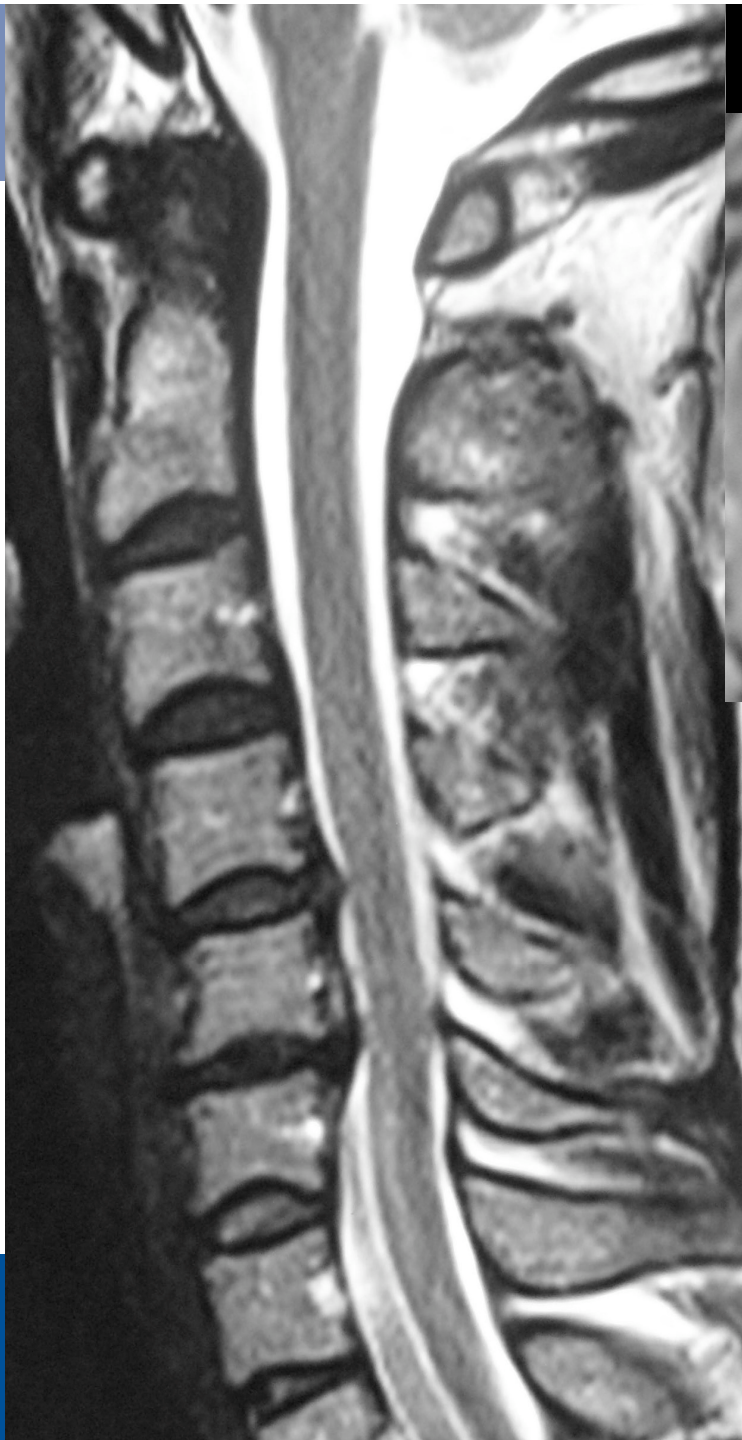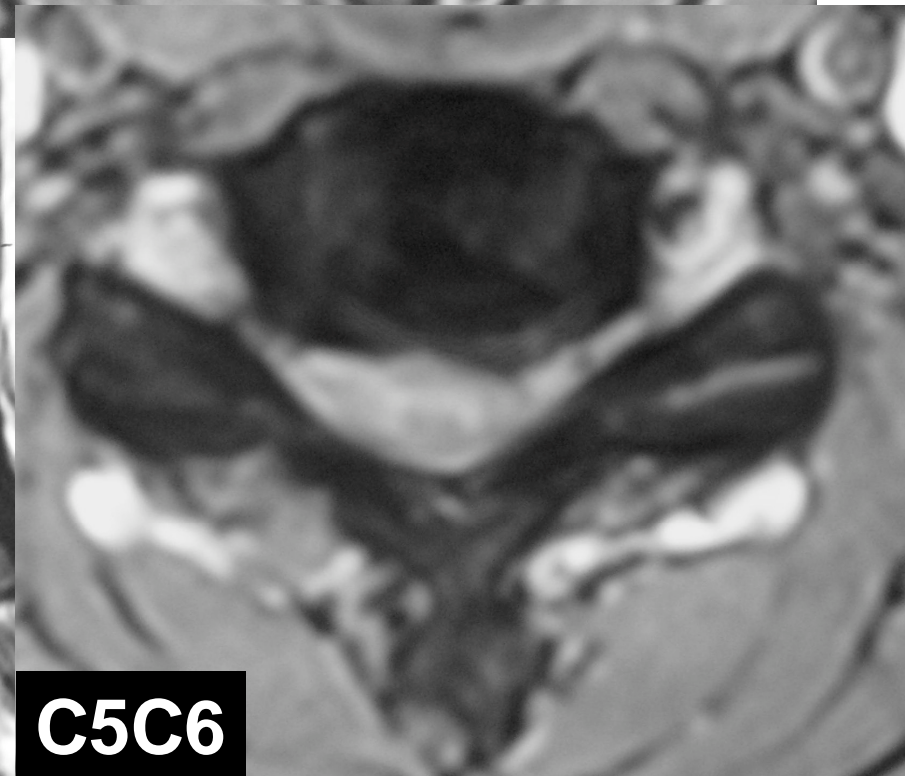


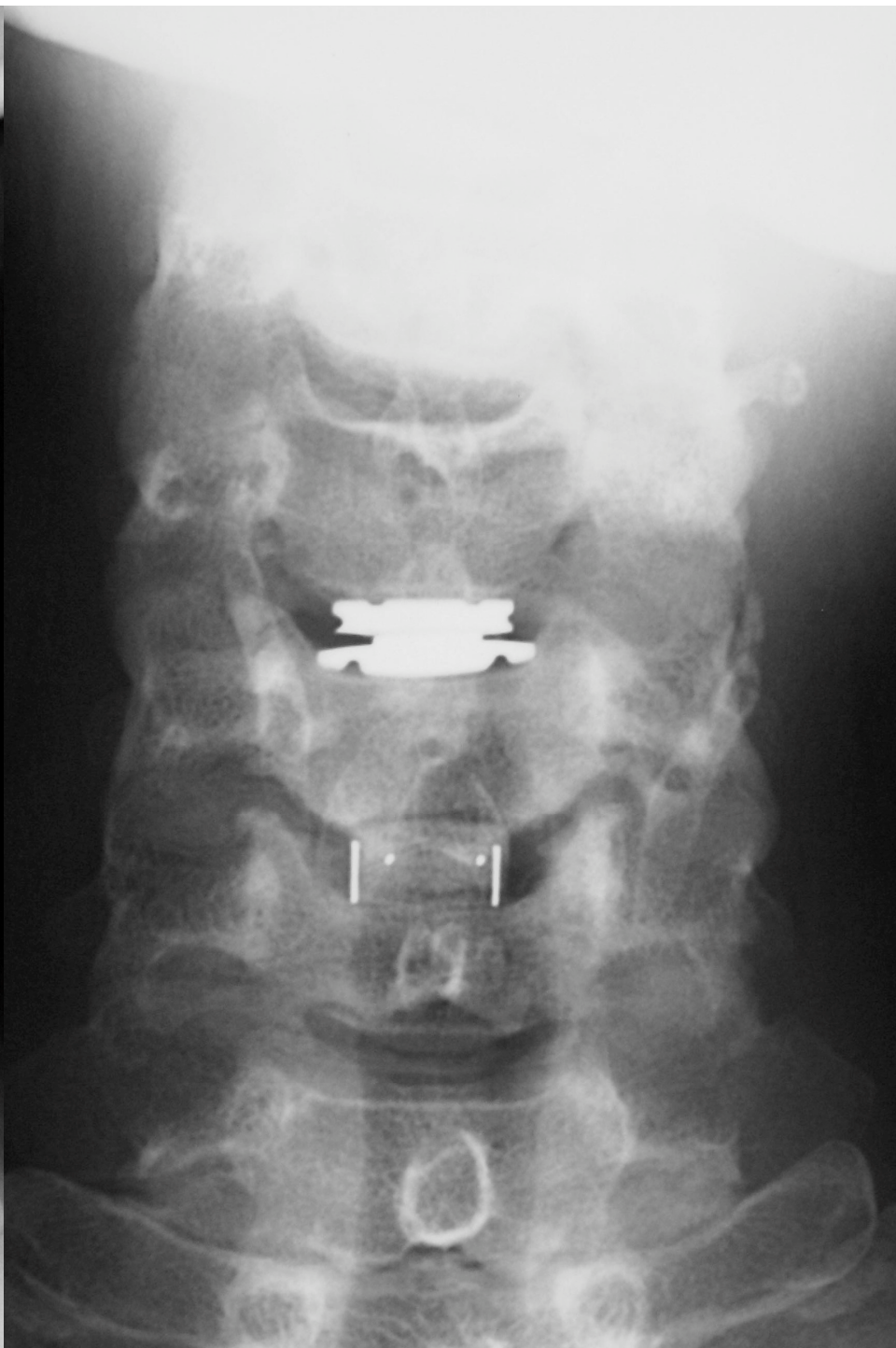

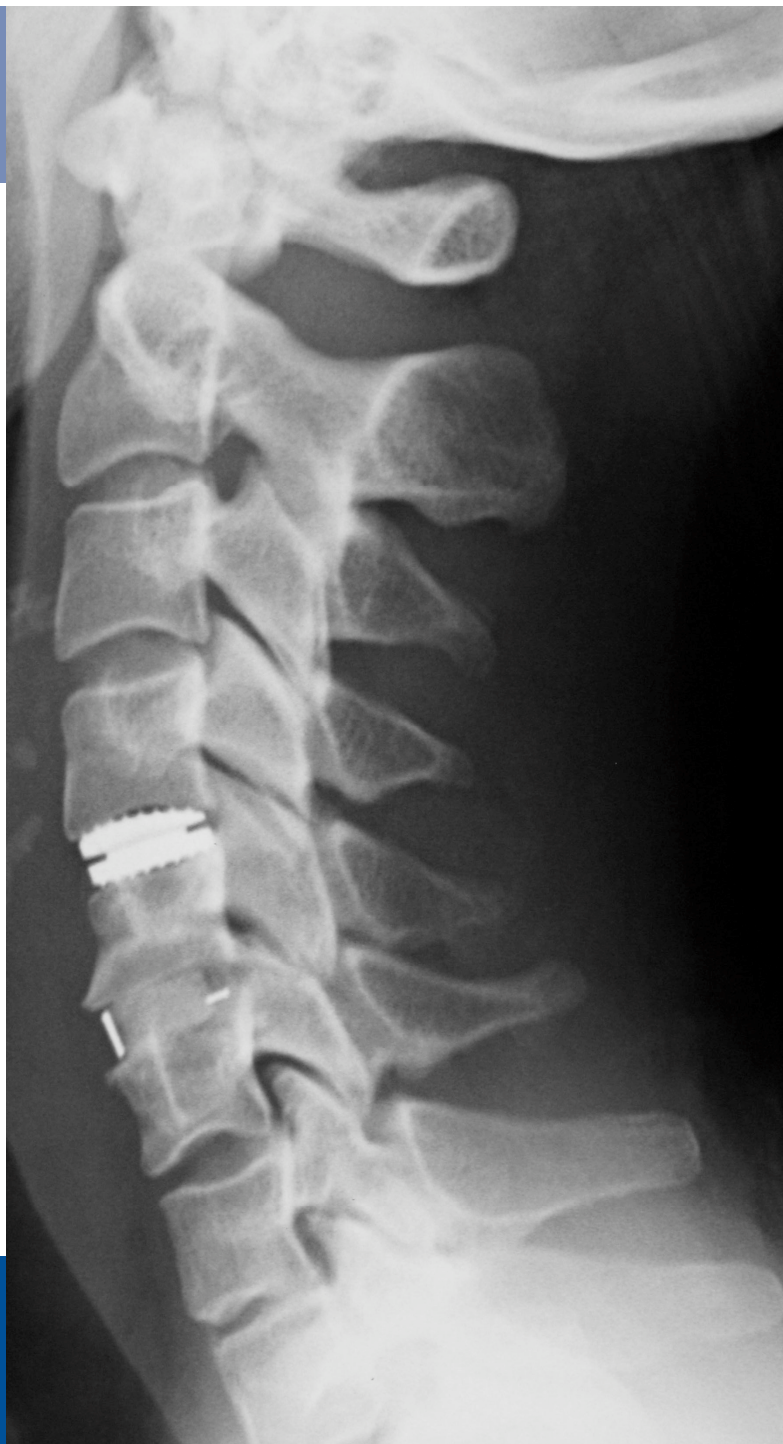
**C4C5**

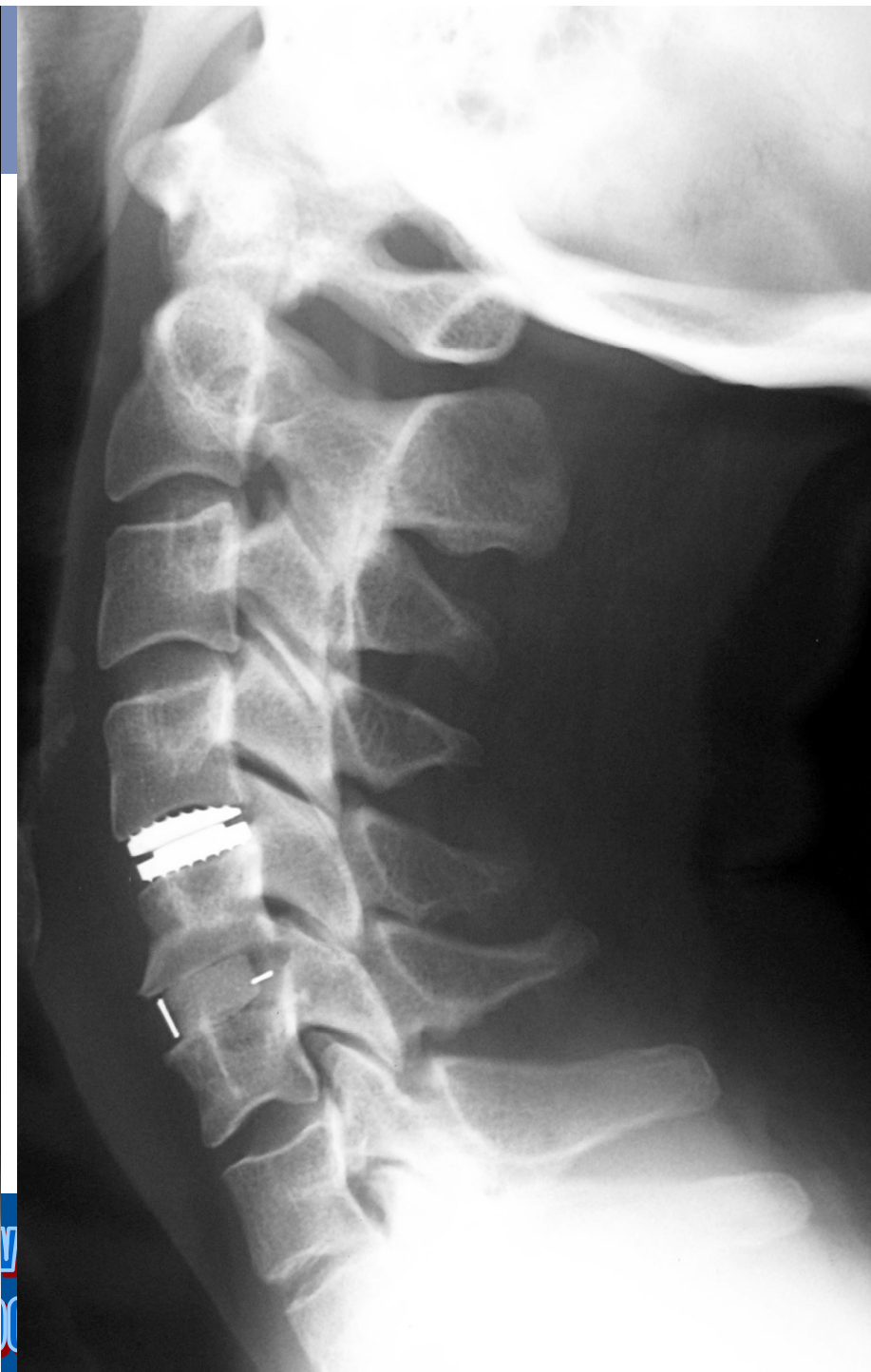
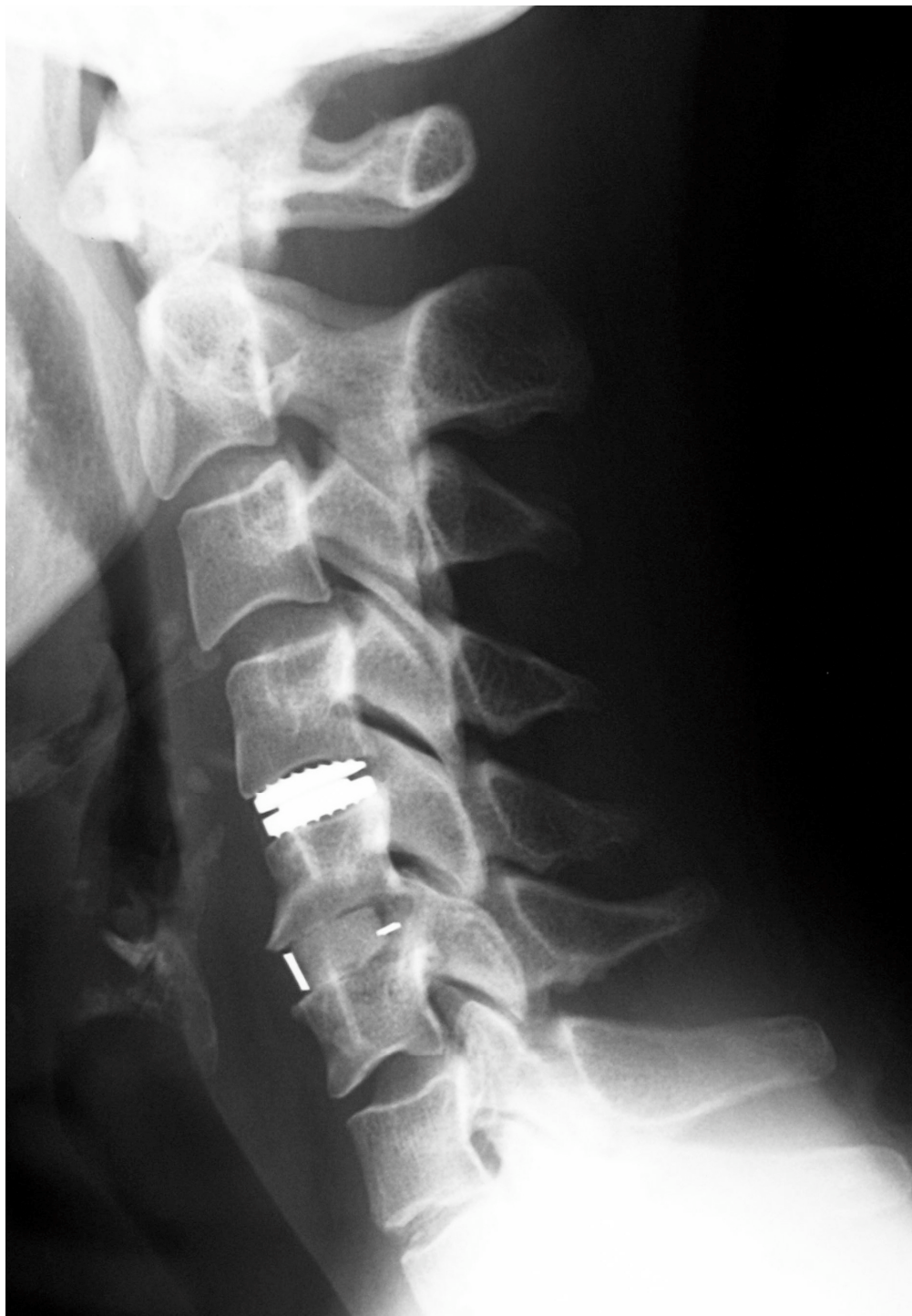


**C5C6**

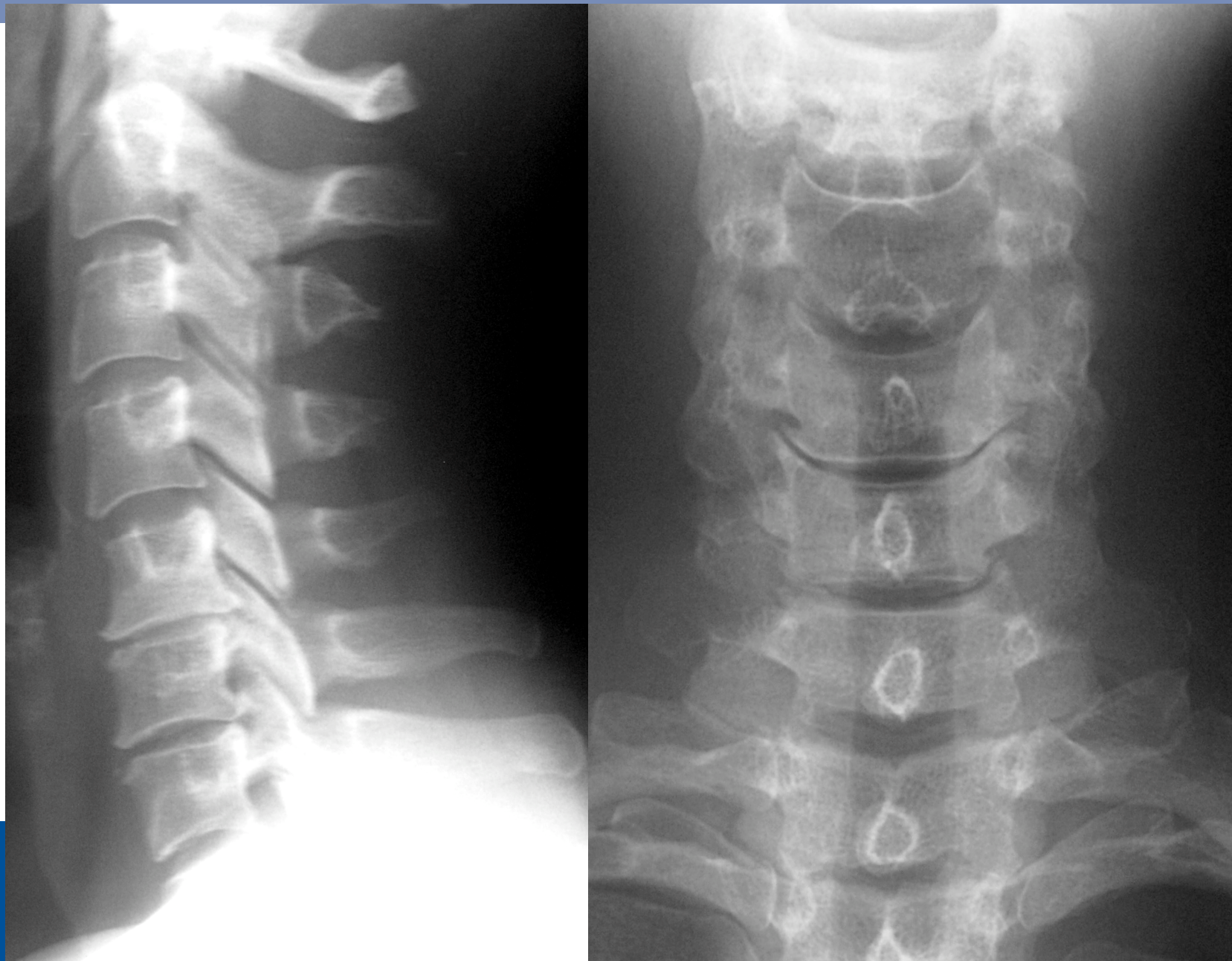








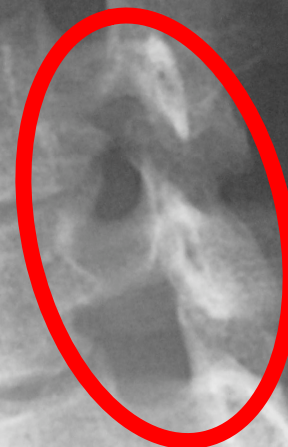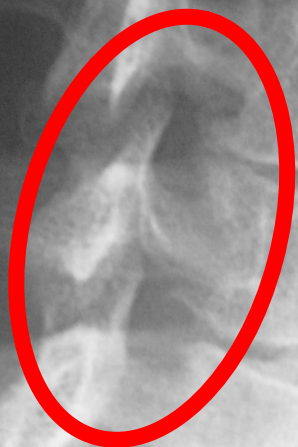# Female , 40 y , rigth cervicobrachialgia



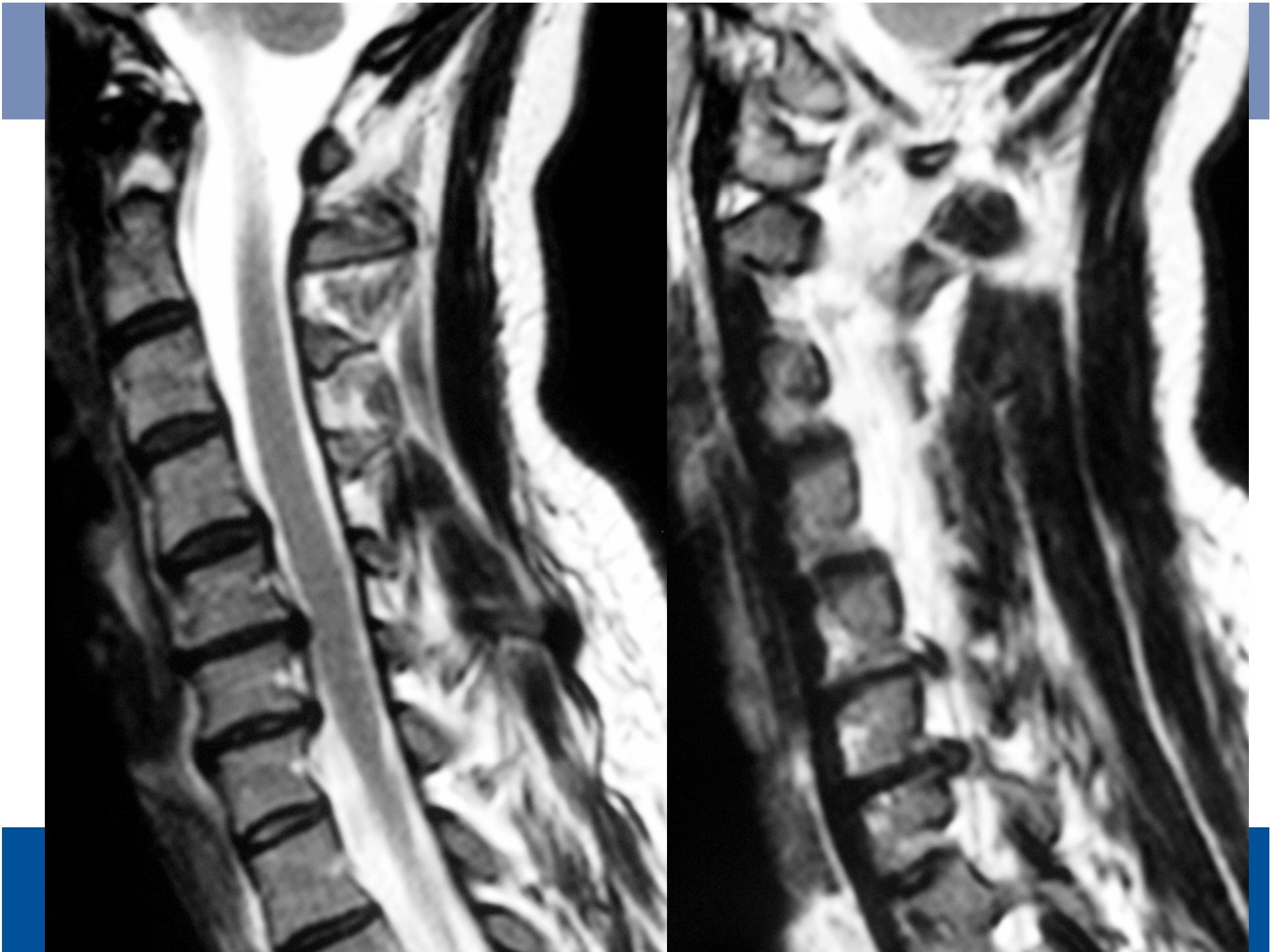


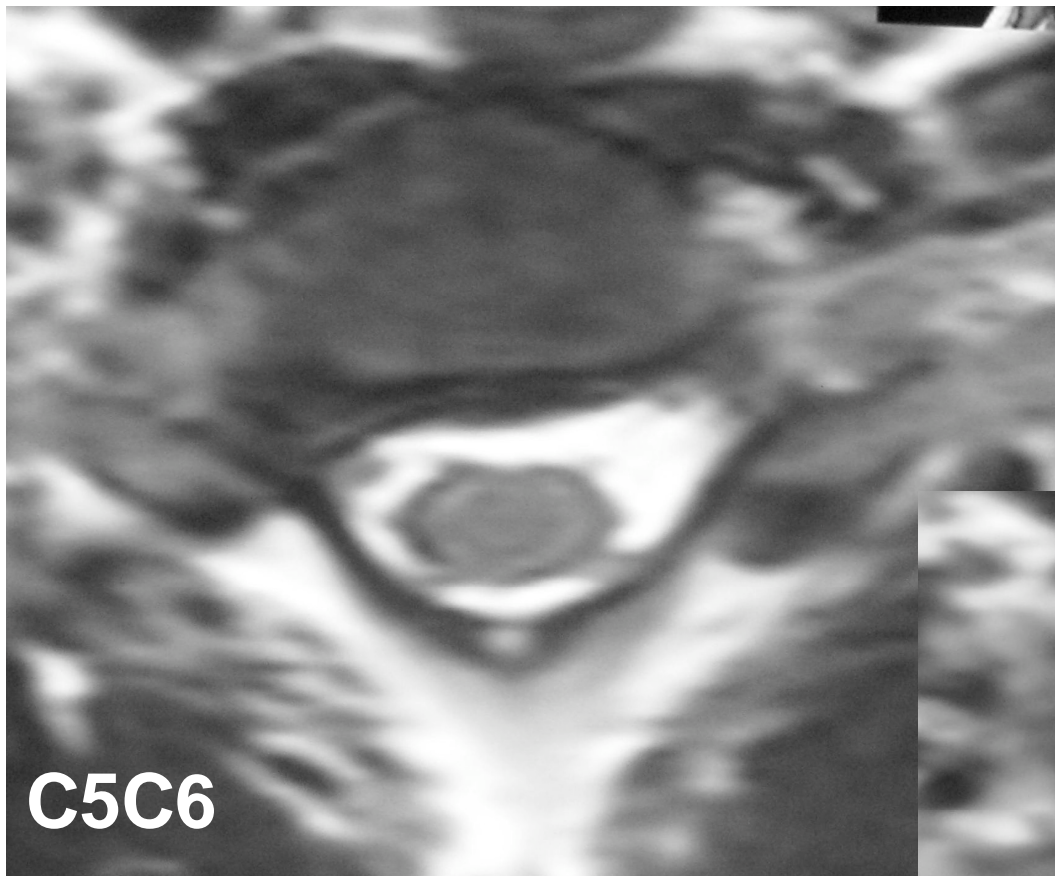
L

R

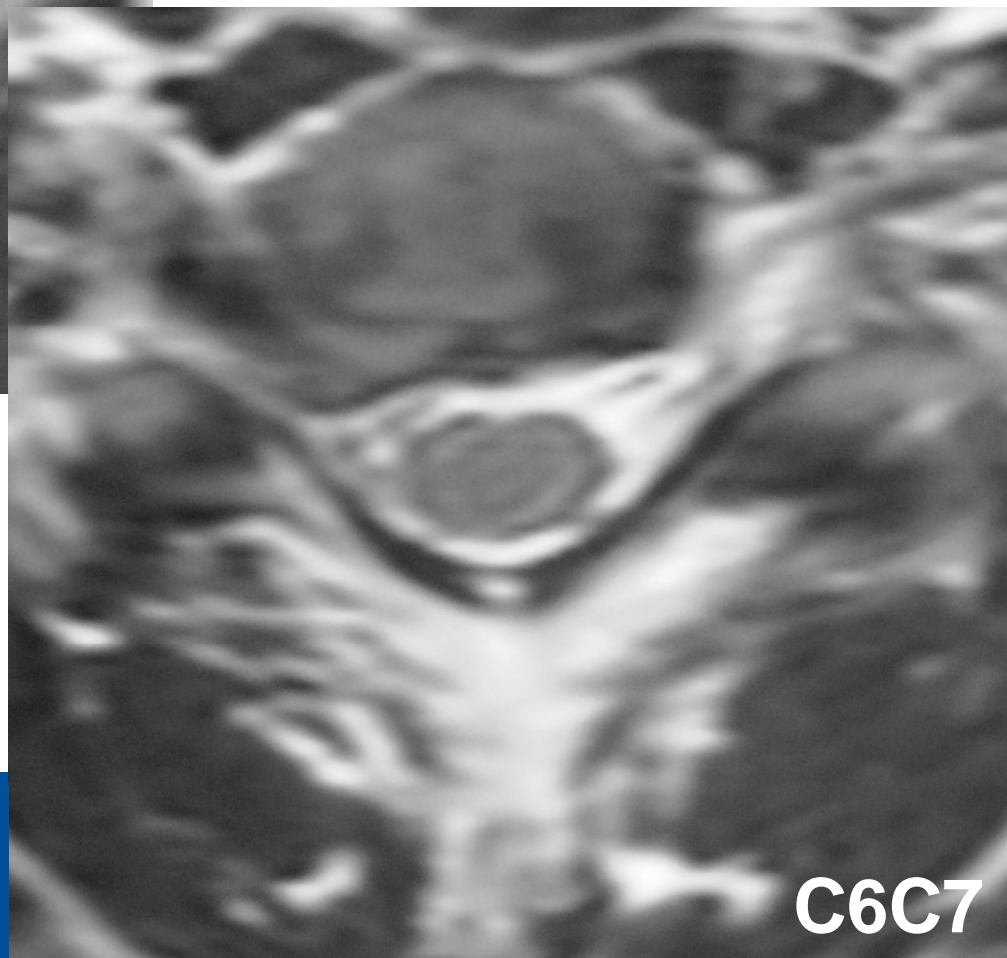






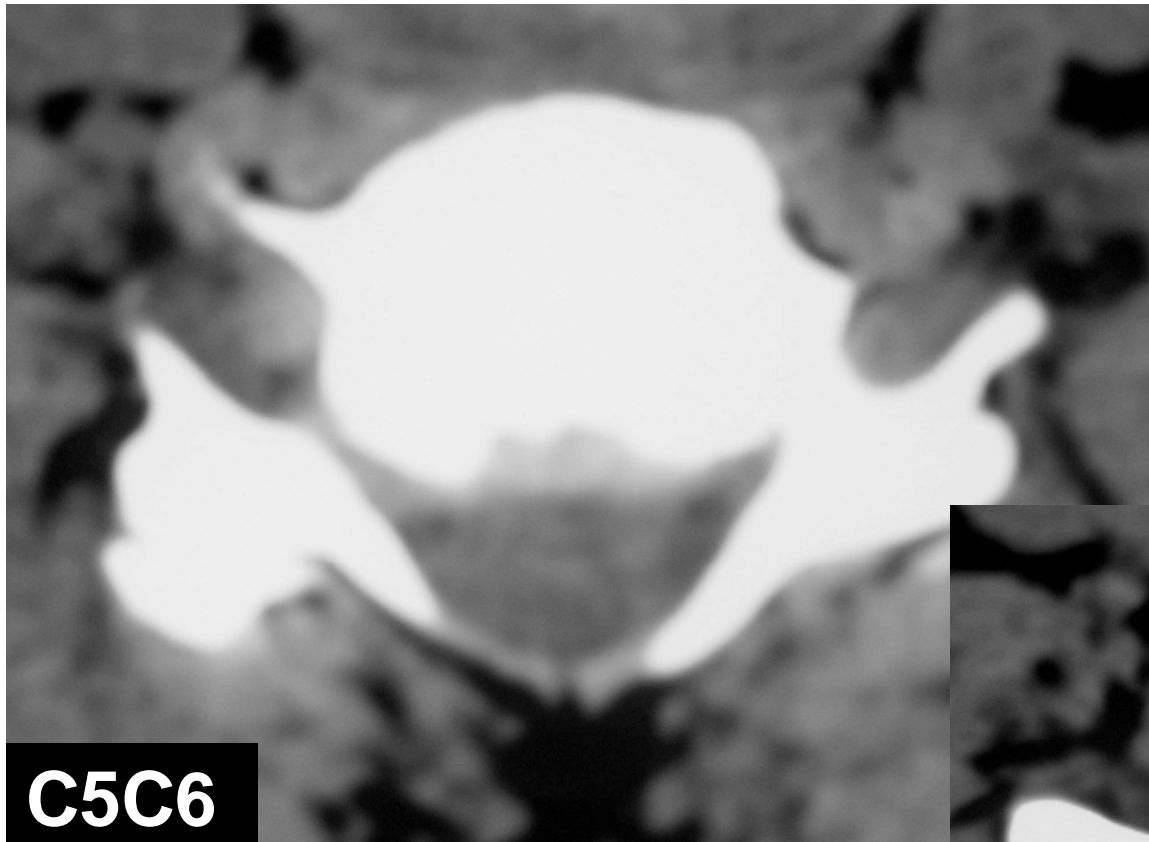


**C5C6**

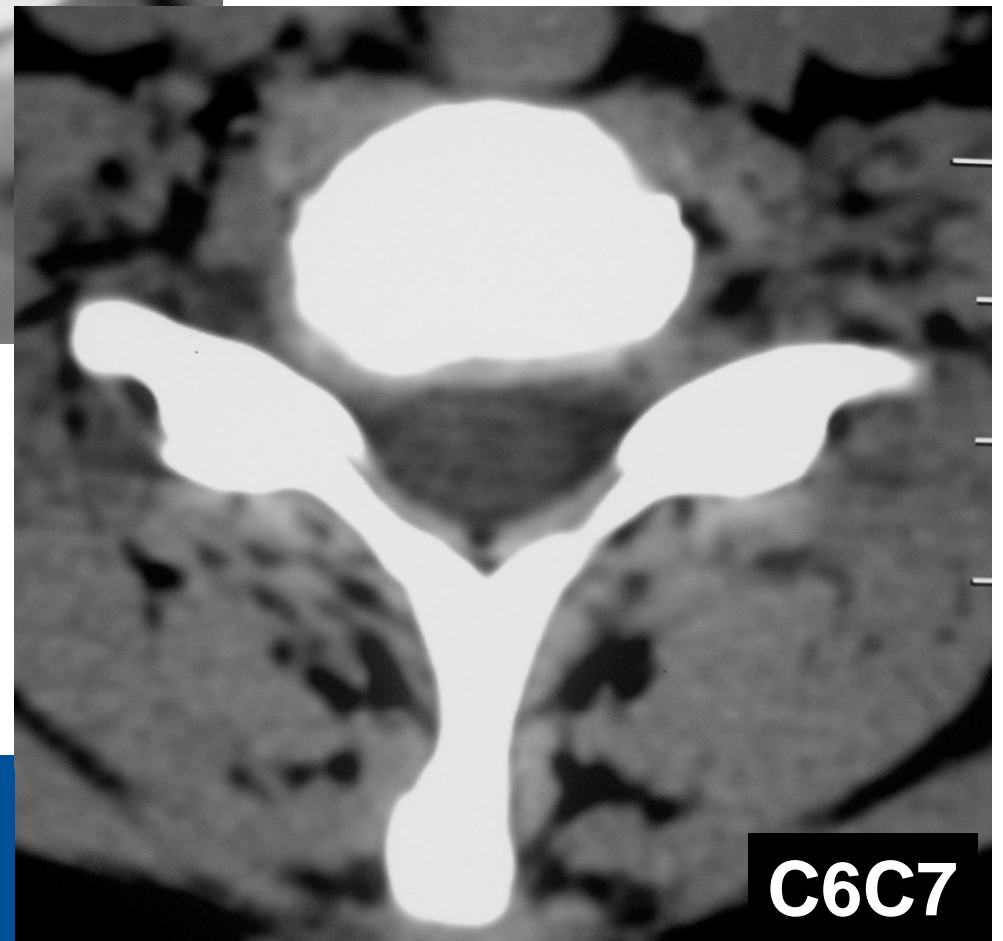


**C6C7**



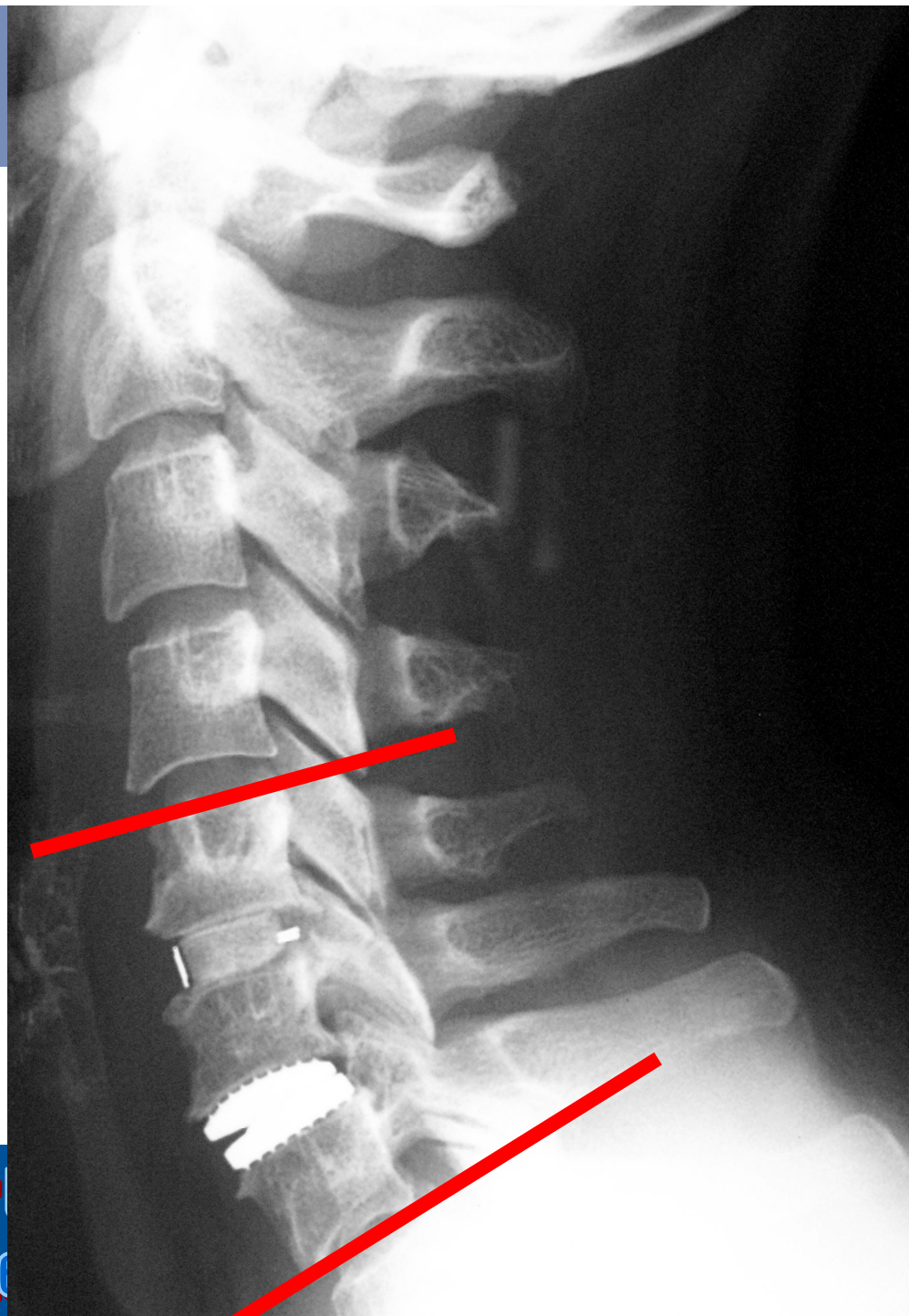
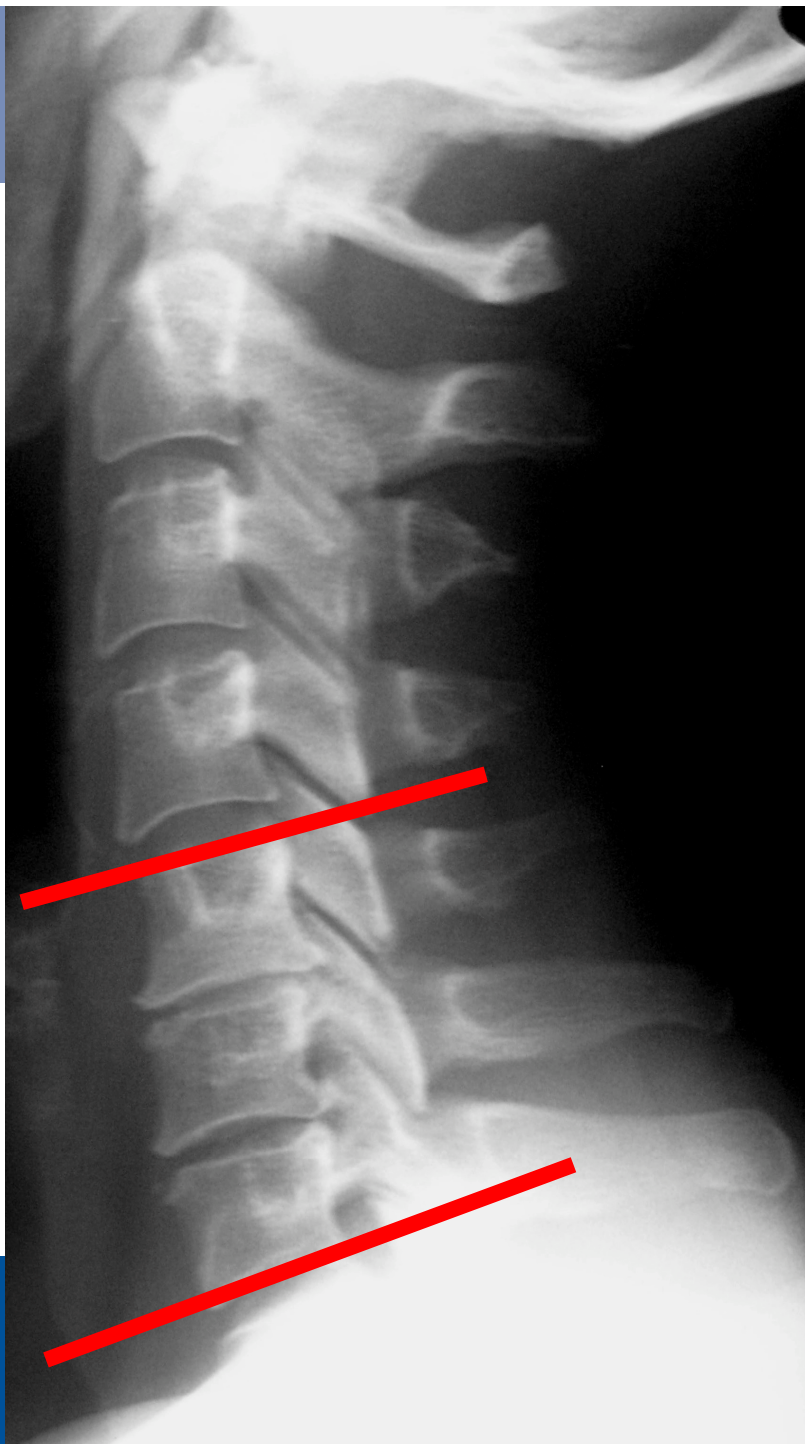

**C5C6**

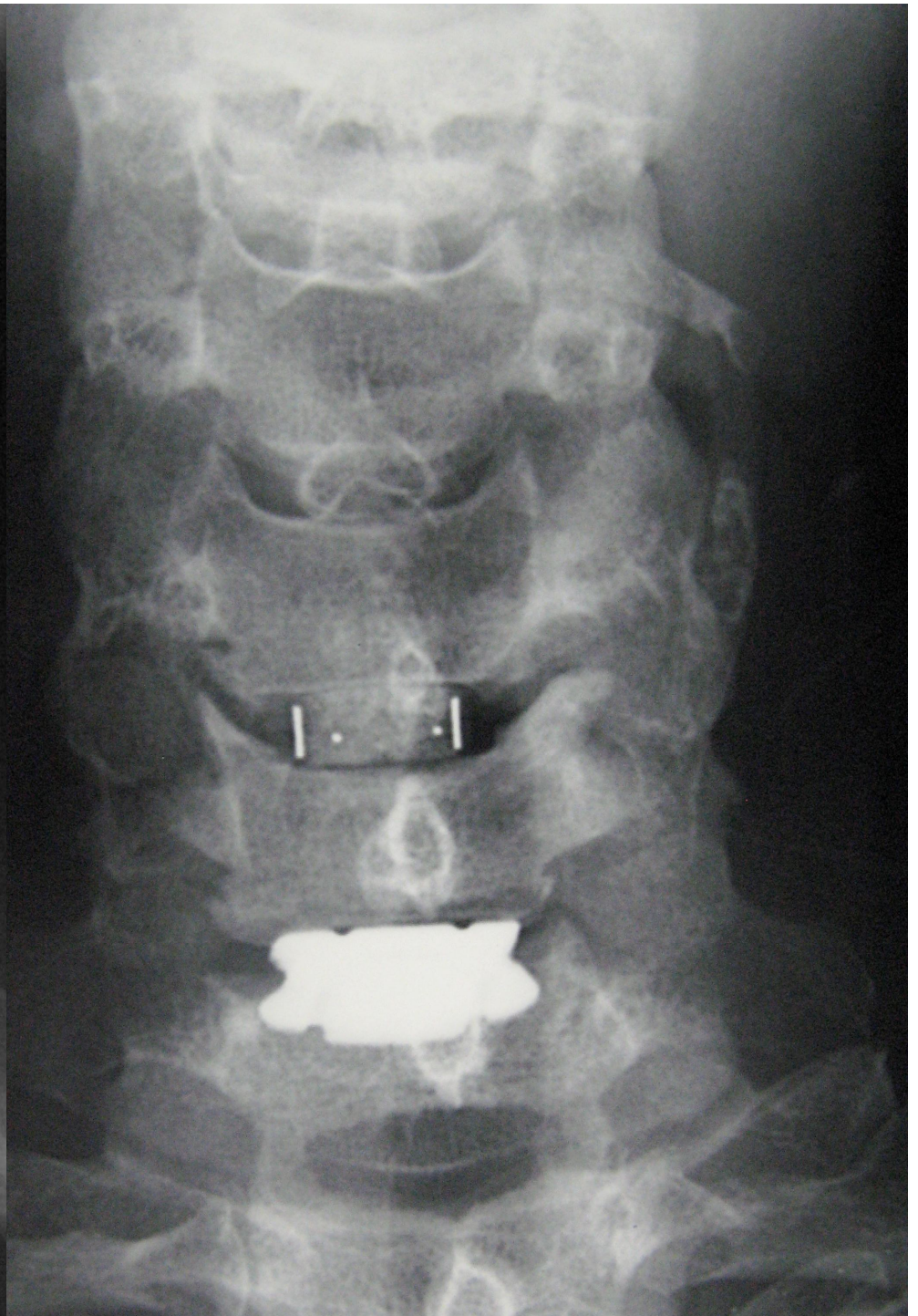
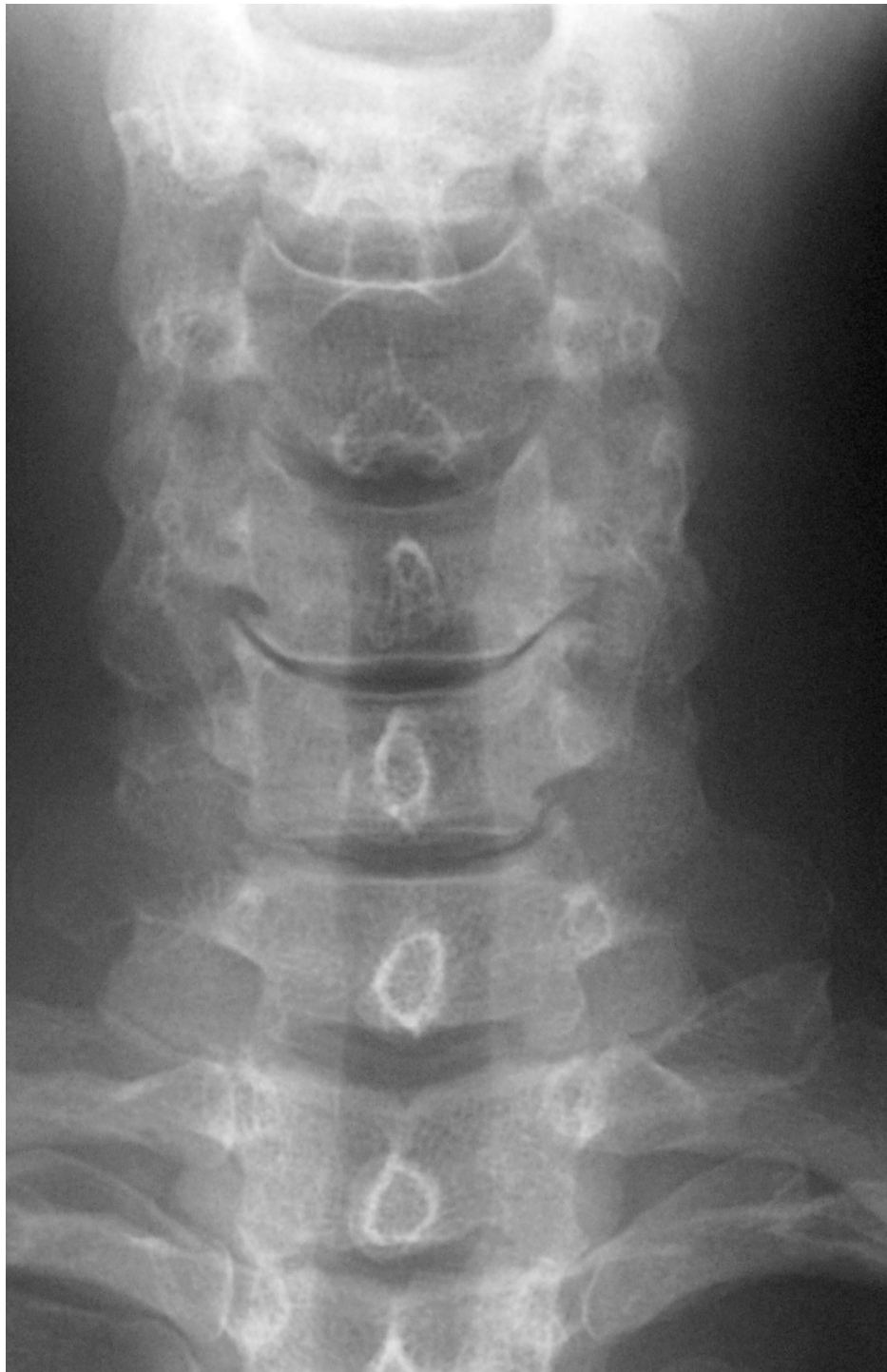
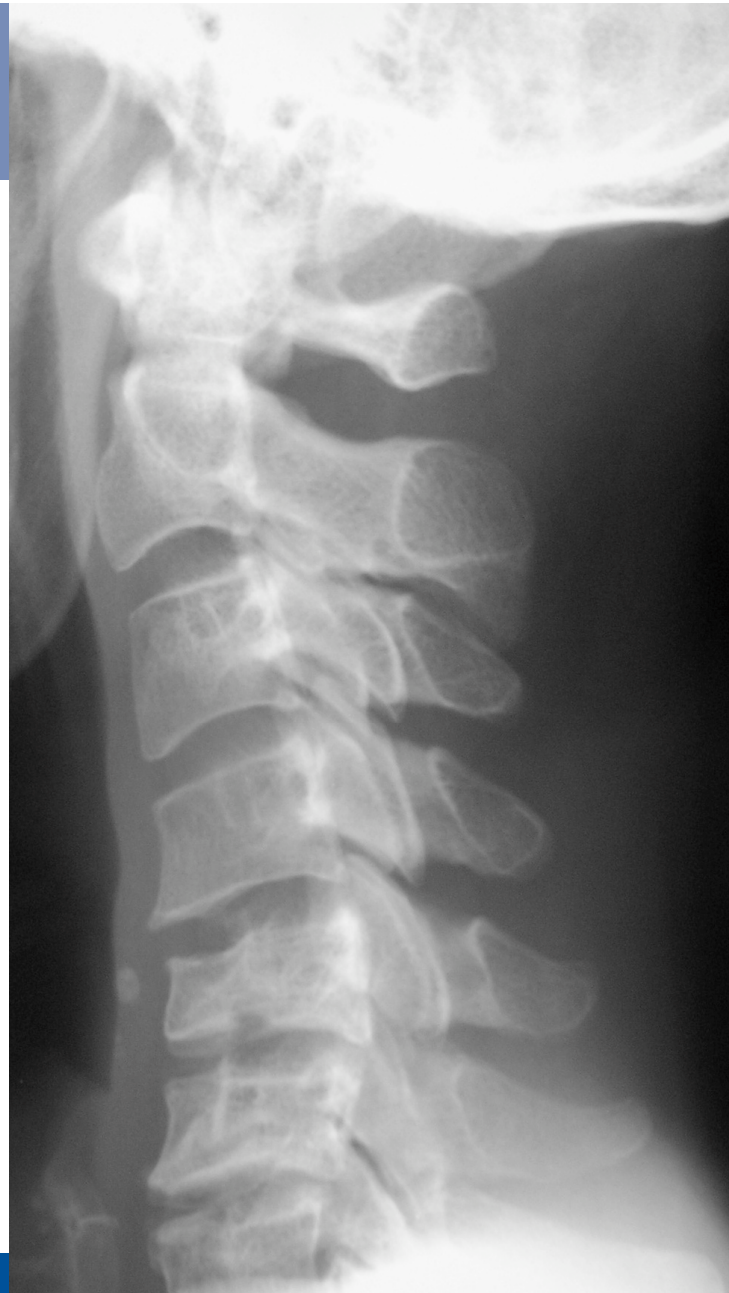**C6C7**





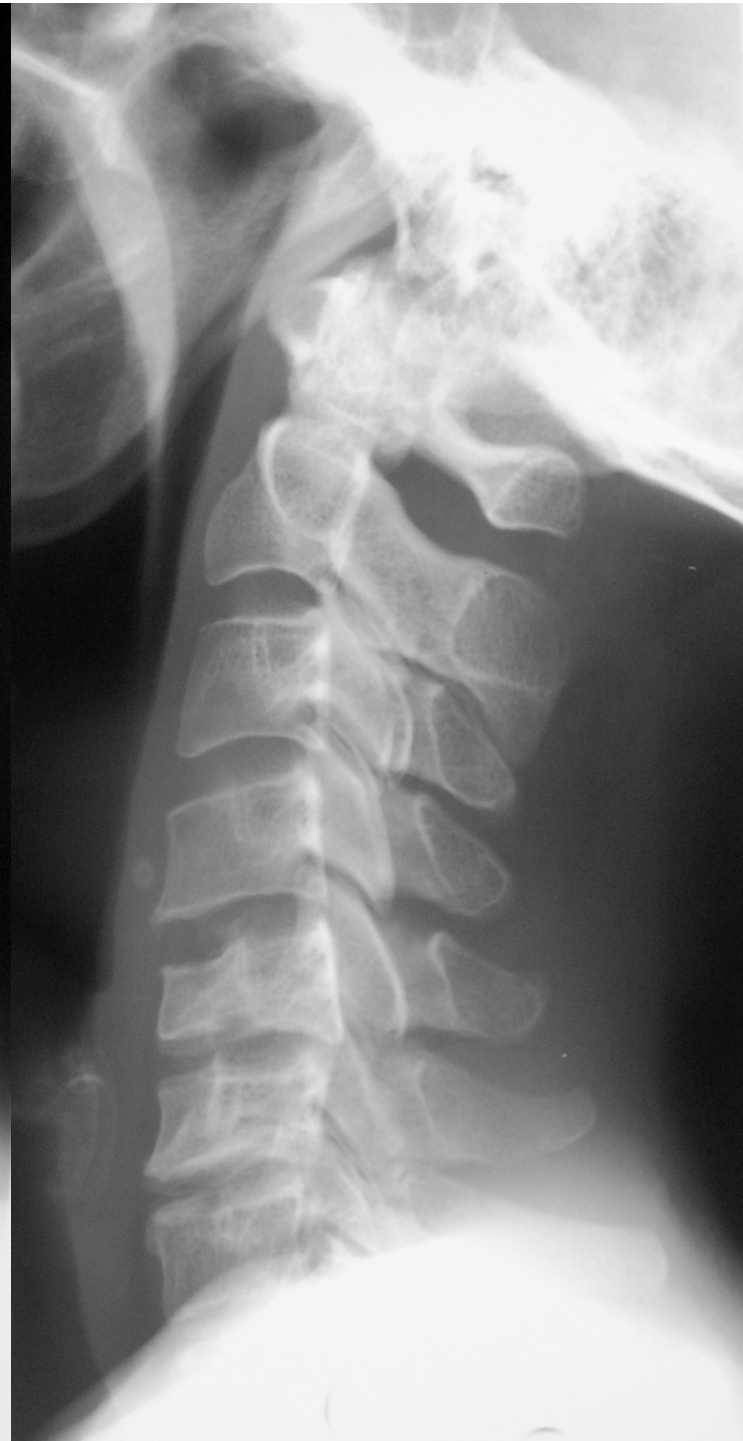
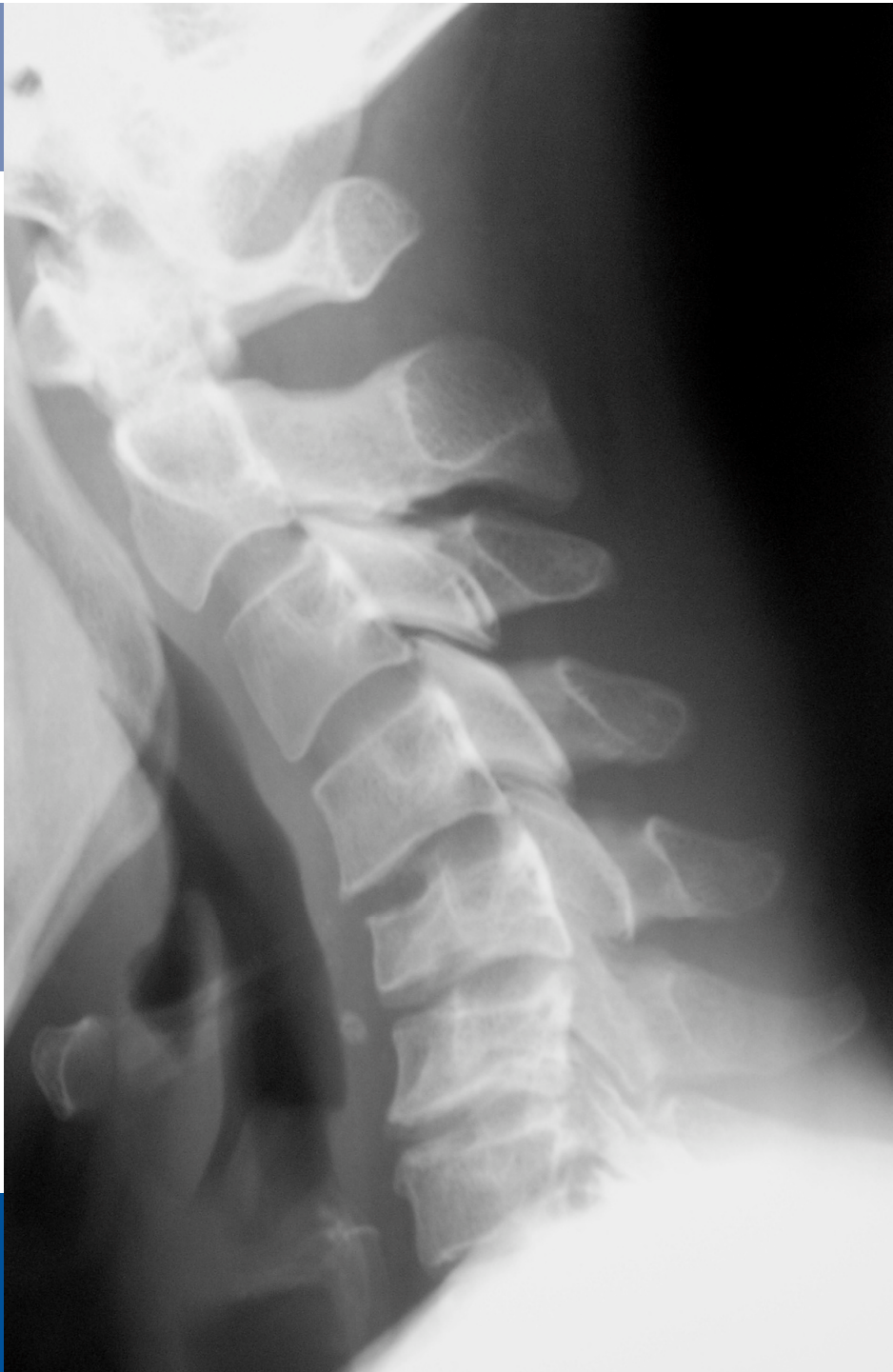




**Male , 42 y , rigth C6 C7 C.B.**

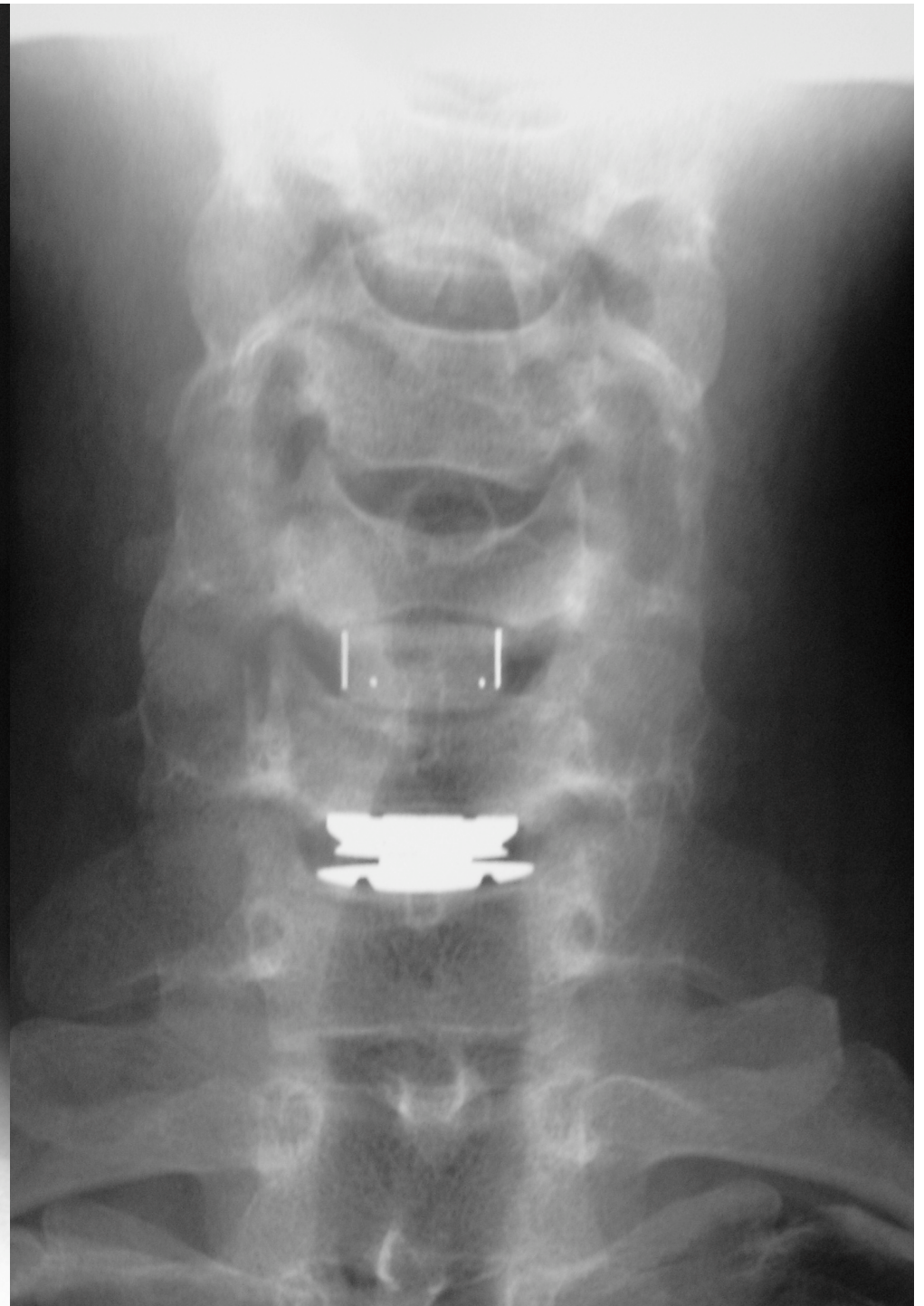
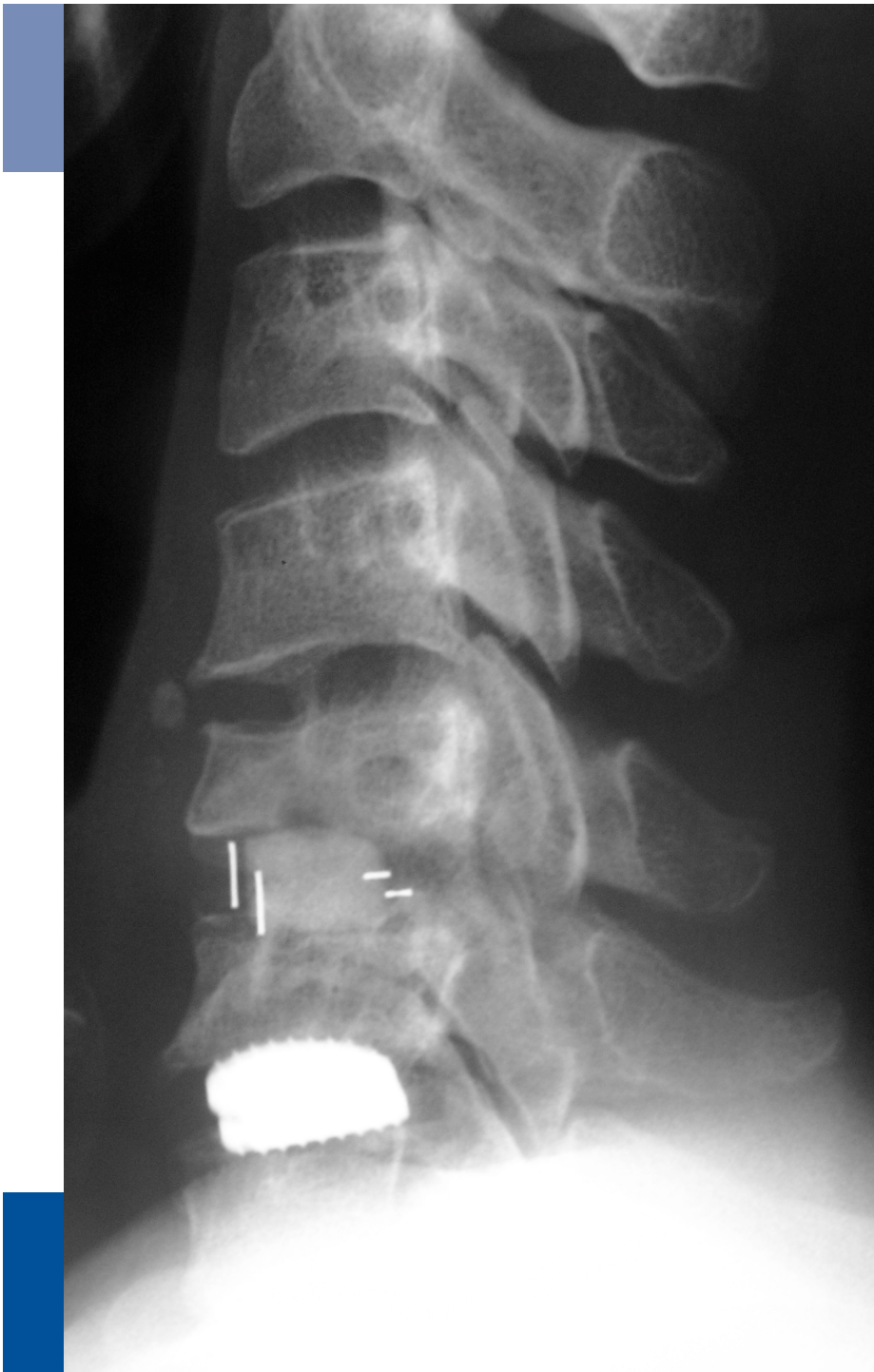



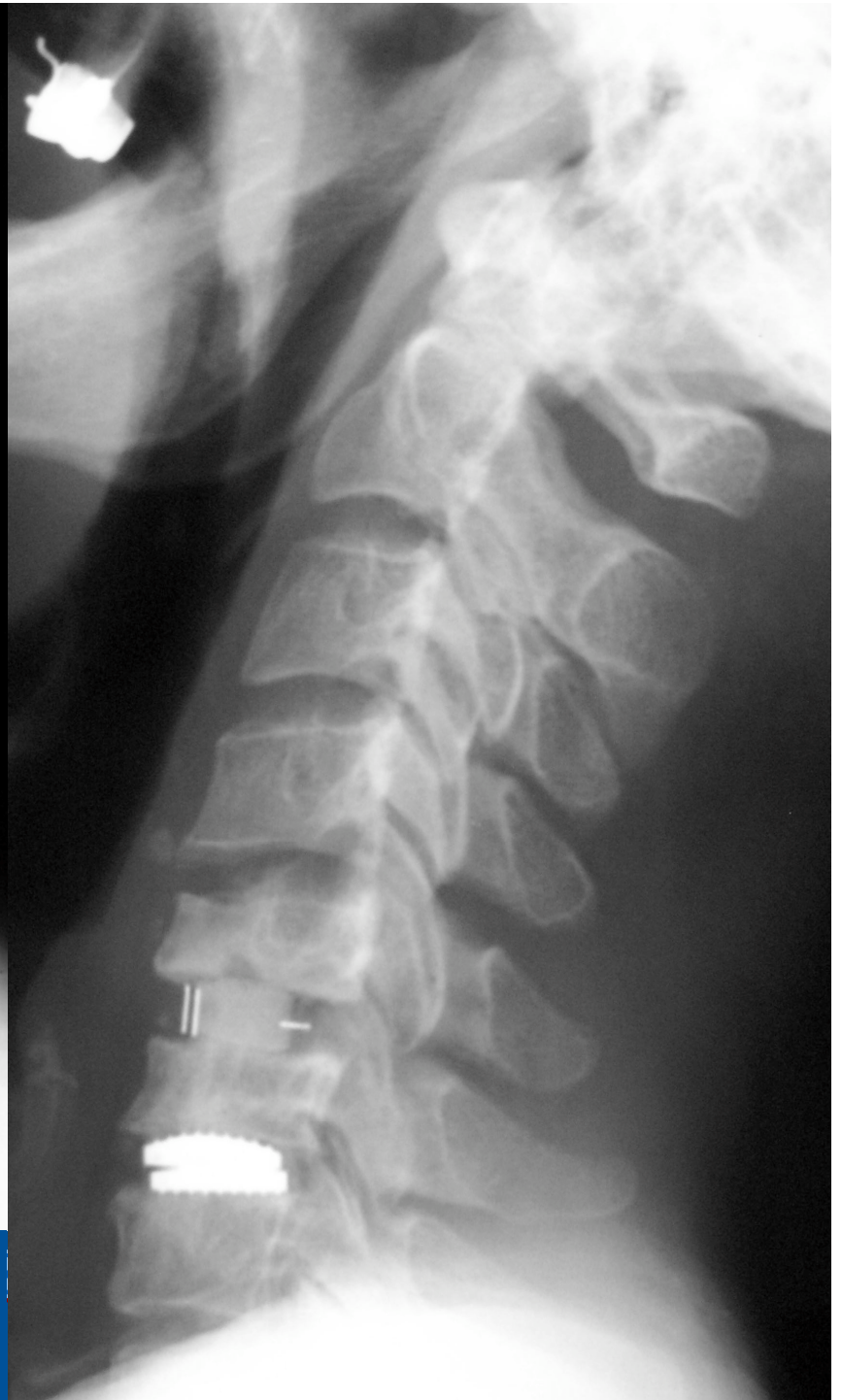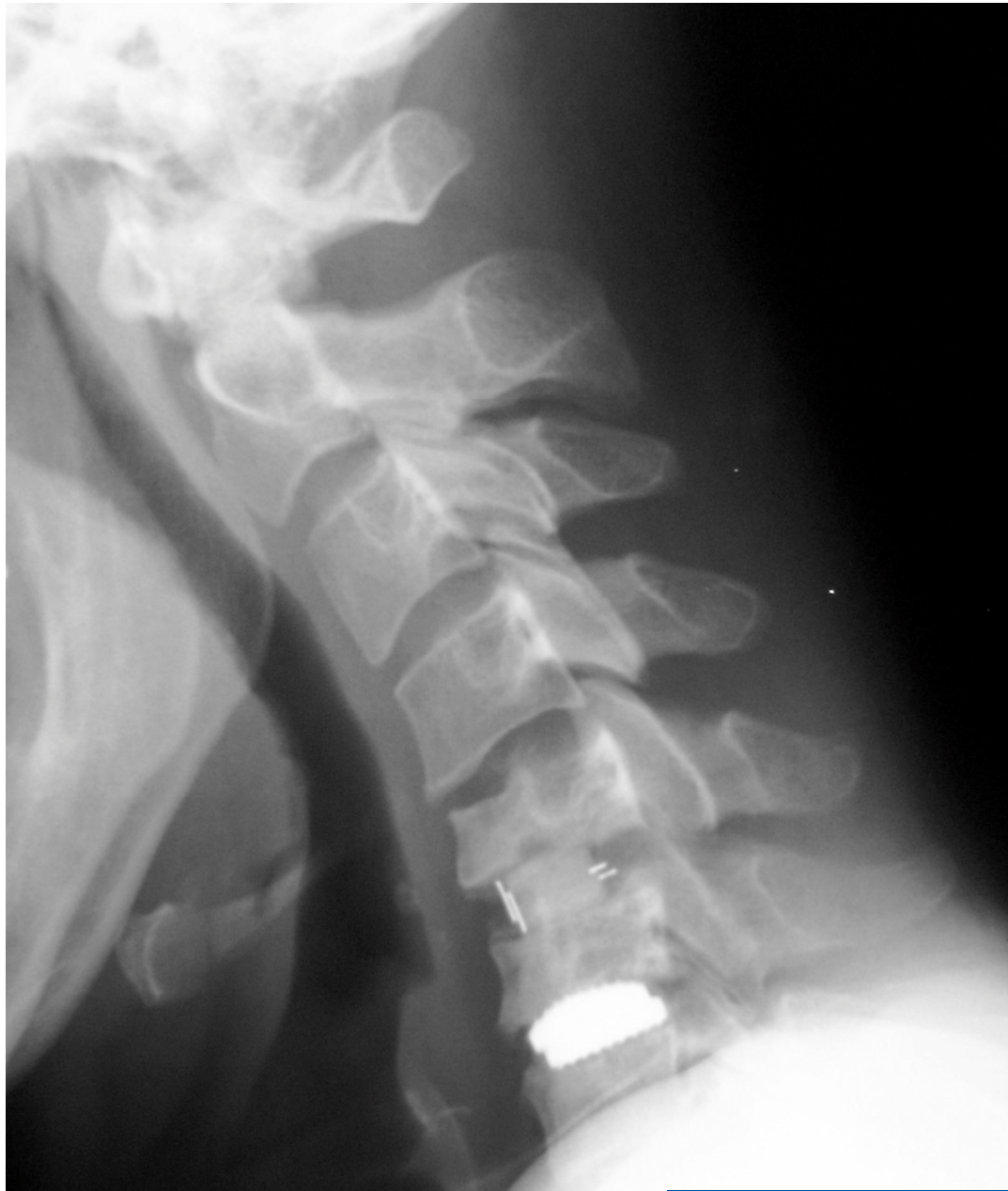**C5C6**

**C6C7**









# Barbagallo ( CSRS Bruxelles 2007 )

- 16 patients (37 to 72 y.)
- 9 patients : 2 levels
- 5 patients : 3 levels
- 2 patients : 4 levels
- CAGE or PROTHESIS : soft/hard herniation ,  
dynamic X-rays , post-release fluoroscopy
- NDI : 32% preop to 5% postop

# Debatable Questions for Discussion

- **DELAYED HYBRID RECONSTRUCTION**

**First : cage**

**Tempted to put prothesis**

**Kyphosis difficult to control**



# Debatable Questions for Discussion

- **HYBRID RECONSTRUCTION in the SAME PROCEDURE**
- PROTHESIS : soft herniation  
mobile disc  
> C7T1
- CAGE : hard herniation (but posterior release)  
little mobility  
mainly at C6C7 level

# Debatable Questions for Discussion

- **DO YOU HAVE TO TREAT**

**ALL THE ANATOMIC DETERIOTATED  
LEVELS**

**ONLY THE SYMPTOMATIC LEVELS ?**

Summer University  
Rome 2007



# Group Experience

Go around and share within the group what current practices are being used

# Group Consensus

- Based on the discussions can the group conclude on what should be “standard” practices for the topic.

# Cases For Discussion

As many cases as the surgeon thinks he will need to help facilitate discussion